

culi could be palpated, but were so adherent to the mucosa of the urethra that it took about 45 minutes of painstaking manipulation with a metal sound to dislodge 12 to 15 calculi which ranged in size from 1 to 6 mm. Expression of the bladder then flushed out about 18 more stones of approximately the same size and some finer material, which evidently was in the urethra posterior to the incision. The incision was left to heal as an open wound. The gluteal fistula was debrided and packed with sterile gauze and the patient was returned to the kennel.

In the accompanying photograph (Fig. 1) the urethral incision is seen just anterior to the scrotum. The gluteal wound with the gauze pack inserted is seen about 7 cm. dorsolateral to the scrotum. Figure 2 shows several of the calculi with a 6 in. ruler.

On the day following the operation slight hemorrhage was noticed from the open wound. Urination was through both the urethral orifice and incision opening. The dog was taken outside to the exercise pen to urinate and while there he ate large quantities of snow. About 1½ hrs. later he vomited a serous fluid. To control vomition, 1/50 gr. of atropine sulfate was given subcutaneously. On the following days slight hemorrhage was

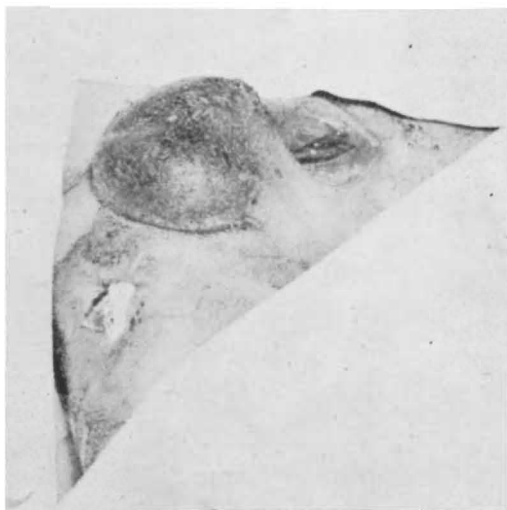


Fig. 1—Photograph of the operative site showing the location of the incision and the gluteal wound.

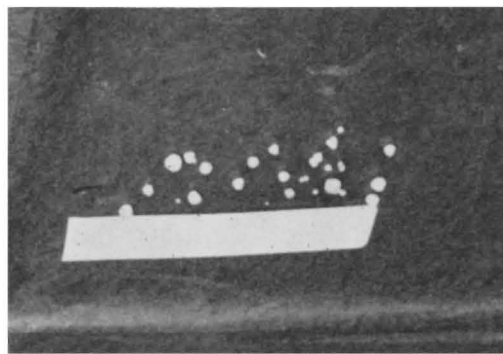


Fig. 2—Several of the calculi with a 6 in. ruler.

seen following urination and excitement. On the fifteenth day the patient was discharged, and at that time urine was still being passed through both openings. As a prophylactic measure, the owner was advised to have the animal castrated following complete recovery; however, at present this has not been done.

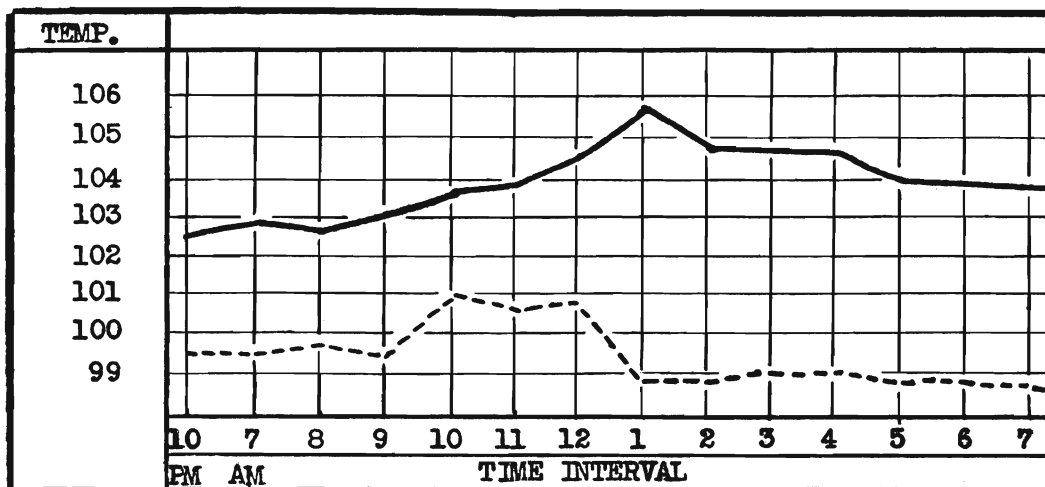
R. Scholten '52

5

A case of John's Disease. On Jan. 31, 1951, a 4-year-old short-horn cow was admitted to Stange Memorial Clinic, and on Mar. 31, 1951, a 5-year-old Brown Swiss bull was also admitted. Both animals were in poor general condition—showing symptoms of watery diarrhea, atonic rumen and poor appetite. Both patients were treated symptomatically for several days with little improvement. It was decided to subject both animals to a test for John's disease. The test was conducted as follows: both animals received 10 cc. of avian tuberculin intravenously and their temperatures were checked hourly.

The Shorthorn cow had more than a 2 degree temperature rise which was considered indicative of John's disease. The Brown Swiss bull did not show enough change in temperature to be considered positive.

The Brown Swiss bull improved greatly after symptomatic treatment consisting of 3 oz. of powdered gentian, ginger and nux vomica (equal parts), 3 oz. of a vitamin feed supplement and 2 oz. of a mineral mixture, containing a trace of



A graph, showing the temperature changes of the Shorthorn cow (solid line) and the Brown Swiss bull (broken line). The injection of avian tuberculin was made at 8 a.m.

cobalt, was given daily. Several ruminal transplants were made. The animal was discharged after about 10 days of treatment. The Shorthorn cow was discharged to be slaughtered.

E. M. Freeman '52

6

An Unusual Lipoma in a Dog.

On April 4, 1951, a small, 11-year old male terrier was admitted to Stange Memorial Clinic. A very large tumor was observed on the underline, involving both the abdominal and thoracic walls. An extremely unfavorable prognosis for successful recovery following surgical removal was given due to the size of the tumor and the condition and age of the patient. However, because of the tumor's large size it was constantly being traumatized so removal was a necessity. The owner realized this was the only possible means of saving his dog's life so requested surgery..

The following morning the patient was given 1 gr. of morphine sulfate and 1/50 gr. of atropine sulfate subcutaneously. The area was clipped, cleaned and defatted and sprayed with alcohol. The eyes and nose were protected with ophthalmic ointment, as ether was the anesthetic of choice. The patient was then restrained on the operating table and a sterile shroud placed over the

