

Ventricular Tachycardia in the Dog

by
Jan Gonder*
and
Lawrence P. Tilley, D.V.M.†

INTRODUCTION

Ventricular arrhythmias are not uncommon. Practitioners should realize that many arrhythmias are potentially very dangerous. Unfortunately, most veterinarians do not have electrocardiographic equipment available as a diagnostic aid. It is hoped that more practitioners will add this valuable item to their existing diagnostic tools, as they did X-ray units not too many years ago.

ETIOLOGY

Ventricular premature contractions (VPC's) and ventricular tachycardia (V-T) that may develop are indications of myocardial irritation or inflammation. Primary myocardial disease is unusual in the dog (3,6,8). Secondary myocardial disease can result from viral, bacterial, mycotic, and protozoal infections, hyperthyroidism, hypothyroidism, anemia, malnutrition, electrolyte imbalances, uremia, pyometra, hypoxia, congestive heart failure (CHF), and many other conditions (3). VPC's are commonly seen secondary to the administration of various drugs. 85% of the animals anesthetized with thiamyl sodium develop arrhythmias—most often VPC's. These arrhythmias are usually temporary, but should be observed closely for development of more serious arrhythmias. Methoxyflurane and halothane are also arrhythmogenic (3,15). Digitalis can cause any type of arrhythmia (3,8,10,11,13).

*J. Gonder is a fourth year student, College of Veterinary Medicine, Iowa State University.

†Dr. Tilley (ISU '69) is the staff cardiologist, Animal Medical Center, New York, N.Y.

CLINICAL PICTURE

Clinical signs usually do not develop until the VPC's become frequent or V-T develops. Decreased filling time results in decreased cardiac output which effects the efficiency of cardiac contraction. Coronary artery flow is decreased by as much as 60% during V-T. Renal blood flow may decrease as much as 50% in V-T (11). Renal ischemia resulting in proteinuria, oliguria, and nephrosis will persist for three to four days following conversion to normal rhythm.

Decreased exercise tolerance, weakness, lethargy, syncope, seizures, coma, and sudden death can all be indications of myocardial irritation and serious arrhythmias. Tachycardias can result in CHF if the arrhythmia persists. History and clinical signs may be characteristic of any of the disease states mentioned above. Cardiac status should always be carefully evaluated and considered before anesthetics are administered. Disasterous situations can be avoided by correcting arrhythmias prior to administration of anesthesia. Pyometra is a prime example of a condition in which ventricular arrhythmias frequently occur (3).

Physical examination may reveal a pulse deficit with either VPC's or V-T. A jugular pulse may be present if the right atrium contracts when the tricuspid valve is closed by a VPC. These are termed cannon "a" waves (3,8).

ELECTROCARDIOGRAPHY

The heart rate may be normal and the normal rhythm is broken by premature beats. In V-T the normal rhythm is broken by a string of premature beats. ST-

Improved rabies vaccine licensed for dogs and cats.



1. "Improved Rabies Vaccine
Licensed for Dogs and Cats,"
U.S. Dept. of Agr., News Release
USDA 1098-73.

2. "Improved Rabies Vaccine
Licensed for Dogs and Cats,"
News Section, *Jrnl. of the*
AVMA, 162:12:1021.

▲▲ The vaccine is produced from rabies virus grown in brain tissue taken from suckling mice. Virus particles are killed during processing, so that they cannot revert to an active, dangerous state. Thus, the vaccine is quite safe for animals and those who handle the vaccine or may be accidentally exposed to it. ^{1, 2}

▲▲ By growing a large number of vaccine virus particles in a small number of brain cells, the manufacturer can produce a vaccine with high strength—or potency—and a low proportion of remaining animal tissue. Large numbers of animal cells could cause irritation and inflammation at the injection site. ^{1, 2}

▲▲ Existing rabies vaccines are made either from killed virus or live virus that is modified, or altered to keep it from causing disease. Killed virus vaccines are generally safe, but have presented problems with limited potency and undesirable side effects. Modified live virus vaccines are quite potent, but present a small, but ever-present safety risk. ¹

▲▲ Puppies and kittens should be vaccinated at three months of age—or revaccinated then if they were vaccinated earlier. Vaccination should be repeated yearly.

▲▲
TRIMUNETM
RABIES VACCINE

Killed virus, murine origin

Manufactured by
Rolyann Laboratories
Lenexa, Kansas

Distributed by
Fort Dodge Laboratories
Fort Dodge, Iowa

depression and/or inverted T-waves are often seen following paroxysms of V-T (13). Characteristically, these premature beats are not associated with P-waves and have bizarre QRS complexes (I). The unusual configuration results from the slower myocardial conduction than that of the Purkinji System (5). Isolated premature beats within a normal rhythm are termed "singles." Two VPC's in a row constitute a "pair." Three VPC's in a row make a "run," and four or more constitute ventricular tachycardia. If all of the premature beats are of similar configuration it is an indication that there is a unifocal ventricular discharge. VPC's of multifocal origin indicate many areas of myocardial irritation and constitute a much more dangerous situation (II). Multifocal V-T should be considered pre-fibrillatory (4).

When a normal PQRS complex occurs in a string of VPC's it is called a capture beat, because the P-wave occurs at just the right time to "capture" the rhythm of the ventricle. A beat occurring between a series

of normal beats and a paroxysm of V-T is called a "fusion" beat. This occurs when a focus in the ventricle is discharged at the same time the ventricle is depolarized. This results in a beat with a normal P-R interval and P-wave, but with a QRS complex different from the normal and the VPC. Capture and fusion beats are diagnostic of ventricular tachycardia (3,8,11,13). They indicate that the ectopic rhythm is ventricular in origin and that the AV node has not lost its ability to conduct.

AV dissociation is a form of V-T where the ventricular rate is less than 100 beats per minute. It is almost always due to digitalis intoxication. When all the beats are of ventricular origin, this is referred to as an idioventricular rhythm.

THERAPY

Effective therapy of ventricular arrhythmias is dependent upon recognition of the cause and severity of the problem. If VPC's occur as a result of myocardial hypoxia due

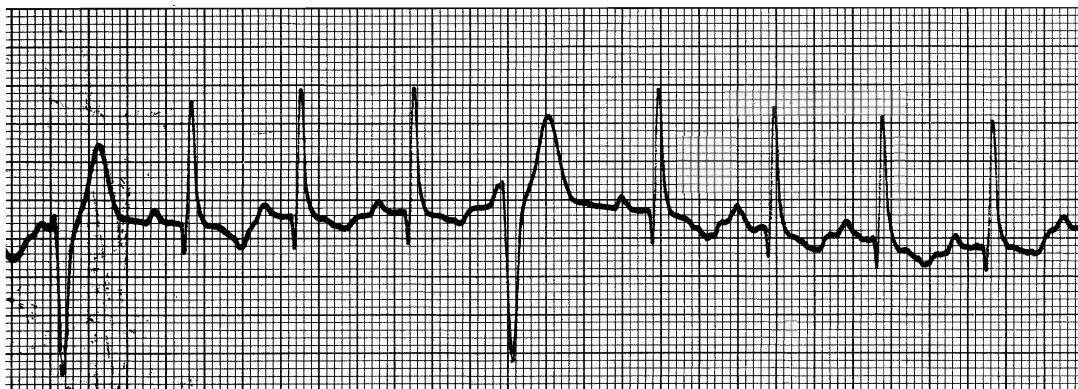


Fig. I. Ventricular Premature Contractions not associated with P-waves. Note bizarre QRS complexes.

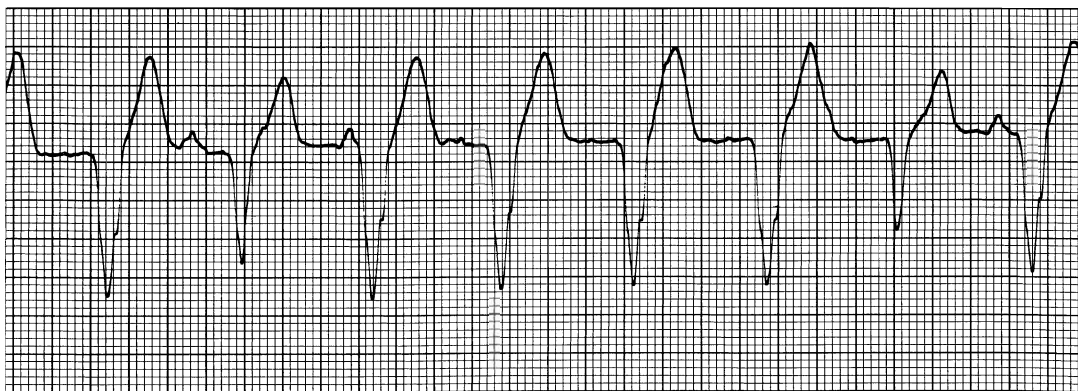


Fig. II. Ventricular tachycardia of multifocal origin.

to CHF, myocardial depressants are contraindicated. In this instance heart failure is severe and pulmonary edema usually exists. Digitalis, diuretics, oxygen, and cage rest are indicated.

In all other cases of ventricular arrhythmias, digitalis is contraindicated because it will enhance myocardial irritability and aggravate the arrhythmia.

Many agents are available for the treatment of ventricular arrhythmias. The choice of agents will depend on the urgency of the situation.

Lidocaine is the drug of choice in cases of sudden collapse or coma associated with ventricular tachycardia (3,7,8,10,12). 2% lidocaine administered in an intravenous bolus at a dose of 2-4mg/# will act in seconds to decrease ventricular excitability and contractility. The same dosage administered over a 1-2 minute period is recommended for less than critical situations to avoid the severe depression associated with bolus administration.

Lidocaine is cleared from the blood in 20 minutes. Intramuscular administration of quinidine sulfate at the same time as the lidocaine will provide for continuation of the myocardial depression after the effects of the lidocaine wear off.

Lidocaine is also used to treat ventricular arrhythmias associated with digitalis intoxication. 1-2 mg/# is administered IV, followed by a slow drip (2 mg/cc) continued until the arrhythmia is gone. In this situation quinidine and procainamide should not be used in combination with lidocaine to control the arrhythmia because of the longer duration and the increased chance of combined intoxication resulting in convulsions.

Quinidine and procainamide are the agents of choice in less critical situations (3,7,8,10,12). Both drugs depress myocardial excitability and contractility and slow conduction. Spontaneous discharge from pacemaker tissue is depressed.

Quinidine is available in oral or IM forms and is administered at a dosage of 3-10 mg/#. The initial dose is given at the low end of the dosage range and is given every 2-8 hours until the arrhythmia is under control. 3-10 mg/# every 6-8 hours is the maintenance dose. Long-acting forms are available and are given every 8-12 hours.

Most cases require maintenance on quinidine for several weeks after return to normal rhythm. In some instances lifetime therapy is required.

Large doses of quinidine may induce idioventricular impulse generation and may cause ventricular fibrillation, therefore when response is delayed, an increase in dosage may be wrong (10). This hazard is related to the increased ventricular conduction time. Prolonged QRS complexes may indicate intoxication. Vomiting, diarrhea, depression, incoordination, and convulsions may also indicate quinidine toxicity.

Procainamide, when used in V-T, will act in minutes after IV administration, but this route should be avoided because severe hypotension may develop. IM administration of 250-500 mg procainamide every 2 hours until the arrhythmia is under control, followed by oral administration every 4-6 hours is used for fairly rapid control. Slow control is achieved with oral doses of 250-500 mg (125 mg in small dogs) every 4-6 hours. This dosage is increased if the arrhythmia persists. Anorexia, vomiting, and prolongation of QRS complexes are indications of procainamide toxicity.

Diphenylhydantoin is often used for digitalis-induced arrhythmias (3,8,10). IV administration of 5 mg/kg diphenylhydantoin over 4-5 minutes, followed by 100 mg orally or IM, QID, thereafter, will usually control the arrhythmia. Diphenylhydantoin may also control arrhythmias where quinidine and procainamide fail.

Propranolol is most often used in combination with quinidine or procainamide in the control of ventricular arrhythmias (3,8,10). This agent acts to slow the heart rate and reduce cardiac output. Propranolol is also indicated in the treatment of severe digitalis-induced arrhythmias. It is contraindicated in CHF because it will aggravate the existing situation. 1-3 mg propranolol is administered by IV bolus or by slow IV infusion until the desired effect is reached.

Electrical cardioversion can be an effective means of controlling some arrhythmias (8,11). It does not replace antiarrhythmic drugs, but is often used in

conjunction with drug therapy. Direct current shock causes depolarization of the entire heart and allows the SA node to take over normal pacing. Cardioversion is contraindicated in digitalis-induced arrhythmias and arrhythmias associated with quinidine and procainamide intoxication because it may induce ventricular fibrillation.

Electrical pacing of the right side of the heart by percutaneous transvenous electrode placement is the method of pacing chosen for emergency or temporary control of heart rate (9). Impulses may be delivered directly to the right ventricle or, if the AV node is functional, to the right atrium. Permanent cardiac pacing is used infrequently in veterinary medicine, although it has been employed with some success (14).

CASE REPORT

On October 3, 1975, a 14 year old male Saluki was presented to the Animal Medical Center nearly comatose with a history of 2-3 episodes of syncope and acute onset of dyspnea and collapse. The dog was treated for heartworms one month previously.

No pulses were palpated on admission and a mitral insufficiency was auscultated. An electrocardiogram done on admission revealed V-T of unifocal origin (A), which was unresponsive to ocular pressure. 500 cc of Lactated Ringer's (L/R) was given by rapid IV administration, followed by 200 mg Solu-Delta-Cortef and another 500 cc L/R with 12 cc of 2% lidocaine. An IV bolus of 2 mg propranolol was then given. No response was seen in one hour. Electric cardioversion was attempted 3 times at 100-250 watt-seconds with no response. Atrial and ventricular pacing was attempted with a favorable response. Ventricular tachycardia was now paroxysmal with runs of normal sinus rhythm. Quinidine sulfate was given every 4 hours, 500 cc L/R with 200 cc sodium bicarbonate and 12 cc 2% lidocaine TID, antibiotics TID, and diuretics BID for the pulmonary congestion and edema.

On October 4, the dog was depressed but able to stand with assistance, had a pulse deficit, and a normal heart rate. The ECG

showed multifocal V-T with an occasional capture beat.

On October 5, the ECG showed rapid heart rate with prolonged P-R intervals and normal QRS complexes. The lidocaine was discontinued. Quinidine was continued as was the L/R, adding 2% dextrose because of an existing hypoglycemia (blood glucose = 40). By 5 PM the dog was back in V-T.

On October 6, the ECG showed some normal QRS complexes and no P-waves. Ventricular tachycardia of multifocal origin was present.

The following differential diagnoses were considered:

- 1) Myocardial Infarction
- 2) Bacterial Endocarditis
- 3) Idiopathic Myocarditis
- 4) Cardiomyopathy

Myocardial infarction was considered because the dog was an old, large breed dog, the chest films were not suggestive of primary valvular disease or congestive heart failure, and experience with this type of case where V-T is unresponsive to drugs (14). The ECG's were not diagnostic of myocardial infarction where S-T elevation is seen because of the multifocal nature of the V-T. First degree heart block (prolonged P-R interval) was found, which can be associated with myocardial infarction (2).

On October 7, an idioventricular rhythm was present. The owners were notified and advised of the grave prognosis. They requested euthanasia.

On October 8, before euthanasia, angiocardiographic studies were done. Dye injected in the area of the coronary sinus revealed no impairment of coronary blood flow, but selective coronary studies were not done.

Gross post mortem findings were multiple myocardial infarctions, pulmonary thrombosis and infarction, *Dirofilaria* (one male and one female), and hepatic congestion.

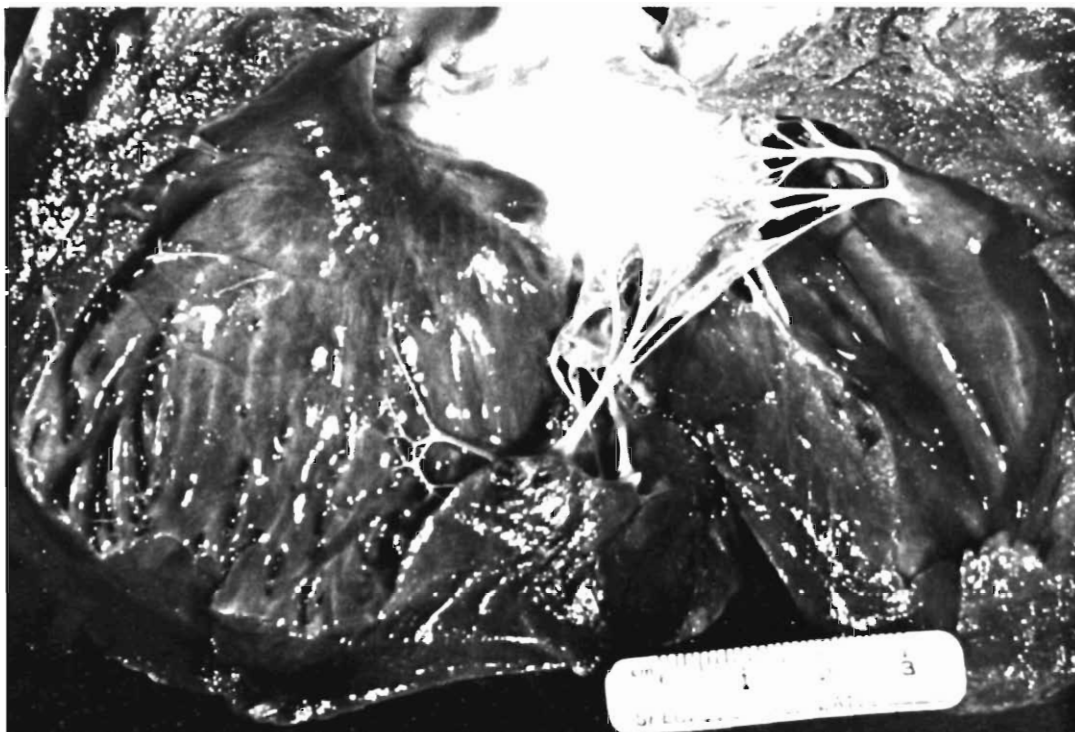CONCLUSION

This case is a good example of the proper management of ventricular tachycardia. Because of the permanent myocardial damage associated with myocardial in-

farcion, therapy was unrewarding. It must be mentioned again that primary myocardial disease such as this is unusual in the dog. Most cases of ventricular arrhythmias, if recognized early and handled properly to correct the arrhythmia and the underlying cause of that arrhythmia, will many times respond favorably.

BIBLIOGRAPHY

1. Bloor, C. M., "Pathophysiology of Acute Myocardial Infarction in Conscious Dogs," *Advances in Experimental Medicine and Biology*, 1972. Vol. 22, P. 347-358.
2. Bolton, Gary R. and Jaffe, Kenneth R., "Myocardial Infarction in a Dog with Complete Heart Block" *VM/SAC*, February 1974, p. 197-200.
3. Bolton, Gary R., *Handbook of Canine Electrocardiography*, 1975, W. B. Saunders, Co., Philadelphia, Pa.
4. Cranefield, Paul F., "Ventricular Fibrillation," *New England Journal of Medicine*, October 4, 1973, Vol. 289 No. 14 p. 732-36.
5. Cranefield, Paul F., Wit, Andrew L., and Hoffman, Brian F. "Genesis of Cardiac Arrhythmias" *Circulation* January 1973 Vol. 47 p. 190-202.
6. Darke, P. G., "Acquired Cardiac Disorders in the Dog," *Veterinary Annual* 1973, Vol. 14, p. 145-47.
7. Darke, P. G., "The Treatment of Cardiac Disease in the Dog," *Veterinary Annual*, 1975 Vol. 15, p. 268-71.
8. Ettinger, Stephen J. and Suter, Peter F., *Canine Cardiology*, 1970, W. B. Saunders, Co., Philadelphia, Pa.
9. Furman, Seymour and Escher, Doris J. W., *Principles and Techniques of Cardiac Pacing*, 1970, Harper and Row, Publishers, Inc., New York, N. Y.
10. Goodman, Louis S. and Gilman, Alfred, *The Pharmacological Basis of Therapeutics*, 4th Ed., 1970, The MacMillan Co., New York, N.Y.
11. Hurst, J. Willis and Logue, R. Bruce, *The Heart*, 1970, McGraw-Hill, Inc., New York, N.Y.
12. Paddleford, Robert R., Short, Charles E., and McGrath, Charles J. "Cardiopulmonary Resuscitation", *The Practicing Veterinarian* Oct.-Nov. 1975, p. 4-8.
13. Scherf, David and Schott, Adolf, *Extrasystoles and Allied Arrhythmias*, 2nd Ed., 1973, William Heinemann Medical Books Ltd., London.
14. Tilley, Laurence P., Staff Cardiologist, Animal Medical Center, New York, N.Y. Personal communication.
15. Wiersig, D.O., Davis, R. H., and Szabuniewicz, M., "Prevention of Induced Ventricular Fibrillation in Dogs Anesthetized with Ultrashort Acting Barbiturates and Halothane," *Journal of the American Veterinary Medical Association*, August 15, 1974, Vol. 165, No. 4 p. 341-44.



Necropsy revealed infarcted areas in the myocardium. Note the highlighted areas at upper left and upper right of photograph.