

71-21,981

WIGGERS, Kenneth Dale, 1942-  
ATHEROSCLEROSIS IN RUMINANTS.

Iowa State University, Ph.D., 1971  
Health Sciences, pathology

University Microfilms, A XEROX Company, Ann Arbor, Michigan

Atherosclerosis in ruminants

by

Kenneth Dale Wiggers

A Dissertation Submitted to the  
Graduate Faculty in Partial Fulfillment of  
The Requirements for the Degree of  
DOCTOR OF PHILOSOPHY

Major Subjects: Nutrition  
Physiology

Approved:

Signature was redacted for privacy.

In Charge of Major Work

Signature was redacted for privacy.

Heads of Major Departments

Signature was redacted for privacy.

Dean of Graduate College

Iowa State University  
Of Science and Technology  
Ames, Iowa

1971

## TABLE OF CONTENTS

	Page
LITERATURE REVIEW	1
Histology	1
Smooth Muscle	5
Aortic Lipid	7
Acid Mucopolysaccharides	9
Calcium	10
Dietary Fat	11
Dietary Carbohydrates	15
Dietary Protein	16
Hypertension	17
Magnesium	18
Body Cholesterol	19
SECTION I - ATHEROSCLEROSIS IN RUMINANTS	21
Materials and Methods	22
Results and Discussion	24
Summary	33
SECTION II - EXPERIMENTAL ATHEROSCLEROSIS IN THE YOUNG BOVINE	34
Materials and Methods	34
Results and Discussion	38
Summary	71

	Page
SECTION III - EXPERIMENTAL ATHEROSCLEROSIS AND CHOLESTEROL	
ABSORPTION IN THE YOUNG BOVINE	72
Materials and Methods	72
Results and Discussion	82
Summary	112
SECTION IV - MISCELLANEOUS OBSERVATIONS	114
Materials and Methods	114
Results and Discussion	115
Summary	127
GENERAL DISCUSSION	129
LITERATURE CITED	134
ACKNOWLEDGEMENTS	147

## LITERATURE REVIEW

Atherosclerosis involving the coronary, cerebral, and peripheral arteries and the aorta is a major cause of death and morbidity in the developed countries of the world (Lloyd and Wolff, 1969). Mortality rates from this disease have increased over the past several years, particularly for the younger age-groups (Masironi, 1970). Aortic (Holman et al., 1958a) and coronary (Strong and McGill, 1962) atherosclerotic lesions are present in almost all of the adult humans in the United States (Gould, Wissler and Jones, 1963). Over half of all deaths in the United States each year are attributable to atherosclerotic complications (Gould, Wissler and Jones, 1963). These deaths are mainly the result of myocardial infarcts and cerebral strokes.

## Histology

In examination of the aorta and the coronary and cerebral arteries of three age-groups in swine, Ratcliffe, Luginbühl and Pivnik (1970) described the following histological features of atherosclerosis: (1) focal reorientation and proliferation of smooth muscle cells (SMCs) often accompanied by apparent medial degeneration, (2) fragmentation and replication of the internal elastic lamina, (3) apparent movement of SMCs through fragmented internal elastic lamina and proliferation to form stenosing lesions and (4) elastic and collagen fiber formation to enclose the SMCs. Larger lesions often contained regions in which SMCs became enlarged and rounded to form fat-containing foam cells. Foam cell formation was accompanied by regional degeneration of these

cells, cholesterol deposition and calcification to produce the features of atheroma.

The walls of arteries consist of three coats or tunics (Gross, Epstein and Kugel, 1934 and Ham, 1969): (1) the tunica intima (the innermost coat or layer), (2) the tunica media (the middle coat or layer) and (3) the tunica adventitia (the outermost coat or layer). In the literature, the three tunics are generally referred to as the intima, media and adventitia. A layer of endothelial cells (endothelium) lines the luminal side of the intima in all arteries (Ham, 1969). The internal elastic lamina, which separates the intima from the media, is important as a structural barrier to infiltrating processes (Lansing, Alex and Rosenthal, 1950). The "normal" intima of the coronary of the human infant at birth consists of a single layer of endothelial cells lying on the internal elastic lamina; the intima progressively increases in thickness with age (Levene, 1956b). Prior and Jones (1952) and Wiggers<sup>1</sup> observed that the intima of human infant and fetal goat aorta, respectively, consisted of a single layer of endothelial cells. In contrast, coronary intimal thickening was noted in the fetal pig and the fetal camel (Taher and Berg, 1969). Splitting of the internal elastic lamina was also associated with the intimal thickening found in the camel fetus.

Knieriem and Hueber (1970) interpret human aortic intimal thickening to be physiological with advancing age and found that the intima increases from 0.1 mm to 0.4 mm. However, Stehbens (1964) states that intimal

---

<sup>1</sup> Wiggers, K. D. Department of Animal Science, Iowa State University, Ames, Iowa. Unpublished data. 1971.

proliferation may not be a physiological component of the arterial wall, but rather a compensatory thickening in response to stress. Tritiated thymidine uptake studies by Constantinides (1968) indicate that the cell population of the hyperplastic intima is derived from endothelial and medial smooth muscle cell (SMC) proliferation and from migration of blood leukocytes into the vessel wall. Intimal thickening is more pronounced in arteries that commonly develop atherosclerosis (Wilens, 1951) and may be an important precursor of the atherosclerotic lesion (Fangman and Hellwig, 1947; Moon, 1957; Prior and Jones, 1952; and Stehbens, 1964). Knieriem and Hueber (1970) also noted there is an additional marked increase of the thickness and area of the intima in cases of atherosclerosis. Getty (1966) found intimal thickening to be more pronounced in areas susceptible to plaque formation in the hog and dog. Stehbens (1963 and 1965) found lipid always localized in the zone of intimal thickening. Fatty and fibrotic degeneration of the intima occurs in atherosclerosis (Lansing, Alex and Rosenthal, 1950). Arteries which have marked intimal thickening are more inclined to develop severe atherosclerosis; however, intimal thickening does not inevitably progress to atherosclerosis (Likar et al., 1969).

Elastic tissue degeneration is involved in the development of atherosclerosis (Blumenthal, Lansing and Gray, 1950; Ehrick, DeLa Chapelle and Cohn, 1931; Gross, Epstein and Kugel, 1934); more specifically, circumstances leading to the degeneration of the internal elastic lamina may be the key to atherogenesis (Adams and Tuqan, 1961). Lesions of the internal elastic lamina are the first visible manifestation of atheroma

over which fibrous thickenings develop (Levene, 1956a, b). These fibrotic thickenings are extremely common in the human coronary during the first three decades of life; subsequently fat, cholesterol clefts, necrotic debris and calcium become prevalent.

Breaks of the endothelial lining (Constantinides and Robinson, 1969) and subsequent damage to the intima (Zilvermit, 1968a) may play an important role in atherogenesis, i.e., infiltration of cholesterol and other lipids into the arterial wall. The proliferation and subsequent degeneration of arterial connective tissue appear to be the primary lesion of atherosclerosis (Adams and Tuqan, 1961). The infiltration of lipids and lipoproteins from the blood is a secondary event responsible for the enlargement of the established plaque. However, intimal plaques have the capacity to grow intrinsically and do not enlarge merely by translocation of cells from the media, the endothelium or from the blood (Stary and McMillan, 1970).

If the arterial wall is first damaged in various places and exposed to hyperlipemia, atheromata will develop selectively at the sites of injury (Constantinides, 1961). Within five minutes of egg yolk infusion into ergocalciferol-injured rat arteries, free yolk particles penetrated inner layers of the arterial wall (Constantinides, 1968). Clusters of yolk-laden foam cells developed within six hours after two infusions. No yolk particle penetration or foam cell development occurred after animals with normal vessels or with arteries completely repaired from previous injury were infused. Ts'ao (1970) noted detachment of rabbit



aortic endothelial cells at the site of even a very brief mechanical injury. Blood platelet aggregation was found at the site of endothelial absence. Platelet-rich microthrombi also occur on apparently normal endothelium; some of the thrombi become incorporated into the vessel wall, thus giving rise to intimal thickening and atherosclerotic-like lesions (Mustard et al., 1964). Microthrombi were also a common feature of bovine coronary arteries (Likar et al., 1969). Moore and Lough (1970) found that within 24 hours after focal endothelial injury due to platelet aggregate embolism, degenerative changes appeared in SMCs. The SMCs accumulated lipid; subsequently, early endothelial regeneration occurred.

Thomas et al. (1968) found ultrastructural evidence of aortic lesions in miniature swine after the first few days of a cholesterol supplemented diet; the lesions consisted of a focal accumulation of SMCs. These ultrastructural lesions which had been induced in swine by ingestion of cholesterol are described as a preproliferative phase of atherosclerosis.

#### Smooth Muscle

The vascular SMC has multi-potential mesenchymal qualities and is responsible for the production of ground substance, collagen and elastic material (Knieriem, 1970 and Wissler, 1968). Fat accumulation in SMCs culminates in the formation of myogenic foam cells (Balis, Haust and More, 1964; Cooke and Smith, 1968; Geer, McGill and Strong, 1961). The phagocytosis by macrophages also results in the formation of foam cells (Balis, Haust and More, 1964 and Haust and More, 1963). Parker and Odland (1966) suggest that lipids get into myointimal cells (SMCs) in two

ways: (1) synthesis within the cell and (2) phagocytosis by the cell. When the foam cells fail to migrate away from the lesion, they rupture and thus contribute to the pool of extracellular lipid. This gives rise to the typical lipid-rich atheroma (Geer, McGill and Strong, 1961 and Haust and More, 1963).

Using immunohistochemical methods, Knieriem, Kao and Wissler (1968) showed a substantial proliferation of SMCs in the intima of the bovine aorta. Antonius and Hill (1968) found a thick intimal layer of SMCs showing almost no evidence of lipid accumulation or degenerative change. As a result of these findings, Antonius and Hill (1968) suggest that the initial anatomic lesion of atherosclerosis may be the proliferation of SMCs and that lipid accumulation is a secondary and perhaps degenerative feature. In examination of fatty streaks from young individuals, McGill and Geer (1963) noted that the first lipid appears within SMCs. Electron microscopic studies of the atheromatous aortic plaque from rabbits fed 5% cholesterol revealed foam-cell-like proliferated SMCs originating from the subendothelial space and the media (Knieriem, 1970). Using electron microscopy, French (1963) showed SMCs in atherosclerotic plaques of dogs fed cholesterol. Cooke and Smith (1968) noted that medial SMCs passed through fenestrations in the internal elastic lamina into the intima; changes in SMC orientation and cytoplasmic degeneration are postulated to be the basic phenomena in pigeon atherosclerosis.

### Aortic Lipid

Gould (1951) noted that human atherosclerotic aortas have a higher content of cholesterol ester than the normal aorta. Similarly, Conner et al. (1967) and Kritchevsky and Tepper (1967) found the total cholesterol content of the rabbit thoracic aorta to correspond with the degree of atherosclerosis. Lofland and Clarkson (1959) used aortic cholesterol concentrations as the primary expression of the extent of atherosclerotic involvement. Cholesterol ester represents quantitatively by far the major lipid in foam cells (Day, Newman and Zilversmit, 1966). The amount of cholesterol ester in aortic intimal lesions containing predominantly foam cells is significantly higher than that in the adjacent normal intima or that in the blood (Smith, Evans and Downham, 1967). In human aortas, cholesterol concentration of the media was found to be quite constant, while in the intima, cholesterol concentration was closely correlated with sudanophilia (Geer et al., 1957), which refers to the positive sudan staining of lipids in the aorta. Sudanophilia is often used as an index of atherosclerosis (Holman et al., 1958b). Jennings et al. (1961) found that the Schultz staining method for cholesterol gives a green coloration almost coextensive with the sudanophilic staining.

In the bovine aortas with moderate gross lesions Likar, Likar and Robinson (1966a) found a significant increase of total lipids (+64%) and decrease in triglycerides (-35%). Bovine aortas with severe gross lesions showed an increase of total cholesterol (+61%). Human aortic fatty streaks contain about 60% cholesterol esters, 5 to 10% free cholesterol, 5 to 15% phospholipids and a low percentage of glycerides (Böttcher, 1963)..

Abdulla, Adams and Bayliss (1969) noted that coronary atherosclerotic lesions contain 4.6 to 24.1% of neutral lipid as triglyceride. Smith, Evans and Downham (1967) found that cholesterol esters in perifibrous lipid (fine extracellular fat aligned along collagen and elastic fibers) contained 28% oleic acid and 40% linoleic acid and in fat-filled cells (foam cells) 48% oleic acid and 14% linoleic acid. Phospholipids in dry tissue are lowest in young intima (about 2%) and highest (8%) in fatty plaques (Böttcher, 1963). Parker et al. (1966), using in vitro studies, demonstrated more phospholipid synthesis in atherosclerotic aortas than in normal aortas. Phospholipids (Day and Tume, 1969; Newman, McCandless and Zilversmit, 1961) and triglycerides (Newman, McCandless and Zilversmit, 1961) of atheromatous lesions are synthesized in situ.

The major part of aortic cholesterol is derived from the plasma (Dayton, 1959; Newman and Zilversmit, 1962; and Zilversmit, 1968b) but the aorta is also capable of synthesizing cholesterol (Reiser et al., 1966). Dayton and Hashimoto (1966) suggested that movement of labeled free cholesterol from plasma into the arterial wall is the result of a physicochemical exchange between lipoprotein and endothelium; in vitro, efflux of cholesterol across the intimal surface was dependent upon the presence of lipoprotein in the medium. This efflux was not retarded by prior boiling of the tissue. Watts (1963) hypothesized that  $\beta$ -lipoproteins are involved in the pathogenesis of atherosclerosis in the following way. The  $\beta$ -lipoproteins act as a carrier for lipids and enter the intimal cells by pinocytosis or direct molecular transfer. Excessive quantities of lipids accumulate, the myocyte (SMC) is converted to a foam

cell, mitochondria and other cytoplasmic structures degenerate and the cell dies. Its lipid and substances are then liberated into the interstices of the vessel wall forming the nidus of a plaque. Continued perfusion of lipoproteins adds to the process and eventually inflammatory cells and scar tissue may appear.

Lofland and Clarkson (1970) observed that in the normal aorta the influx of free cholesterol greatly exceeds that of cholesterol esters; there was not a net positive cholesterol balance. In fatty streaks the influx of both free and esterified cholesterol was greater than for normal tissue and influx rates exceeded efflux rates. In plaques still greater rates of influx and efflux were observed; the influx of cholesterol esters frequently exceeded that of free cholesterol and the plaques were in positive cholesterol balance. Zilvermit (1968b) observed that the rate of cholesterol influx and efflux in the atherosclerotic arterial wall seems to be related to serum cholesterol concentration as well as to aortic cholesterol content. The atherosclerotic plaque in pigeons is the major site of aortic fatty acid synthesis (Lofland et al., 1965). As the aorta becomes more diseased, relatively more of the newly synthesized fatty acid becomes esterified to cholesterol.

#### Acid Mucopolysaccharides

Acid mucopolysaccharides (AMPS) may play some role in atherogenesis. Acid mucopolysaccharides are found in the intercellular substances of connective tissue where they constitute what is termed the ground substance (Ham, 1969). There are two types of AMPS, the sulfated and

the non-sulfated. A common nonsulfated AMPS is hyaluronic acid, whereas the most common sulfated AMPS is chondroitin sulfate. Heparin is another important AMPS.

Increased levels of AMPS may be the nonspecific response of the arterial wall to noxious agents, i.e., activation of connective tissue (Likar, Likar and Robinson, 1968b). Wang, Strauss and Adlersberg (1956) suggested that AMPS furnishes a "matrix" that precedes lipid deposition and is closely related to experimental atherosclerosis in the rabbit. Gould, Wissler and Jones (1963) proposed that AMPS in the artery wall may precipitate  $\beta$ -lipoproteins that filter into the vessel, resulting in an accumulation of cholesterol and cholesterol ester. Zugibe and Brown (1960) routinely observed in human aortas an increase in AMPS in areas of increased collagen.

In the African buffalo, McKinney (1968) observed that AMPS were plentiful in areas of internal elastic lamina degeneration and intimal changes, or, when lipid is present. Likar, Likar and Robinson (1968a) found the severity of degenerative elastic changes in bovine coronary arteries to parallel the decrease in hyaluronic acid. Kumar et al. (1967b) and Nakamura et al. (1968) noted significant decreases in AMPS as atherosclerosis became more extensive. In studies on lesion-free human aortas, Kumar et al. (1967a) found the total AMPS to increase to around the third decade and then to decrease with advancing age.

#### Calcium

The atheromatous plaque "progresses" to a stage where it becomes calcified (Blankenhorn, 1963). Elastic tissue changes involving

calcification of the elastic tissue are more severe under a plaque than in areas adjacent to the plaque (Lansing, Alex and Rosenthal, 1950). The calcification process involves nucleation of calcium apatite crystals in degenerating elastic fibers (Yu and Blumenthal, 1963). Calcium is deposited as a complex of phosphate and carbonate salts in a molar ratio approximating that of carbonate apatite. Yu and Blumenthal (1963) suggested two ways calcium may become bound in the aorta: (1) a reaction of soluble calcium salts with fatty acids forms calcium soaps; these react with glycerides resulting in the precipitation of inorganic calcium salts; and (2) calcium and phosphate ions are trapped by substances such as AMPS and protein.

#### Dietary Fat

As mentioned in the beginning of this review, atherosclerosis is more of a problem in the developed countries where there is a higher standard of living. In these countries, atherosclerosis can be correlated with dietary constituents, hypertension, smoking, stress, blood lipids, diabetes, inherited disposition and our sedentary habits.

Diet has been heavily implicated in the etiology of atherosclerosis, with most emphasis being placed on the role of dietary unsaturated and saturated fats, cholesterol and carbohydrates. There is much variability in species response to dietary constituents. Cook (1936) noted some of this variability when feeding cholesterol in low-fat stock diets to guinea pigs and rats. The guinea pigs were very susceptible to development of fatty livers whereas the rats were not. Fatty livers could be produced in the rats only if fat was added to the cholesterol-stock diet and thus

Cook concluded that cholesterol was absorbed by rats only when fat was present in the diet. Rodbard, Bolene and Katz (1951) found the tendency to atherosclerosis and hypercholesteremia in chicks to be correlated with the amount of cholesterol ingested per kilogram of body weight. Atherosclerosis was also induced in cholesterol-fed chicks on 2/3 normal feed intake.

Saturated fats, cocoa butter and hydrogenated vegetable oil shortening fed to rabbits for periods of up to one year did not produce hypercholesterolemia or gross atherosclerosis (Connor, Rohwedder and Armstrong, 1967). Feeding coconut oil for the same time increased serum cholesterol for four months but a return to baseline was noted by six months. Slight atherosclerotic lesions were noted in 50% of the rabbits fed cocoa butter. The serum cholesterol levels and incidence of atherosclerosis increased greatly when moderate amounts of cholesterol were added to diets supplemented with saturated fat. Fat in the diet appears to accentuate the effect of cholesterol due to its influence on cholesterol absorption rather than to a metabolic effect of its own (Reiser et al., 1966). Vles et al. (1964) found induction of atherosclerosis in cholesterol-fed rabbits to be enhanced when coconut oil was fed and to be retarded when soybean oil was fed. Lofland, Clarkson and Goodman (1961) found that feeding corn oil to cholesterol-fed pigeons caused a significant lowering of serum cholesterol.

Human serum cholesterol levels at birth and during the first few days of post-natal life range from 60 to 80 mg% (Pomeranze, Goalwin and Slobody, 1957). Infants fed an evaporated milk formula during the first four months had serum cholesterol levels of 140 to 180 mg%. If, in lieu



of the evaporated milk formula, a soy-milk formula was fed to the infants, a minimal rise in serum cholesterol was noted. Pomeranze, Goalwin and Slobody (1957) also found that addition of corn oil to the evaporated milk decreased infant serum cholesterol levels significantly. Moses et al. (1957) found similar results when feeding a skimmilk-corn oil mixture to elder ambulatory patients in a hospital. A 25 to 60% decrease in total serum cholesterol was noted in four of seven patients after the regular hospital diet was supplemented with the skimmilk-corn oil mixture. A safflower seed oil formula diet was fed to normal, atherosclerotic and hyperlipemic patients (Steiner, Varson and Rudman, 1957); mean levels of serum cholesterol and phospholipids showed a mean decrease of 21%. Beveridge et al. (1957) suggests that the cholesterol-lowering effect of corn oil is mainly accounted for by its sitosterol content. However, Farquhar and Sokolow (1957) conclude that the serum cholesterol lowering effect of safflower oil is not dependent on its sitosterol content. Safflower oil is a highly unsaturated vegetable oil containing 70% linoleic acid (Farquhar and Sokolow, 1957). Samy and Cama (1964) found oleic acid and cholesterol were necessary in the rat diet for induction of hypercholesterolemia; linoleic acid counteracted this effect.

When Hellman et al. (1957) changed a patient's diet from ad libitum feeding to a 40% butter oil formula, the plasma cholesterol level increased from 478 to 720 mg%. This was accompanied by a 5.4 gm decrease in fecal steroids. The butter diet was replaced by an isocaloric 40% corn oil formula; plasma cholesterol level decreased from 720 to 340 mg% while the fecal sterols increased to a minimum of 9.6 grams.

Gosling, Hayes and Segre-Mackay (1969) found that a diet composed mainly of crushed boiled eggs fed to 21-day-old cockerels induced atherosclerotic lesions and raised serum cholesterol levels five to ten times over controls. Pollak (1957) made the following observations on rabbits fed one egg daily plus their regular chow: (1) a raw whole egg or egg yolk resulted in a threefold increase in blood cholesterol, (2) a soft-boiled or poached egg induced a fivefold increase, (3) a scrambled egg plus one gram of butter yielded an increase of six times, (4) a hard-boiled egg gave a tenfold increase and (5) an egg fried in one gram of butter gave a fourteen-fold increase in blood cholesterol. There are 250 to 300 mg cholesterol per egg.

Downie et al. (1962) fed swine a low-fat diet and diets with 25% of calories as lard; egg yolk; and lard and cholesterol (equal to that of egg yolk). The lard-cholesterol swine had the highest mean serum cholesterol and phospholipid levels, the egg yolk group was next highest and the lard group was slightly above the controls. Swine receiving lipid-rich diets had greater mean platelet adhesiveness. The lard-cholesterol group had the greatest mean area of atherosclerosis.

Fraser and Courtice (1969) have shown that the distribution of cholesterol in thoracic duct lymph of rabbits and rats depends upon the fat content of the diet with which cholesterol is fed; cholesterol is transported in larger lipid particles in the lymph when cholesterol is fed with high levels of triglycerides than when fed with normal rabbit food. Wilkens, De Wit and Bronte-Stewart (1962) proposed that dietary fats, free from cholesterol, exert their effect on serum cholesterol

concentration by causing reabsorption of biliary or endogenous cholesterol. Solubilities of cholesterol in natural and modified triglyceride fat at 37°C were found to be positively correlated with the effects of these fats on the serum cholesterol concentration of rats and man. Cholesterol is more soluble in fats with lower iodine values than in fats with higher iodine values. Cholesterol at a level of 4 to 6% of the dietary fat produced the maximum rise in serum cholesterol.

Not all researchers agree that changes in diet are responsible for the increased risk of coronary heart disease in the past 50 to 60 years. Kahn (1970) suggests that the relationship is not very high and that other environmental factors are probably associated with having raised the risk from that of 50 years ago to the present level.

#### Dietary Carbohydrates

More research in the past several years has been directed toward the relationship of various carbohydrates to hyperlipemia and atherogenesis. Cheraskin et al. (1967) found a greater frequency of cardiovascular complaints in older persons who consume relatively greater quantities of carbohydrates. Yudkin (1969) singled out sucrose as the dietary sugar most strongly correlated with the development of coronary heart disease. In humans, Malmros (1969) found a greater cholesterologenic response from sucrose than from glucose or starch. Antar et al. (1970) showed that in humans, sucrose in comparison to starch, is definitely hyperlipidemic, but Birchwood et al. (1970) noted this is not the case when a low cholesterol diet which is high in polyunsaturated fatty acids is fed. Hodges et al. (1967) found, when feeding an Oriental-type diet

(protein from vegetable sources; low fat, with the fat primarily from vegetable oils; and an absence of cholesterol) to Westerners, serum triglycerides were very responsive to source of carbohydrates, i.e., rising with sucrose and falling with starch.

Cholesterol-enriched lactose, sucrose, and stock diets were compared in rats by Iritani and Takeuchi (1969). They found a marked hypercholesterolemia due to the sucrose-cholesterol diet. Not all data are in agreement, however. Kritchevsky, Sallata and Tepper (1968) observed rabbits fed 40% of their diet as either glucose, sucrose, starch or hydrolyzed starch for 33 weeks. Starch was the most hypercholesterolemic and atherogenic of the carbohydrates while glucose was the least.

#### Dietary Protein

Pick, Stamler and Katz (1959) reported that the hypercholesterolemia and atherosclerosis-promoting effect of butter and egg yolk in young cockerels and mature chickens could be prevented by the simultaneous feeding of large amounts of casein or egg albumen. Bohman, Wade and Torrell (1962) suggested that the protein content of alfalfa decreased plasma cholesterol levels in calves. Altschul and Williams (1962) noted a similar lowering of serum cholesterol in sheep and rabbits when alfalfa was fed. Cookson and Federoff (1968) found that ingestion of 300 grams of alfalfa per week by rabbits completely prevented the rise in serum cholesterol due to ingestion of daily doses of cholesterol up to 0.6 gram. Okey and Lyman (1954) measured the effect on rat liver cholesterol storage of the addition of 15% egg albumen to a diet adequate for good growth. Male rats given the extra egg albumen had significantly smaller

amounts of liver cholesterol than did those fed the basal diets. Female rats consistently had lower liver cholesterol values than did the males, but showed no significant decrease with increased protein intake.

However, Lofland, Clarkson and Goodman (1961) found that high levels of dietary protein fed to pigeons lead to higher serum cholesterol values and more severe atherogenesis. Middleton et al. (1967) noted that the level of dietary protein when fed with cholesterol had little effect on serum cholesterol levels of Squirrel monkeys, but severity of aortic and coronary atherosclerosis was enhanced when 25% rather than 9% protein was fed with the cholesterol.

Hodges et al. (1967) noted that as soon as vegetable protein replaced animal protein in the human diet, serum cholesterol levels decreased markedly and remained low regardless of source of carbohydrate (sugar versus starch) or level of fat (15 versus 45% of calories).

### Hypertension

Fries (1969) suggests that hypertension is the most important contributing factor to atherosclerosis. Knieriem and Hueber (1970) and Wilens (1951) reported marked aortic intimal thickening in hypertensive humans. Knieriem and Hueber (1970) noted a marked increase in the thickness of the media in hypertensives when they were compared to normal aortas. Hypertension in rats greatly accelerated the intimal deposition of lipid and formation of foam cells (Still, 1970). This author suggested that in cases of hypertension, the majority of these intimal foam cells are derived from mononuclear cells of the blood. Esterly and Glagov (1963) made the following observations on the renal

arteries of hypertensive rats: vacuolation and degeneration of endothelial cells; adhesion of blood cells to the endothelium; widening of the subendothelial space; appearance of blood cells, macrophages, cell fragments and SMCs in the subendothelial space; vacuolation and degeneration of medial SMCs; and accumulation of extracellular osmiophilic material in the media. Hypertension alters the permeability of the arterial wall. Watts (1963) maintains that in the hypertensive, the greater hydrostatic pressure drives the lipoproteins into the vessel wall, thus increasing lipid deposition.

#### Magnesium

A deficiency of magnesium has been indicated as a possible agent in atherosclerosis. Moore, Hallman and Sholl (1938) and Vitale et al. (1961) found that calves and puppies, respectively, with hypomagnesemia demonstrated aortic calcium deposition. Wener et al. (1964) showed that hypomagnesemia in young dogs caused swelling and degeneration of medial cells and swelling and loss of some of the intimal lining cells together with edema and disorganization of the vessel walls which lead to a reduction in the caliber of the lumen. Rademeyer and Booyens (1965) attributed the hypocholesterolemic effect of saturated fat and maize-meal in rats to the high magnesium content of maize. Magnesium-deficient monkeys showed marked aortic sudanophilia whereas the controls showed very little sudanophilia (Vitale et al., 1963). Vitale et al. (1957) found that, in rats fed an atherogenic diet, aortic intimal sudanophilia could be extensively reduced by feeding large amounts of magnesium. In rabbits, Nakamura et al. (1965) found that aortic sudanophilia could be

enhanced in cholesterol-fed rabbits by feeding a magnesium-deficient diet, but sudanophilia could not be reduced by feeding a high magnesium diet. Adams et al. (1964) observed that orally administered magnesium had neither anti-atherogenic nor hypocholesterolemic effects in the cholesterol-fed rabbit.

### Body Cholesterol

Circulating cholesterol is derived almost exclusively from three sources, diet and endogenous synthesis in liver and intestinal tract (Lindsey and Wilson, 1965). The liver and intestinal tract account for 90% of cholesterologenesis of the whole body in the rat (Dietschy and Siperstein, 1967). There are several factors governing the amount of body cholesterol. The conversion of cholesterol into the bile acids and subsequent fecal excretion represents the major pathway of cholesterol disposition (Kelly et al., 1957 and Siperstein and Chaikoff, 1955). Dietschy (1968) suggests that bile salts may also play a role in inhibiting intestinal cholesterol synthesis.

Man's principle protection from diet-induced hypercholesterolemia is his limited capacity for absorption by the intestine (Taylor and Ho, 1967 and Wilson, Lindsey and Dietschy, 1968). In man there is a continuous unaltered rate of delivery of endogenously synthesized cholesterol to the plasma regardless of dietary absorption, i.e., there is an essential absence of a hepatic "feedback" mechanism (Taylor and Ho, 1967).

Reiser et al. (1966), Cox et al. (1954) and Chung, Tsai and Lai (1970) found hepatic cholesterol synthesis to decrease substantially when cholesterol was fed to rats, monkeys and young chickens, respectively. Cholesterol synthesis in the rat aorta is not inhibited by dietary cholesterol (Reiser et al., 1966). Stout (1969) found insulin stimulates cholesterol synthesis in the rat aortic wall. Cayen (1969) and Cox et al. (1954) found hepatic suppression of cholesterol synthesis when cholesterol was fed to rats and monkeys, respectively, but did not find a change in the rates of intestinal cholesterol synthesis in either species.



## SECTION I - ATHEROSCLEROSIS IN RUMINANTS

Atherosclerosis is a principal cause of death and morbidity in humans in the United States. Because of the ruminant's unique digestive and metabolic characteristics, it may be a very useful research animal for study of this disease. There have been, however, only limited reports of atherosclerosis in ruminants. Likar, Likar and Robinson (1966b) found spontaneous gross lesions in 53.5% of aortas from 200 Massachusetts cows. Skold, Jacobson and Getty (1967) reported spontaneous atherosclerotic plaques in the abdominal aortas of Iowa cattle. Stehbens (1965) observed spontaneous intimal proliferation and lipid deposition in the cerebral arteries of Australian sheep and steers. Roser and Magarey (1964) found lipid staining areas in 75% of the aortas or coronary arteries of lambs; the incidence rose to 97% in aged sheep. Jennings, Jennings and Burton (1969) found cardiovascular lesions in all of 19 male Red deer taken from an island near Scotland. Stout and Bohorquez (1969) reported atherosclerosis in Cervidae kept in zoos. Atherosclerosis in the African buffalo was reported by McKinney (1968).

The purpose of the present study was to determine the incidence of spontaneous atherosclerosis in selected domestic and wild ruminants under various environmental conditions, to appraise the atherosclerotic lesions histologically and to determine plasma and liver cholesterol levels in some of the animals.

## Materials and Methods

Aortas from six 6-month-old calves, 11 aged ewes, 10 goats<sup>1</sup> (five males and five females), 35 wild native White-tailed deer<sup>2</sup> (24 males and 11 females) and nine wild Alaskan caribou<sup>3</sup> (six males and three females) were examined grossly and histologically. The goats, deer and caribou ranged in age from young to old. Four of the calves (two males and two females) received whole milk by nipple, for 180 days; the other two calves (males) were fed a concentrate mixture<sup>4</sup> and a limited amount of milk for 31 days and the concentrate mixture from 31 to 180 days. In the young ruminant ingestion of milk by sucking causes closure of the esophageal groove thereby bypassing the rumen and directing liquid to the abomasum (Webster, 1930; Wise and Anderson, 1939; Hegland et al., 1957; and Ørskov and Benzie, 1968). This reflex can be maintained until the animal is a year or more of age (Webster, 1930 and Ørskov and Benzie, 1968). All calf diets were supplemented with vitamins and minerals. The complete dietary history of the other animals was not known.

---

<sup>1</sup> Provided through the courtesy of Dr. L. H. Schultz, Department of Dairy Science, University of Wisconsin, Madison.

<sup>2</sup> Obtained at DeSoto Bend National Wildlife Refuge. The deer were obtained and aged with the help of Dr. A. O. Haugen, Iowa Cooperative Wildlife Research Unit, ISU, Ames, Iowa.

<sup>3</sup> Obtained south of Fairbanks.

<sup>4</sup> Composition, in %: ground corn, 40; crimped oats, 27; soybean meal, 20; molasses, 10; dicalcium phosphate, 2; and trace mineral salt, 1.

All aortas were fixed in 10% neutral buffered formalin. Gross detection of lipid was determined by staining with Sudan IV (Holman et al., 1958b). Blocks of tissue were taken from fatty streaks, lesions and grossly "normal" areas for preparation of slides for light microscopy.

A Technicon Auto-Analyzer<sup>5</sup> was used to determine total cholesterol in plasma and liver extracts. The latter were prepared by homogenization of about 750 mg lyophilized liver for 45 seconds in isopropanol with a teflon tissue grinder<sup>6</sup>. The homogenate and rinse were poured into 125 ml Erlenmeyer flasks and sealed with Parafilm<sup>7</sup> and rubber stoppers. The samples were then put on a wrist-action shaker<sup>8</sup> for at least 24 hours.

After removal from the shaker, samples were transferred to 250-ml centrifuge bottles. The flasks were rinsed with isopropanol, and the rinsings were also added to the centrifuge bottles. The samples then were centrifuged. The supernatant from each sample was decanted into a 200-ml beaker and reduced to a volume of about 5 ml in a high velocity exhaust hood. Subsequently, the extract was transferred to a 10-ml volumetric flask; the beaker was rinsed with isopropanol, and the rinsings were added to the flask. Isopropanol was added to increase total volume to 10 milliliters. Five-tenths ml of this extract was then extracted in the same manner as suggested by Technicon (1965).

---

<sup>5</sup> Technicon Instruments Corp., Chauncey, New York.

<sup>6</sup> Arthur H. Thomas Co., Philadelphia.

<sup>7</sup> American Can Company, Neenah, Wisconsin.

<sup>8</sup> Burrell Corp., Pittsburg, Pennsylvania.


## Results and Discussion

Sudanophilic streaking was noted grossly in the aortas of three of four milk calves, but not in the calves fed limited-milk and grain. All ewes, five goats, six deer and three caribou had gross sudanophilic lesions. The aortas from all animals had some degree of intimal thickening. This observation of intimal thickening in the very young and in such animals as the nomadic caribou that have liberal exercise would lend support to the hypothesis that intimal thickening is a normal physiological process that varies in different blood vessels as well as with age and species (Levene, 1956(a, b); Stehbens, 1965; Getty, 1966; and Taher and Berg, 1969). Prior and Jones (1952) found a positive correlation between intimal thickenings in human infants and atherosclerosis in adults. Fangman and Hellwig (1947), Prior and Jones (1952), Moon (1957), Levene (1956 a, b) and Stehbens (1964) suggest that intimal thickening may be an integral precursor in the pathogenesis of atherosclerosis.

Calcium deposition as evidenced by Von Kossa calcium stain was observed in aortas of one milk-fed calf, eight ewes, one goat, three of six deer examined and two caribou. The nature of the calcium deposits in the calf aorta is shown in Figure 1.1; some ewe aortas showed similar deposits. Most of the calcium deposits in the aortas of the ewes, however, were as shown in Figure 1.2; i.e., large deposits of calcium in the tunica media. In one of the deer (a 200-pound 5½-year-old female), calcium was deposited at the junction of the intima and media as well as at the junction of the adventitia and media (Figure 1.3). In the other two deer, calcium was deposited only at the junction of the intima

Figure 1.1. Abdominal aorta from milk-fed Holstein calf. Note stippled calcium deposition adjacent to the internal elastic membrane (arrows) between the tunica intima (I) and tunica media (M). Von Kossa calcium stain. Line scale = 50  $\mu$ .

Figure 1.2. Abdominal aorta from an aged ewe. Part of a large calcium deposit (arrows) in the tunica media (M) has been dislodged during sectioning. Much lipid is present in the tunica intima (I) as evidenced by the red stain (black in print). Mayer's Hematoxylin and Oil-Red-O. Line scale = 100  $\mu$ .



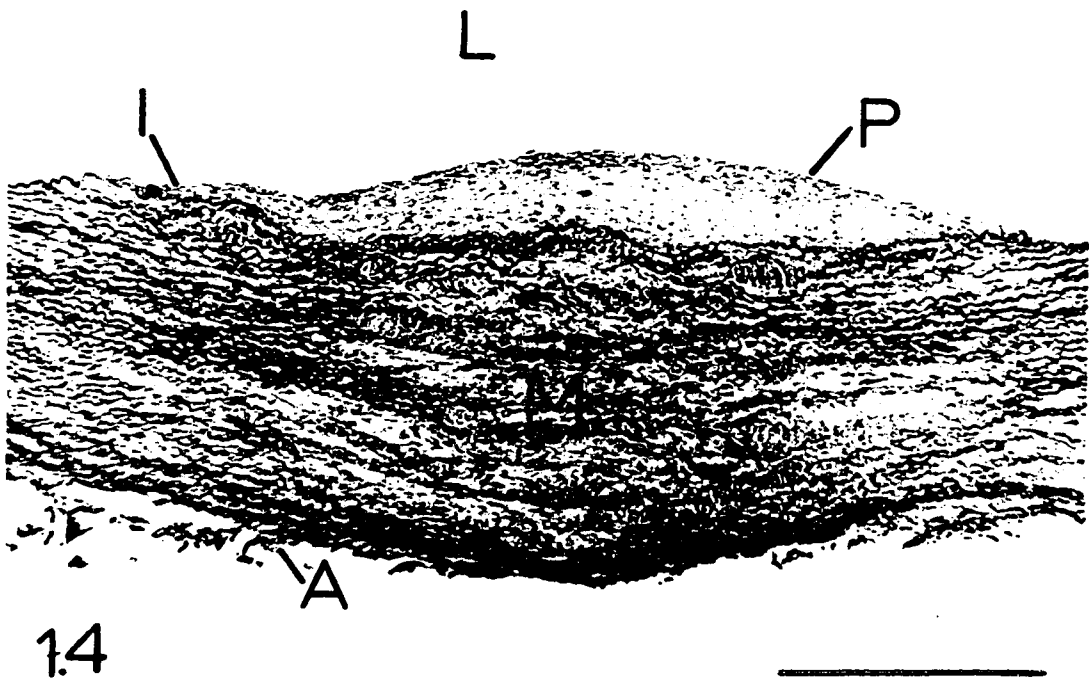

and media. Jennings, Jennings and Burton (1969) observed "massive calcium deposits" in the media of three stags. Roser and Magarey (1964) and Knieriem, Kao and Wissler (1968) reported intimal calcification in ovine and bovine, respectively. In our present study, histological observations of sections stained with Oil-Red-O revealed lipid in the tunica intima of three milk calves, all ewes (Figure 1.2), six goats, four deer and three caribou.

Large plaques were found in each species, as exemplified by the cross-section of a deer aorta (Figure 1.4). There was duplication and disruption of the internal elastic membrane in the plaque area. Elastic tissue degeneration is involved in the development of atherosclerosis (Ehrich, De La Chapelle and Cohn, 1931; Gross, Epstein and Kugel, 1934; and Blumenthal, Lansing and Gray, 1950). The circumstances that lead to the degeneration of tissue at the junction of the media and intima may be the key to atherogenesis (Adams and Tuqan, 1961). In many instances, medial degeneration was noted subjacent to the plaque area (Figure 1.4). Constantinides, Booth and Carlson (1960) made similar observations in the rabbit and suggested that medial degeneration may be initiated by medial hypoxia resulting from a local blockage of the lumen-to-media oxygen flow by the atheromatous mass. Knieriem, Kao and Wissler (1968), using an immunohistochemical method, demonstrated smooth muscle cells in the intima of the bovine aorta. Frequently, in the present study, there was a radial orientation of the smooth muscle nuclei at the point of disruption of the internal elastic membrane, as shown in the aorta of a milk-fed calf (Figure 1.5). A migration of the

Figure 1.3. Abdominal aorta from 5½-year-old female deer. Note calcium deposition (arrows) at junction of tunica intima (I) and tunica media (M) and also at junction of tunica media and tunica adventitia (A). Von Kossa calcium stain. Line scale = 100  $\mu$ .

Figure 1.4. Abdominal aorta from 1½-year-old male deer. Note the absence of elastic fibers in the tunica media (M) beneath the plaque (P). I, tunica intima; A, tunica adventitia; L, lumen. Verhoeff's elastic stain. Line scale = 1000  $\mu$ .






smooth muscle cells into the tunica intima is evident. These smooth muscle nuclei were found in the tunica intima of all species examined. It is of interest to note that Antonius and Hill (1968) stated that proliferation of smooth muscle cells may be the initial anatomic lesion of atherosclerosis with lipid accumulation as a secondary and perhaps degenerative feature. Note the cellular infiltration (Figure 1.6) of the intima in a caribou aorta which suggests degenerative changes preceding plaque formation. Lipid deposition and fibroelastic intimal thickenings were discernable with special stains.

Plasma and liver cholesterol levels were determined for some of the animals. At approximately 21 weeks of age the average (and range) of plasma cholesterol levels for the milk-fed calves were 197 (166 to 251) mg/100 ml and for the grain-fed calves 65 (56 to 74) mg/100 ml. The average (and range) of plasma cholesterol levels for the goats were 66 (54 to 86) mg/100 ml and for the ewes were 73 (36 to 134) mg/100 ml. Average (and range) of liver cholesterol, on a dry matter basis, were 1.22 (1.09 to 1.49) % for the milk-fed calves and 0.86 (0.68 to 1.04) % for the grain-fed calves. The goat liver cholesterols expressed on a dry matter basis averaged 0.87% and ranged from 0.66 to 0.96%. The higher plasma and liver cholesterol levels in the milk-fed calves, in contrast to levels in the other animals, reflects their higher cholesterol, 11-14 mg/100 ml milk, (Homer and Virtanen, 1966 and 1967) and fat intake. This is also related to the increased aortic sudanophilia seen in the milk-fed calves. Dietary fat (beef tallow) markedly increases plasma lipid, including cholesterol, in weanling steer calves (Bohman, Wade

Figure 1.5. Abdominal aorta from milk-fed Holstein calf. Observe smooth muscle cells migrating through disrupted internal elastic membrane at site of arrows. Mallory's triple stain. Line scale  $\approx 100 \mu$ .

Figure 1.6. Thoracic aorta from caribou. Note cellular infiltration in area of developing plaque (arrows). Hematoxylin + Eosin. Line scale  $\approx 500 \mu$ .



and Torrell, 1962). It has also been shown (Jacobson, Zaletel and Allen, 1953) that feeding either a crude soybean oil-filled milk or whole milk to young calves increases plasma cholesterol and total lipid.

#### Summary

Atherosclerotic lesions were observed in the abdominal aortas of calves, sheep, goats, deer and caribou. Many histological similarities were seen between domestic and wild ruminants. Plaque formation, fatty streaks, lipid and calcium deposition, internal elastic membrane duplication and disruption and smooth muscle cells in the intima are quite similar to those observed in man and other animals.

Average plasma cholesterol levels for the milk-fed calves, grain-fed calves, ewes and goats, respectively, were 197, 65, 73 and 66 mg/100 ml. Liver cholesterol levels, on a dry matter basis, for milk-fed calves, grain-fed calves and goats, respectively, were 1.22, 0.86 and 0.87%. The observations suggest that whole milk increases plasma cholesterol and aortic sudanophilia in the ruminant. However, it appears that development of atherosclerosis in the older ruminant can occur in the absence of a diet rich in saturated fatty acids and of a high plasma cholesterol.

## SECTION II - EXPERIMENTAL ATHEROSCLEROSIS IN THE YOUNG BOVINE

Although reports of spontaneous atherosclerosis in nonruminants are legion, similar information about ruminants is sparse (Wiggers, Jacobson and Getty, 1971). Moreover, research on experimental atherosclerosis has been restricted largely to the nonruminant. No reports have been found in the literature concerning experimental atherosclerosis in the ruminant. The young ruminant is unique in that it can be limited to essentially a nonruminant state or it can be quickly developed into a ruminant through dietary manipulation. The former can be maintained indefinitely if a fortified milk diet is fed by nipple from birth. The main purpose of the experiment reported herein was to determine the effect of cholesterol supplementation on blood plasma cholesterol levels and atherogenesis in calves fed diets consisting primarily of (1) milk or (2) grain.

### Materials and Methods

Eight male and eight female 4-day-old Holstein calves were divided into four comparable groups and fed as follows for 24 weeks: Group M - whole milk; Group MC - whole milk plus cholesterol in the milk; Group MG - whole milk plus a grain mixture<sup>1</sup> to 4 weeks, then only the grain; Group MGC - whole milk plus grain plus cholesterol in the milk to 4 weeks,

---

<sup>1</sup> Composed of, in %: ground corn, 40; crimped oats, 27; soybean meal, 20; molasses, 10; dicalcium phosphate, 2; and trace mineral salt, 1.

then grain plus cholesterol. All diets were supplemented with chlortetracycline, vitamin A, vitamin D<sub>2</sub> and trace minerals.<sup>2</sup> Cholesterol<sup>3</sup> was fed at the rate of 250 mg per kilogram body weight daily. Whole milk, fed by nipple, was fed at a rate of 10% body weight to the Group M and MC calves whereas Group MG and MGC calves received 3.2 kg per day for the first 3 weeks and 1.8 kg per day for the fourth and final week. Total milk, grain and cholesterol consumptions are presented in Table 2.1. During milk feeding, cholesterol was fed in the milk, thus bypassing the ruminoreticulum. In the young ruminant ingestion of milk by nursing causes closure of the esophageal groove thereby bypassing the ruminoreticulum and directing milk to the abomasum (Webster, 1930; Wise and Anderson, 1939; Hegland et al., 1957; and Ørskov and Benzie, 1969). This reflex can be maintained until the animal is a year or more of age (Webster, 1930 and Ørskov and Benzie, 1968).

All calves were in individual pens equipped with automatic waterers. Each M or MC calf was in a special pen that had an expanded metal screen bottom which was partly covered by a rubber mat. The MG and MGC calves were bedded on wood shavings.

---

<sup>2</sup> Each calf received a daily supplement of 50 mg chlortetracycline, 10,000 I.U. vitamin A, 1,000 I.U. vitamin D<sub>2</sub> and 2.4 g of trace mineral mix composed of, in %: MnSO<sub>4</sub>, 12.5; FeSO<sub>4</sub>, 5.0; FeCO<sub>3</sub>, 10.0; CuSO<sub>4</sub>, 2.0; CoCO<sub>3</sub>, 1.5; ZnO, 4.0; CaIO<sub>3</sub>, 0.2; and CaCO<sub>3</sub>, 64.5.

<sup>3</sup> Nutritional Biochemicals Corporation. 26201 Miles Rd., Cleveland, Ohio 44128.

Table 2.1. Average per-calf feed consumption by 4-week periods

Group	Final week of 4-week period					
	4	8	12	16	20	24
<u>M</u>						
Milk (kg)	129	160	222	300	368	434
Grain (kg)	0	0	0	0	0	0
Fat <sup>a</sup> (kg)	4.5	5.6	7.8	10.5	12.9	15.2
Cholesterol <sup>b</sup> (g)	16	19	26	36	44	52
Cholesterol/Fat, %	0.34	0.34	0.34	0.34	0.34	0.34
<u>MC</u>						
Milk (kg)	126	162	228	296	382	456
Grain (kg)	0	0	0	0	0	0
Fat <sup>a</sup> (kg)	4.4	5.7	8.0	10.4	13.4	16.0
Cholesterol <sup>b</sup> (g)	15	19	27	36	46	55
Cholesterol (g)	346	484	637	824	1060	1241
Cholesterol/Fat, %	8.2	8.8	8.3	8.3	8.2	8.1
<u>MG</u>						
Milk (kg)	80	0	0	0	0	0
Grain (kg)	10	43	68	82	101	102
Fat <sup>a</sup> (kg)	3.1	1.3	2.0	2.4	3.0	3.0
Cholesterol <sup>b</sup> (g)	10	0	0	0	0	0
Cholesterol/Fat, %	0.3	---	---	---	---	---
<u>MGC</u>						
Milk (kg)	80	0	0	0	0	0
Grain (kg)	11	42	68	94	97	101
Fat <sup>a</sup> (kg)	3.1	1.2	2.0	2.8	2.8	3.0
Cholesterol <sup>b</sup> (g)	10	0	0	0	0	0
Cholesterol (g)	357	458	621	784	952	1092
Cholesterol/Fat, %	11.8	37.2	31.0	28.4	33.4	36.8

<sup>a</sup> Estimated fat in the milk and/or grain.

<sup>b</sup> Estimated cholesterol in the milk [11-14 mg cholesterol per 100 ml of milk (Homer and Virtanen, 1966 and 1967)]; a value of 12 used here.



Venous blood samples for plasma cholesterol determination (Technicon, 1965) were taken from each calf at 4-6 days of age (0-time) and at 1, 2, 3, 4, 6, 8, 10, 12, 14, 16, 20 and 24 weeks later. Whole blood glucose, hemoglobin, hematocrits and clotting time also were determined on each sample to determine whether the diet affected these parameters and also to determine the general well-being of the animal. Whole blood glucose was determined on deproteinized blood (Somogyi, 1945); these protein-free filtrates were immediately frozen in six-dram glass vials and kept frozen until Glucose Oxidase Analysis.<sup>4</sup> Oxy-hemoglobin<sup>5</sup> values were determined. Hematocrits were determined by centrifuging whole blood in an International Clinical Centrifuge<sup>6</sup> for 30 minutes at ca. 1780 x gravity. Whole blood clotting times were determined as outlined in the manual for the clot-times<sup>7</sup>. The data for glucose and cholesterol were subjected to statistical analysis by the method of least squares (Snedecor and Cochran, 1967). Calf weights were determined weekly.

At the termination of the experiment (24 weeks) 13 of the 16 calves were slaughtered and the hearts, aortas and livers were removed. The hearts and aortas were fixed in 10% neutral buffered formalin. Gross detection of lipid was determined by staining with Sudan IV

---

<sup>4</sup> Glucostat. Worthington Biochemical Corporation. Freehold, New Jersey 07728.

<sup>5</sup> Bausch and Lomb, 77466 Bausch St., Rochester 2, New York. Clinical Methods and Calibrations Manual, Catalog No. 33-29-46.

<sup>6</sup> International Equipment Co., Boston, Massachusetts.

<sup>7</sup> Mechrolab Inc., 1062 Linda Vista Avenue, Mountain View, California. Model 201, Clot-timer.

(Holman et al., 1958b). Blocks of tissue were taken from fatty streaks, lesions and grossly "normal" areas for histological preparations.

Total liver weights were recorded; core samples of each liver were lyophilized and analyzed for total cholesterol as described previously (Wiggers, Jacobson and Getty, 1971).

### Results and Discussion

The M and MC calves consumed milk quite readily throughout the experiment. Infrequently, diarrhea occurred in these calves.

Growth rates (Figure 2.1) to 12 weeks were quite similar; thereafter, the M and MC calves gained weight more rapidly than the MG and MGC calves.

Whole blood glucose values are shown in Figure 2.2; the difference between ruminating (MG and MGC) and nonruminating (M and MC) calves, regardless of cholesterol supplementation, was highly significant as can be seen in Table 2.2. Young et al. (1970) reported whole blood glucose values for calves fed milk only to 105 days of age; the glucose values reported for the M calves in Figure 2.2 are quite similar up to this age, but for an undetermined reason glucose values increased after this.

Hemoglobin and hematocrit values, Figures 2.3 and 2.4, respectively, were determined at each blood sampling to check for hemodilution and to determine the effects of diet. Hemoglobin values of M and MC calves declined below (but not in the range or gross deficiency) those of MG and MGC calves even though the M and MC calves received supplemental iron equivalent to their estimated requirements. Hematocrit values, as with the hemoglobin data, of the M and MC calves decline with time below those of MG and MGC calves.

Figure 2.1. Growth rates.

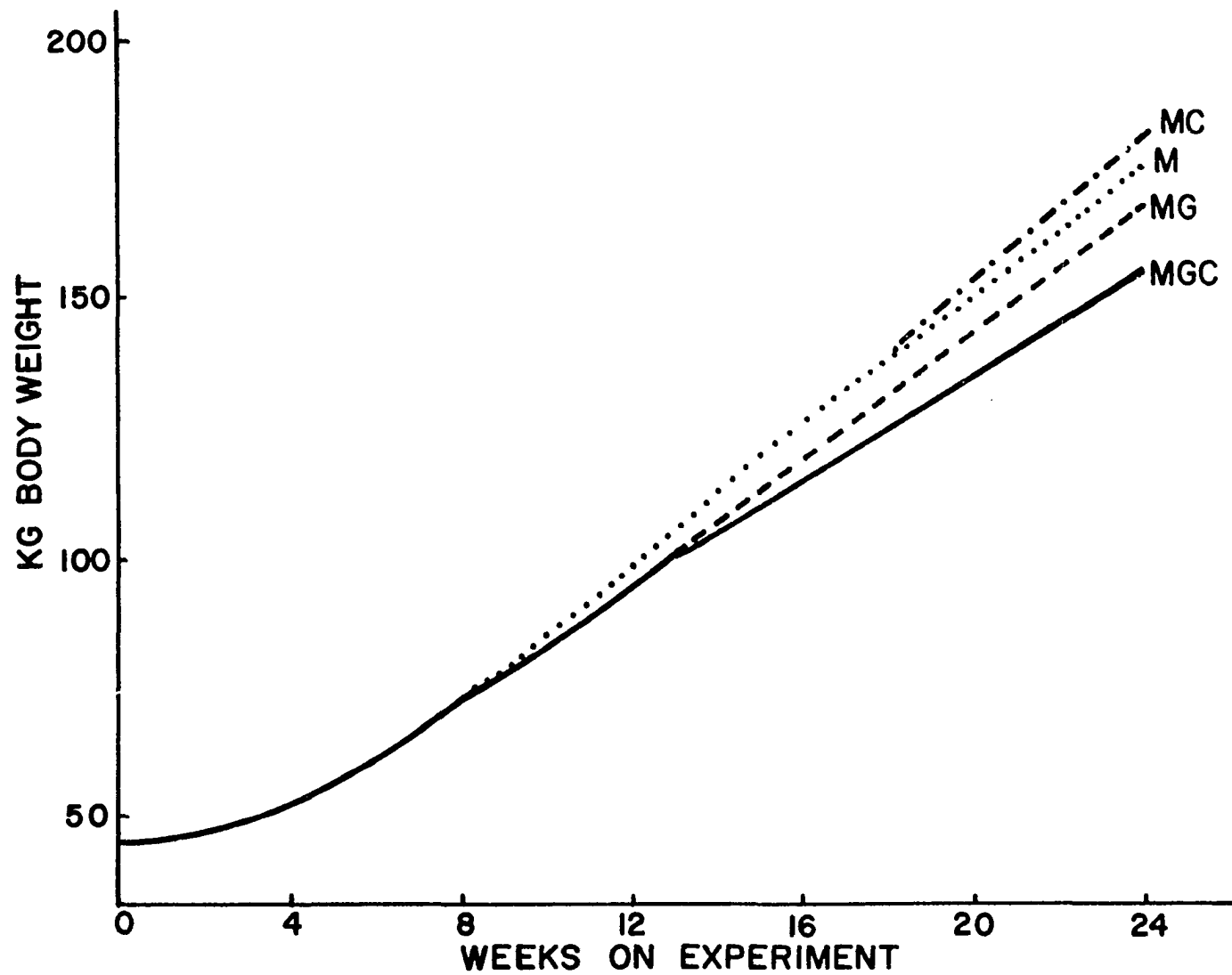


Figure 2.2. Whole blood glucose.

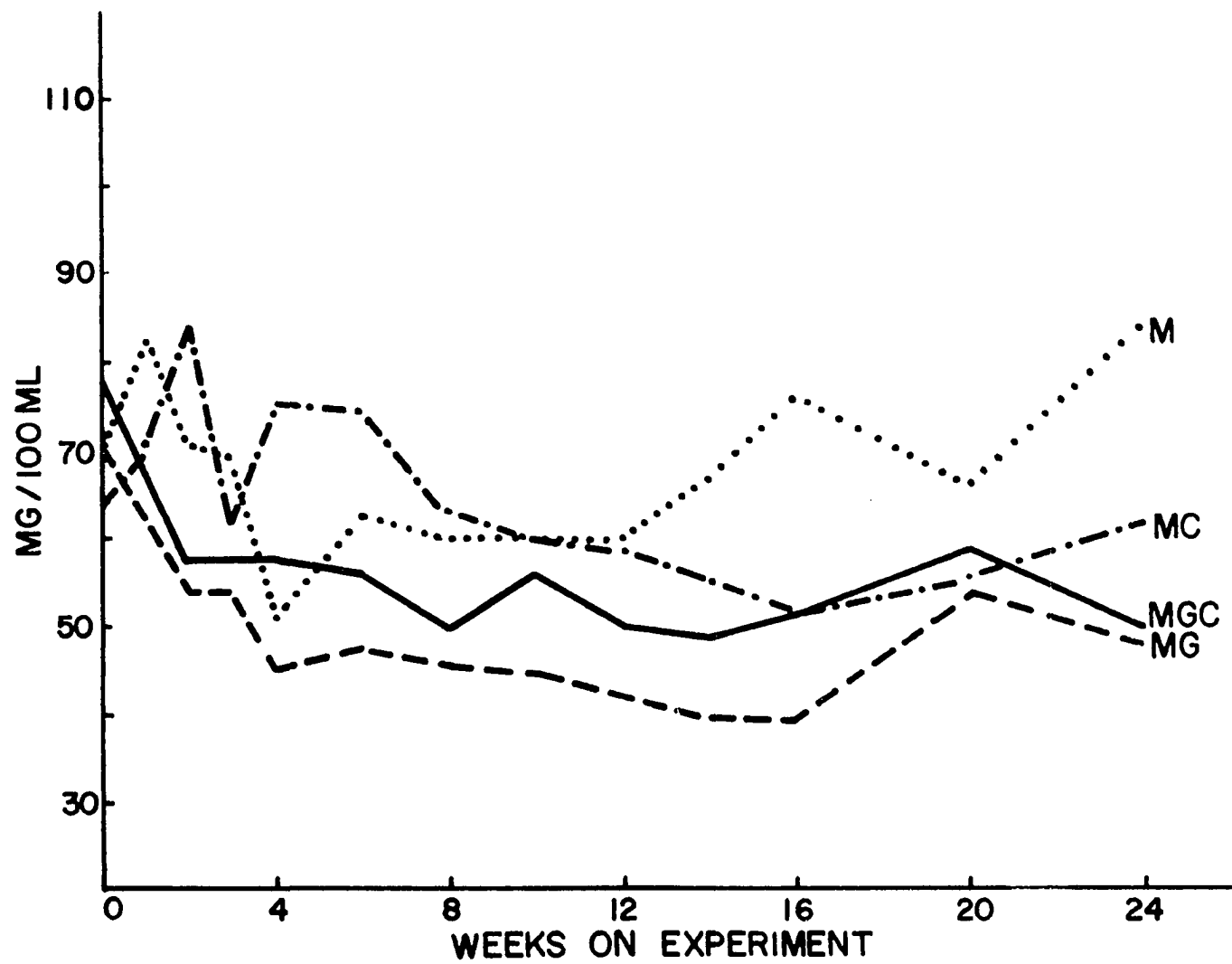


Figure 2.3. Hemoglobin values.

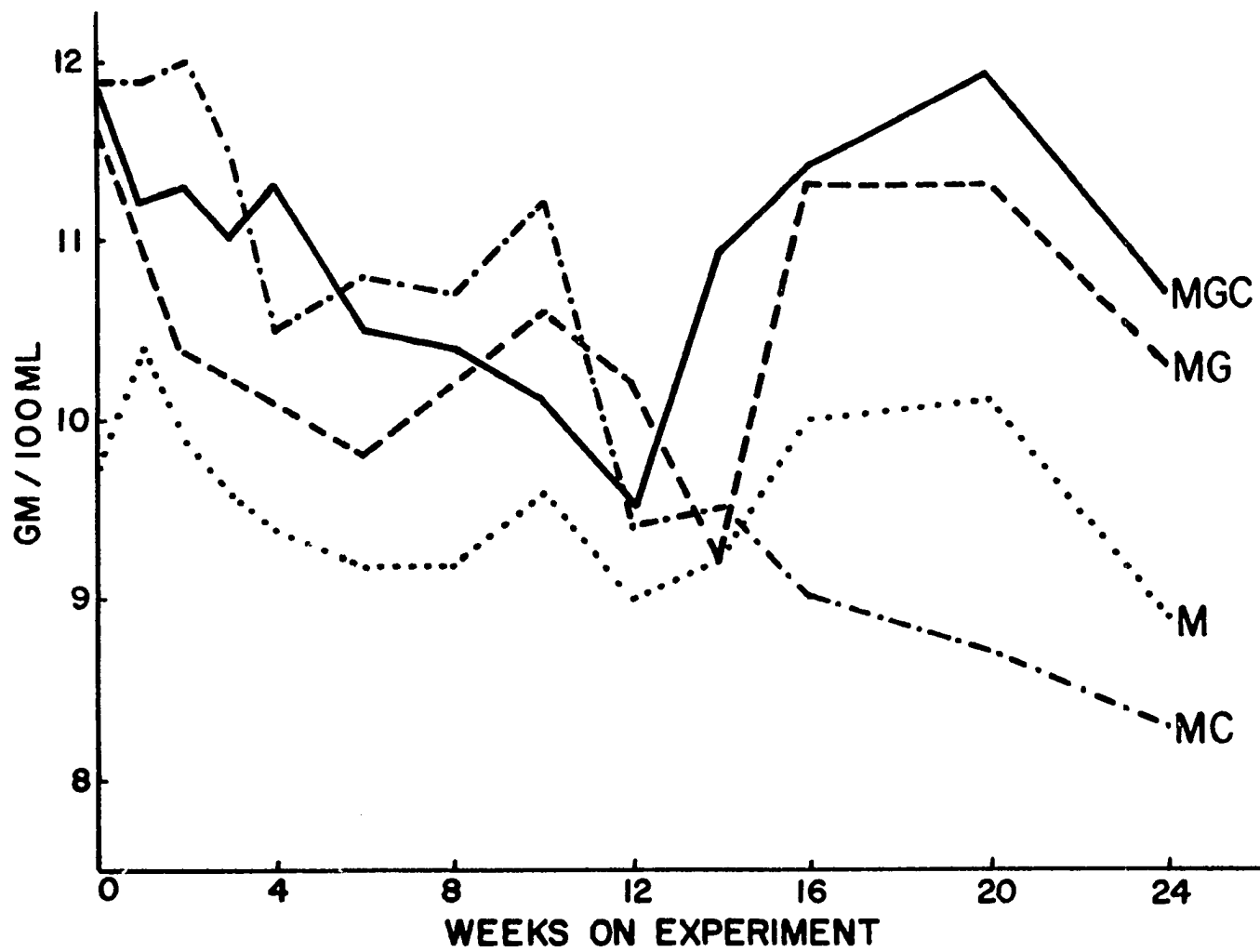




Figure 2.4. Hematocrit (% packed cell volume).

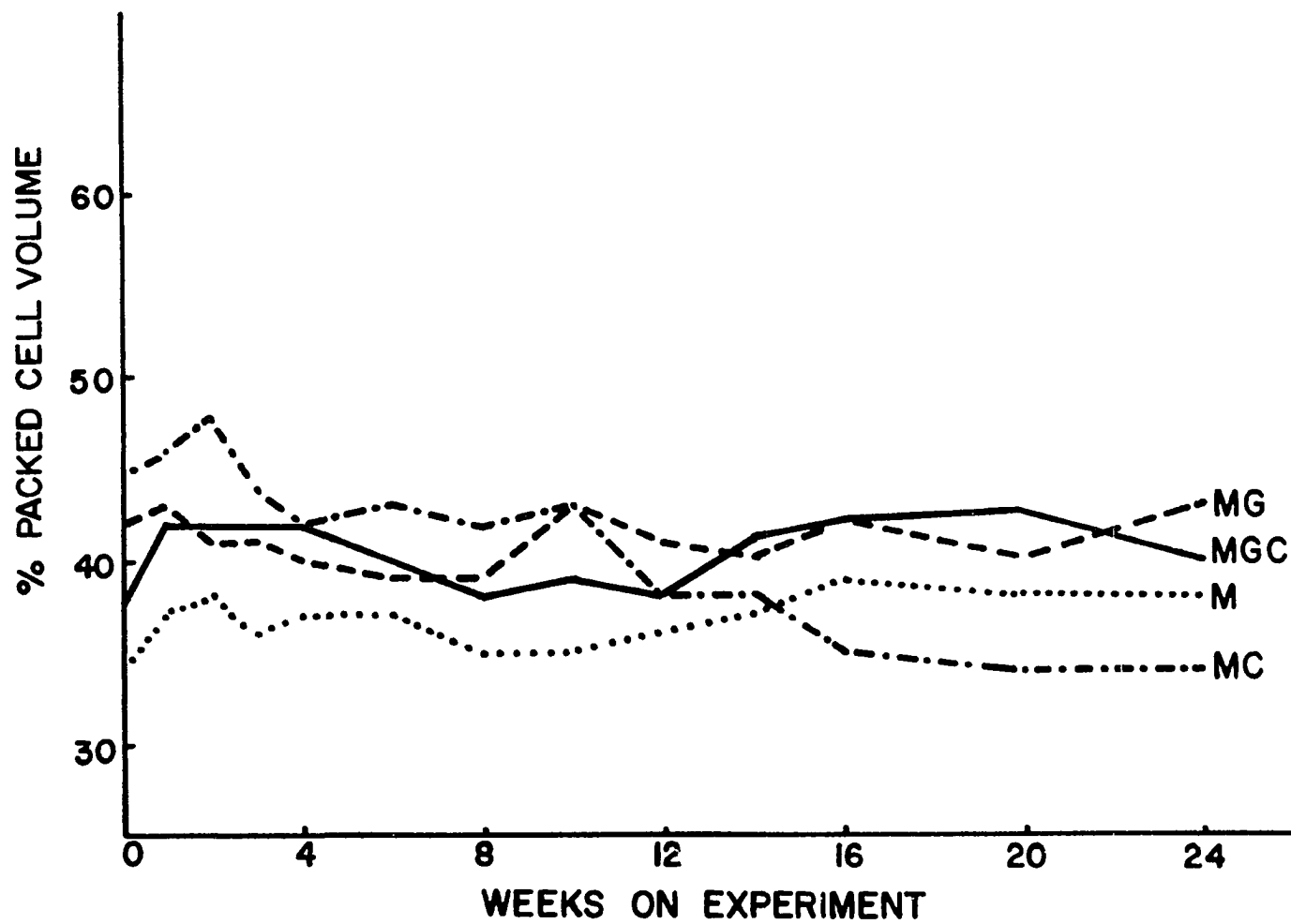


Table 2.2. Analysis of variance of whole blood glucose

Source of variation	d.f.	Mean squares	"F"
M vs. G	1	8806.36	37.559 <sup>**</sup>
C	1	268.98	1.147
M-G x C	1	1300.52	5.547 <sup>*</sup>
Animal/Trt.	12	234.47	1.225
Week	12	639.94	3.343 <sup>**</sup>
Trt. x Week	36	215.28	1.125
Error	141	191.45	

\*  $p < 0.05$ .

\*\*  $p < 0.01$ .

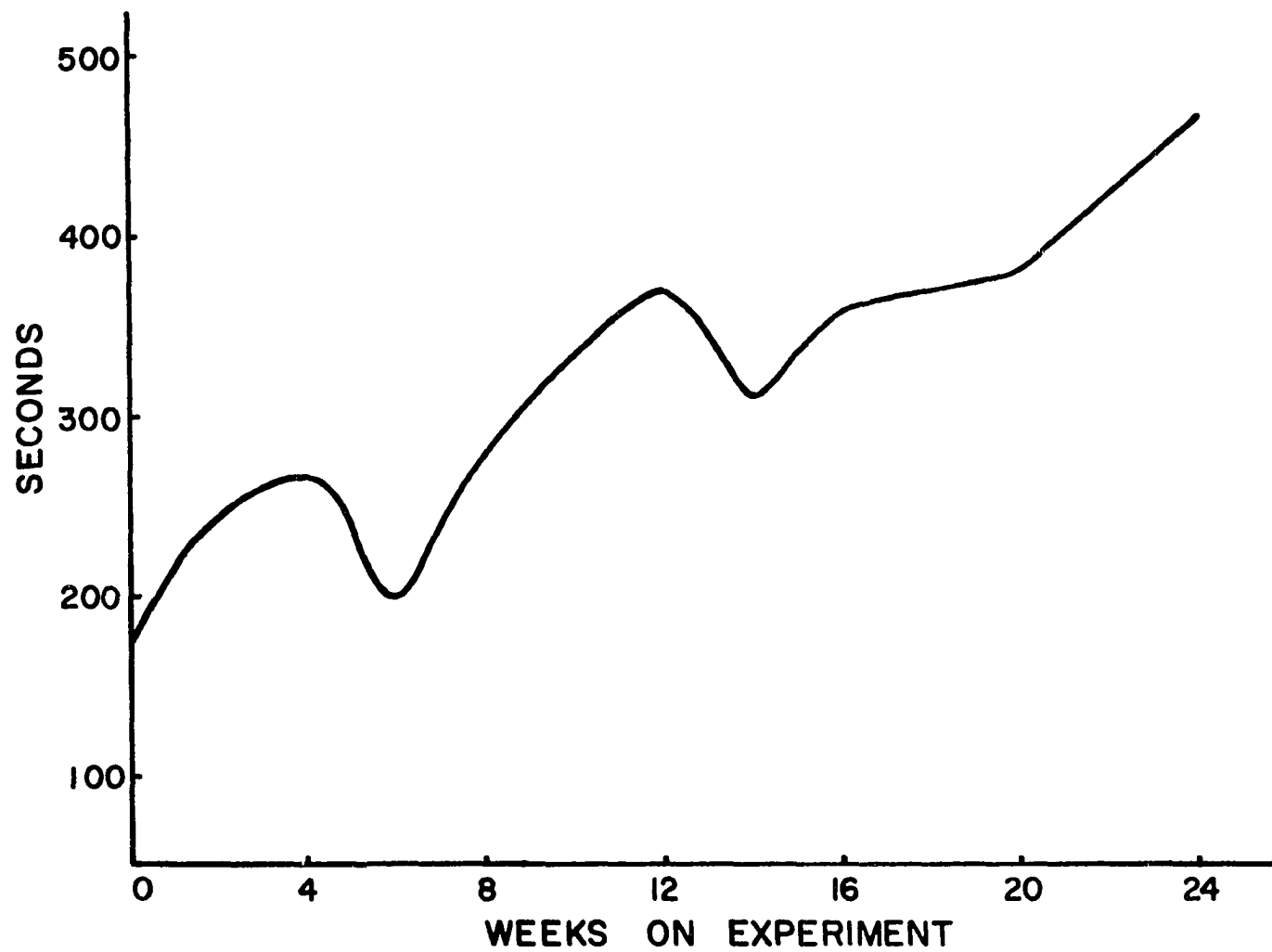
Clotting times did not vary markedly between groups, so they were plotted together as shown in Figure 2.5. The time required for clotting increased as age of calves increased. These data are in accord with observations made by Wangsness and McGilliard<sup>8</sup>; they noted that catheters implanted in blood vessels are rendered nonfunctional by thrombus and/or sheath formation more rapidly in young calves than in older calves.

The analysis of variance in Table 2.3 indicates effects of ration ignoring cholesterol treatment and of cholesterol ignoring type of diet were highly significant; however, a highly significant interaction resulted because the plasma cholesterol response due to addition of cholesterol to M diets was much greater than addition of cholesterol

---

<sup>8</sup> Wangsness, P. J. and A. D. McGilliard, Department of Animal Science, Iowa State University, Ames, Iowa. Private Communication. 1970.

Figure 2.5. Clotting times.



to MG diets. Plasma cholesterol levels (Figure 2.6) of the MGC calves showed a sharp decline at 4 weeks; this decline coincides with the cessation of milk feeding and with change in method of cholesterol administration, i.e., from the milk to the grain.

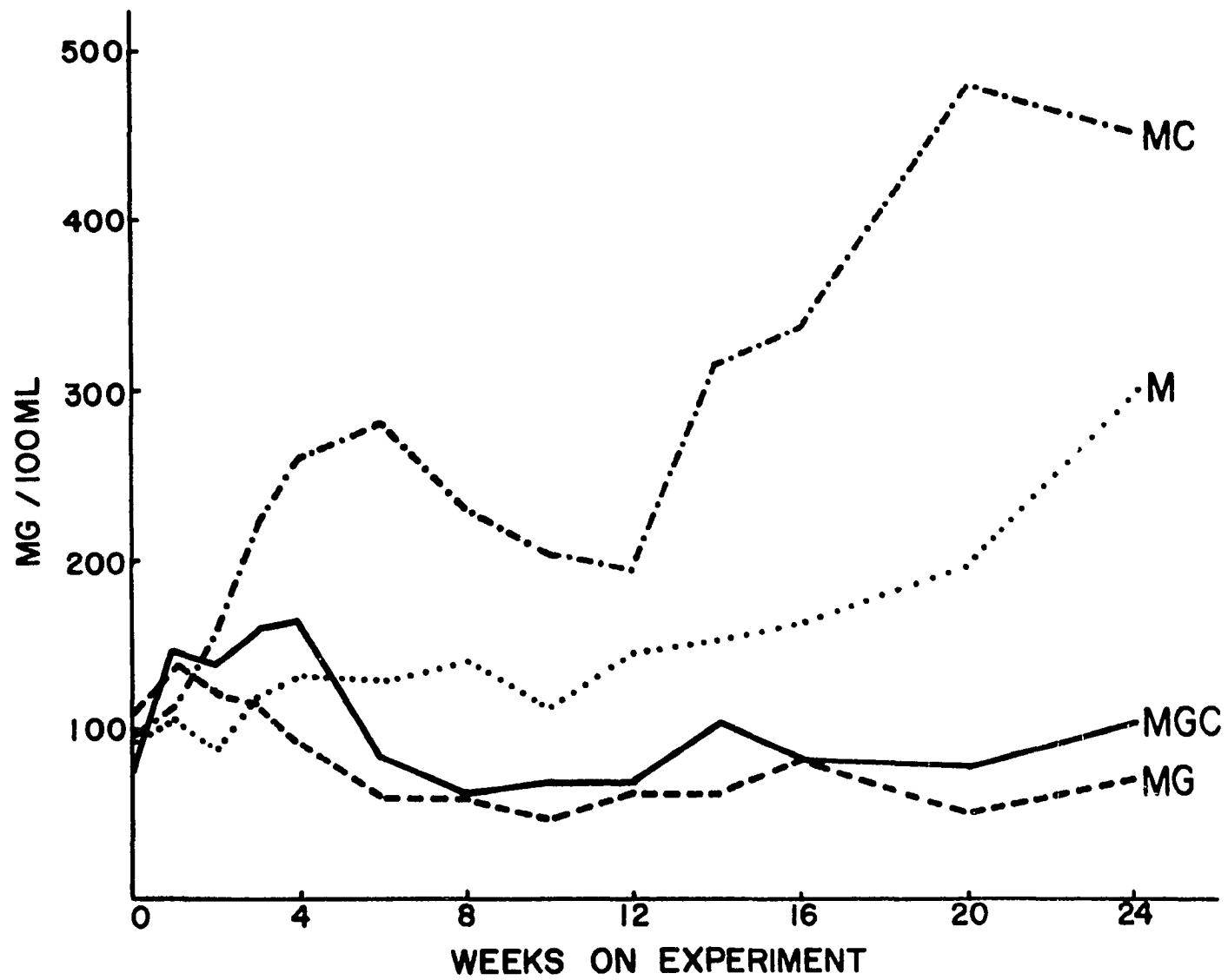
Table 2.3. Analysis of variance of plasma cholesterol

Source of variation	d.f.	Mean squares	"F"
M vs. G	1	594,600	77.151**
C	1	209,057	27.126**
M-G x C	1	92,256	11.970**
Animal/Trt.	12	7,707	3.148**
Week	12	24,646	10.069**
Trt. x Week	36	17,710	7.236**
Error	141	2,448	

\*\*  $p < 0.01$ .

Total estimated fat intakes (Table 2.1) are much higher for the M and MC calves than for the MG and MGC calves. Studies have shown that cholesterol is much more effectively absorbed by the gut when fed in the presence of fat (Connor, Rohwedder and Armstrong, 1967; Cook, 1936; Fraser and Courtice, 1969; and Wilkens, De Wit and Bronte-Stewart, 1962). Due to the relative low fat intake of the MGC calves, cholesterol to fat ratios are much higher than those of the MC calves. Wilkens, De Wit and Bronte-Stewart (1962) noted, in rats and humans, that above 4-6%

Figure 2.6. Plasma cholesterol levels.





of cholesterol dissolved in the fat fed, no further rise in serum cholesterol occurred and a plateau formed; the MC calves dietary cholesterol was very near this percentage. It is quite likely that absorption of dietary cholesterol by the MGC calves was limited by the relatively low fat intake.

Cholesterol fed to the MGC calves was subjected to some degradative action by microorganisms found in the ruminoreticulum. Arima et al. (1969) presents a list of types of microorganisms that decompose cholesterol; at least eight and probably more of these microorganisms are found in the bovine ruminoreticulum.

Cholestanol is one of several products synthesized in the cecum of animals from cholesterol by microbial action. Ito et al. (1969) have studied cholestane-3 $\beta$ , 5 $\alpha$ , 6 $\beta$ -triol (CT), a structural analog of cholestanol. They found that 50 mg of CT in an emulsion with tritiated cholesterol administered intragastrically to rats resulted in a 50% inhibition of cholesterol transfer into the lymph. It is quite possible that CT or a similar compound may be synthesized in the ruminoreticulum and have the same negative effect on cholesterol absorption in the calf.

The weights of the livers and the percent cholesterol in the liver, expressed on a dry matter basis, are shown in Table 2.4. The values for the M, MC, MG and MGC calves represent averages of four, four, two, and three calves, respectively. The total liver cholesterol is greater for the MC calves than for the calves in the other groups.

The aortas from the MC calves (Figure 2.7 and 2.8) showed the most extensive sudanophilia; there was ca. 100% staining of the intimal surface of the aorta of two of the MC calves, ca. 85% in one and ca. 40%

Figure 2.7. Aortas from Group MC calves stained with Sudan IV. Lipid deposition appears as mottled dark areas, especially about the ostia. Line scale = 10 cm.

Figure 2.8. Close-up photograph of thoracic portion of two aortas shown in Figure 2.7. Much lipid deposition is apparent. Line scale = 5 cm.




Table 2.4. Mean liver weights and percent liver cholesterol (dry matter basis)

Treatment	Liver (kg)	% Liver Cholesterol
M	2.94	1.2
MC	3.71	3.7
MG	3.43	0.9
MGC	3.08	1.1

in the other. Aortic intimal sudanophilia is one criterion that may be used to detect the presence and extent of aortic atherosclerosis (Holman et al., 1958b). One M calf aorta showed over 90% sudanophilia but did not stain as intensely as the aortas from the MC calves; the other three M calves showed very slight staining. Sudanophilia was virtually absent in the aortas from the MG and MGC calves.

It is recognized that a deficiency of magnesium has been suggested as a contributing factor to atherogenesis. Duncan, Huffman and Robinson (1935) found calves fed whole milk to exhibit signs of magnesium deficiency. Although, the diets of the M and MC calves were not supplemented with magnesium, other observations<sup>9</sup> suggest that calves fed similarly do not become hypomagnesemic.

Examination of cryostat and paraffin sections with various stains under the light microscope revealed vascular irregularities in aortas

---

<sup>9</sup> Wiggers, K. D. Department of Animal Science, Iowa State University, Ames, Iowa. Unpublished data. 1971.

from all calves; the degree and type of irregularity varied with the treatment. The lipid in the aortas of the M and MC calves was restricted to the intima (Figure 2.9): the aortic intimal lipid was much more widespread in the MC calves than in the M calves. McMartin et al. (1970) have also noted very limited aortic intimal lipid in mature Holstein cows. Staining with Schultz's cholesterol stain showed cholesterol to be coextensive with Oil-Red-O lipid (Figure 2.10). Aortic calcium deposition (Figures 2.11 and 2.12) was noted in all calves. Calcium was noted along the internal elastic lamina as in Figure 2.11 and also subjacent to the internal elastic lamina as in Figure 2.12. The calcium deposition in Figure 2.11 would appear granular as in Figure 2.12 under higher magnification. The calcium deposition in the aortas of M and MC calves was generally spread along the internal elastic membrane (Figure 2.11) while the deposition was more spotty in the aortas of the MG and MGC calves (Figure 2.12).

Aortic intimal thickening was more pronounced in the M and MC calves (Figure 2.13) than in the MG and MGC calves (Figure 2.14). The intimae seem to contain the same cell-types, the identity of which cannot be discerned under the light microscope. Some of the intimal nuclei have an appearance quite similar to the smooth muscle cell (SMC) nuclei in the media. Using electron microscopic techniques and immunohistochemical methods, respectively, Knieriem (1967) and Knieriem, Kao and Wissler (1968) noted the presence of SMCs in bovine arterial lesions. Duff, McMillan and Ritchie (1957) using light microscopy classified rabbit aortic intimal cells beneath an intact endothelium as fibrocytes,

Figure 2.9. Intimal lipid deposition (black in print) in abdominal aorta of MC calf. Oil-Red-O + Mayer's hematoxylin. Line scale = 100  $\mu$ .

Figure 2.10. Intimal cholesterol deposition in abdominal aorta of MC calf. Schultz cholesterol stain. Line scale = 100  $\mu$ .




Figure 2.11. Section from abdominal aorta of MC calf showing large plaque and calcium deposition (arrow). Von Kossa. Line scale = 1000  $\mu$ .

Figure 2.12. Section from abdominal aorta of MG calf showing granular calcium deposition subjacent to the internal elastic lamina. Von Kossa. Line scale = 100  $\mu$ .



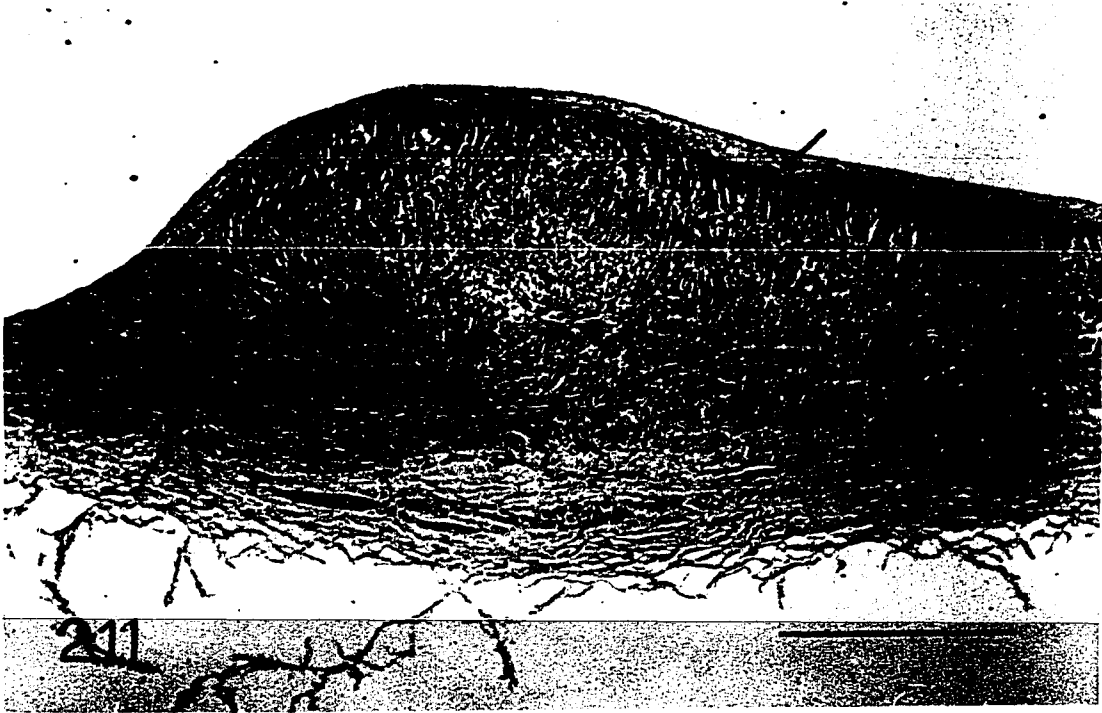



Figure 2.13. Abdominal aorta of MC calf showing thickened intima with a variety of cell types. Hemotoxylin + Eosin. Line scale = 100  $\mu$ .

Figure 2.14. Abdominal aorta of MG calf with intimal thickening showing some of the same cell-types as in Figure 2.13. Hematoxylin + Eosin. Line scale = 100  $\mu$ .



histiocytes and monocytoïd cells. Lee et al. (1970) using electron microscopy classified these subendothelial cells into three groups: SMC-like, 30%; monocyte-like, 40%; and unclassified, consisting of cells without specialized features, 30%. Some of the subendothelial cells in Figures 2.13 and 2.14 appear to be a form of one of the monocyte series (Bloom and Fawcett, 1968); they also present the characteristics of plasmacytes which according to Platt (1969) are variants of lymphocytes. Plasmacytes contain large amounts of  $\gamma$ -globulins; they play an important role in resistance to disease. It is not unreasonable to assume that cells of this type may be present since plasmacytes are plentiful in highly cellular connective tissue (Bloom and Fawcett, 1968).

Disruption and duplication of the internal elastic lamina occurred in all calves, although it was much more prevalent in the M and MC calves. Figure 2.15 shows some duplication of the internal elastic lamina and perhaps an incipient plaque in the aorta of an MG calf. Knieriem (1967) observed that aortic medial SMCs migrate into the intima through fenestrations in the internal elastic lamina. Breaks in the internal elastic lamina are evident in the aorta from an M calf (Figure 2.16); a higher magnification (Figure 2.17) shows an apparent migration of medial SMCs into the intima.

Large plaques were noted in some aortas of the MC calves as noted in Figure 2.11; a higher magnification is shown in Figure 2.18. Some of the cells in the media of the plaque are similar to the subendothelial cells of the intima. Considering that the entire media involved in plaque-formation is of a different cell-type (Figure 2.19) than the

Figure 2.15. Abdominal aorta from MG calf showing duplication of internal elastic membrane (arrows) and what may be an incipient plaque. Hematoxylin + Eosin. Line scale = 100  $\mu$ .

Figure 2.16. Abdominal aorta from M calf showing disruption of the internal elastic membrane. Mallory's triple stain. Line scale = 200  $\mu$ .



Figure 2.17. Abdominal aorta from an M calf showing a higher magnification of one of the disruptions of the internal elastic lamina shown in Figure 2.16. There is a radial orientation of medial smooth muscle nuclei at the disruption. Mallory's triple stain. Line scale = 100  $\mu$ .

Figure 2.18. Abdominal aorta from an MC calf showing a higher magnification of an adjacent section to that in Figure 2.11. This represents an area on the left shoulder of the plaque. Some medial cells are similar to those found in the intima. Hematoxylin + Eosin. Line scale = 100  $\mu$ .


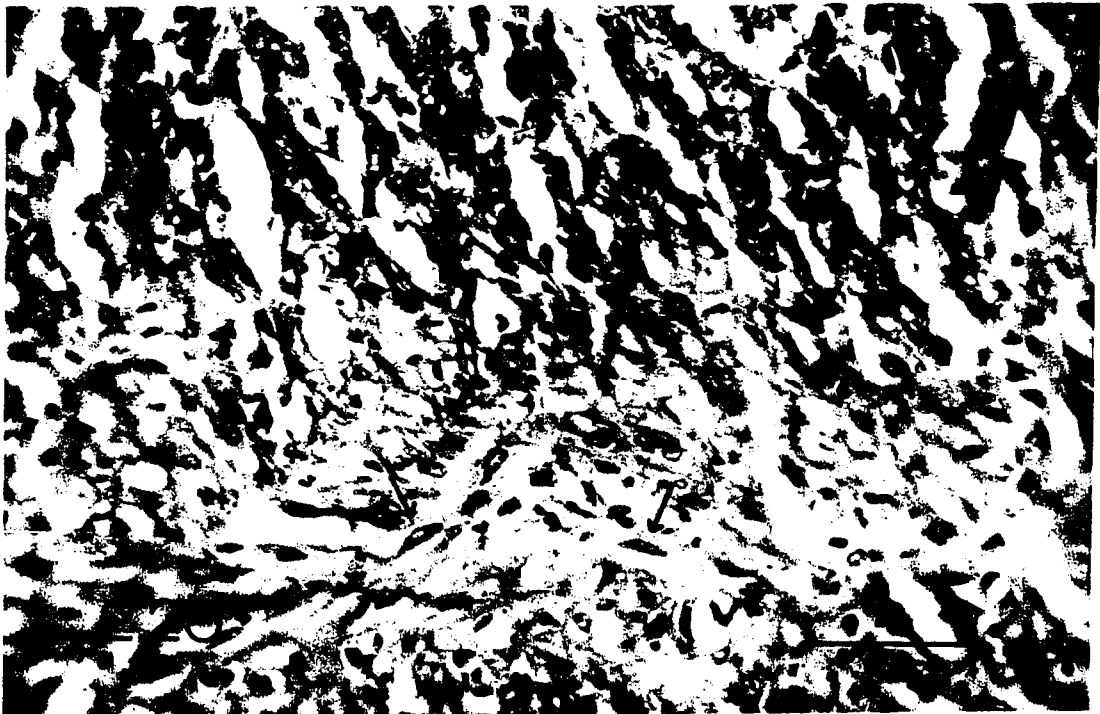





Figure 2.19. Abdominal aorta from an MC calf. A cell-type other than the conventional medial SMC is present in the media subjacent to the plaque. Hematoxylin + Eosin. Line scale = 200  $\mu$ .

Figure 2.20. Abdominal aorta from an MC calf showing a higher magnification taken deep in the media of the section illustrated in Figure 2.18. SMC-like cells (arrows) may be transitory between SMCs and the other common cell-type found subjacent to plaques. Hematoxylin + Eosin. Line scale = 50  $\mu$ .



conventional medial SMC, I think it quite likely that these cells derive from SMCs. A photomicrograph (Figure 2.20) of higher magnification taken deep in the media of the plaque shown in Figures 2.11 and 2.18 shows what may be an intermediate stage between the "conventional medial SMC" and the type of medial cell found under a plaque.

#### Summary

This study relates several dietary regimes (M, MC, MG and MGC) fed to Holstein calves to atherogenesis. Plasma cholesterol levels were quite responsive to diet. Cholesterol supplementation to calves fed milk only caused a marked increase in plasma cholesterol levels whereas the same level cholesterol supplementation to calves fed a predominantly grain diet had no apparent effect. The amount of cholesterol stored in the liver was much higher in calves fed milk and cholesterol than in calves fed grain and cholesterol. Gross aortic sudanophilia was very extensive in calves fed milk and cholesterol, less so in calves fed milk only and virtually absent in calves fed milk and grain or milk, grain and cholesterol. Histological examination revealed aortic lipid to be confined to the intima; cholesterol was found to be coextensive with the lipid. Some aortas from calves in each group had deposits of calcium. Aortas from calves in all treatments showed some evidence of vascular degeneration but the degeneration was much more extensive in calves fed milk-cholesterol.

### SECTION III - EXPERIMENTAL ATHEROSCLEROSIS AND CHOLESTEROL ABSORPTION IN THE YOUNG BOVINE

This experiment was designed to answer questions raised by the previous study where four groups of calves were fed to 6 months of age as follows: (1) milk only, (2) milk plus cholesterol in the milk, (3) limited milk plus grain to 4 weeks then grain only, and (4) limited milk plus cholesterol in the milk to 4 weeks then grain plus cholesterol. Plasma cholesterol levels and atherogenesis were much greater in calves fed milk plus cholesterol than in calves fed milk-grain plus cholesterol. Cholesterol fed in grain enters the ruminoreticulum whereas cholesterol fed in milk bypasses the ruminoreticulum and enters the omaso-abomasum directly. It seemed possible that the lower plasma cholesterol level of grain-cholesterol calves, as compared to milk-cholesterol calves, may have been due either to degradation of cholesterol in the ruminoreticulum or to decreased absorption because of the lower fat content of the diet or both. The present study was designed to help clarify the relative contribution of these factors.

#### Materials and Methods

Twelve male Holstein calves were allotted to three comparable groups and from 4 days to 6 months of age were fed as outlined in Table 3.1. Total feed consumption is presented in Table 3.2. All diets were supplemented with chlortetracycline, vitamin A, vitamin D<sub>2</sub> and

Table 3.1. Treatments

Group	Whole milk (by nipple)	Grain <sup>a</sup>	Cholesterol <sup>b</sup>
I	10% body weight to 6 months	none	250 mg/kg body weight daily, in milk
II	3.2 kg/day, 4-24 days 1.8 kg/day, 25-31 days 1.0 kg/day, 32 days to 6 months	<u>ad libitum</u>	250 mg/kg body weight daily, in milk
III	3.2 kg/day, 4-24 days 1.8 kg/day, 25-31 days none, 32 days to 6 months	<u>ad libitum</u>	250 mg/kg body weight daily, in milk to 31 days, in grain thereafter

<sup>a</sup> Composed of, in %: ground corn, 40; crimped oats, 27; soybean meal, 20; molasses, 10; dicalcium phosphate, 2; and trace mineral salt, 1.

<sup>b</sup> Nutritional Biochemicals Corporation, 26201 Miles Rd., Cleveland, Ohio 44128.

trace minerals<sup>1</sup>. Two calves in each group were slaughtered at 6 months; the other two were changed to a diet of grain and slaughtered at 9 months to determine if regression of atherosclerotic plaques would occur.

---

<sup>1</sup> Each calf received a daily supplement of 50 mg chlortetracycline, 10,000 I.U. vitamin A, 1,000 I.U. vitamin D<sub>2</sub> and 2.4 g of trace mineral mix composed of, in %: MnSO<sub>4</sub>, 12.5; FeSO<sub>4</sub>, 5.0; FeCO<sub>3</sub>, 10.0; CuSO<sub>4</sub>, 2.0; CoCO<sub>3</sub>, 1.5; ZnO, 4.0; CaIO<sub>3</sub>, 0.2; and CaCO<sub>3</sub>, 64.5.

Table 3.2. Average per-calf feed consumption by 4-week periods

Group	Final week of 4-week period					
	4	8	12	16	20	24
<u>I</u>						
Milk (kg)	136	168	220	293	365	446
Grain (kg)	0	0	0	0	0	0
Fat <sup>a</sup> (kg)	4.7	5.9	7.7	10.2	12.8	15.6
Cholesterol <sup>b</sup> (g)	16	20	26	35	44	54
Cholesterol (g)	368	466	607	794	1008	1219
Cholesterol/Fat, %	8.2	8.2	8.2	8.1	8.2	7.8
<u>II</u>						
Milk (kg)	80	28	28	28	28	28
Grain (kg)	5	28	58	92	106	145
Fat <sup>a</sup> (kg)	3.0	1.8	2.7	3.7	4.1	5.3
Cholesterol <sup>b</sup> (g)	10	3	3	3	3	3
Cholesterol (g)	348	421	571	786	988	1241
Cholesterol/Fat, %	12.1	23.0	21.2	21.4	24.2	23.5
<u>III</u>						
Milk (kg)	80	0	0	0	0	0
Grain (kg)	6	42	74	92	108	141
Fat <sup>a</sup> (kg)	3.0	1.2	2.2	2.7	3.2	4.1
Cholesterol <sup>b</sup> (g)	10	0	0	0	0	0
Cholesterol (g)	362	444	607	791	982	1210
Cholesterol/Fat, %	12.1	35.5	28.0	29.3	30.8	29.2

<sup>a</sup> Estimated fat in the milk and/or grain.

<sup>b</sup> Estimated cholesterol in the milk [11-14 mg cholesterol per 100 ml of milk (Homer and Virtanen, 1966 and 1967)]; a value of 12 was used here.

In the young ruminant, ingestion of milk by nursing causes closure of the esophageal groove; thus the ruminoreticulum is bypassed and milk is directed to the omaso-abomasum (Webster, 1930; Wise and Anderson, 1939; Hegland et al., 1957 and Ørskov and Benzie, 1968). This reflex can be maintained until the animal is a year or more of age (Webster, 1930 and Ørskov and Benzie, 1968). Consequently, cholesterol fed in the milk also bypasses the ruminoreticulum.

All calves were in individual pens equipped with automatic waterers. Each Group I calf was in a special pen with an expanded metal screen bottom which was partly covered by a rubber mat to provide comfort for the calf. The other calves were bedded on wood shavings.

Blood samples were obtained weekly from the jugular vein; all were analyzed for cholesterol and some for triglycerides. Both analyses were run on a Technicon Auto-Analyzer<sup>2</sup>, cholesterol as suggested by Technicon (1965) and triglycerides by the method of Kessler and Lederer (1966) as modified by Ewan<sup>3</sup>, i.e., silicic acid was used in lieu of zeolite. Total cholesterol in liver extracts was also determined; preparation of liver extracts for analysis has been described previously (Wiggers, Jacobson and Getty, 1971).

---

<sup>2</sup> Technicon Instruments Corp., Chauncey, New York.

<sup>3</sup> Ewan, R. C., Department of Animal Science, Iowa State University, Ames, Iowa. Private Communication. 1969.

Plasma magnesium levels were determined by use of an atomic absorption spectrophotometer<sup>4</sup>; 0.5 ml of plasma was diluted to 50 ml with 1% certified lanthanum chloride<sup>5</sup> solution. Magnesium standards made with  $\text{MgCL}_2 \cdot 6\text{H}_2\text{O}$  were compared to Lab-Trol<sup>6</sup> standards.

To approximate cholesterol digestibilities, fecal excretion of cholesterol was determined over a 6-day period when each experimental calf was 4-1/2 to 6 months of age. Total fecal cholesterol was also determined on four control calves, two fed the grain diet and two fed milk only, to detect the amount of endogenous cholesterol excreted. Noller et al. (1956) described a method for total fecal collection in very young calves; a similar method with modifications suitable to the larger calves was used in the present study. Large plastic "turkey" bags, cellulose tape, baling twine, 4-inch webbing and either branding cement<sup>7</sup> or formica glue<sup>8</sup> were used to make the fecal collection bag and to hold it in place. The hair was clipped from the area back of the hip bones and posterior to the prepuce. The adhesive was applied to the calf and webbing; after allowing the adhesive to "set" the webbing

---

<sup>4</sup> Techtron Atomic Absorption Spectrophotometer. Cary Instruments, Monrovia, California 91016.

<sup>5</sup> Fisher Scientific Company, Chemical Manufacturing Division, Fair Lawn, New Jersey.

<sup>6</sup> Dade Division, American Hospital Supply Corporation, Miami, Florida 33152.

<sup>7</sup> Victor Business Forms Co., Lincoln, Nebraska.

<sup>8</sup> Formica No. 140. Cyanamide Products, 4614 Spring Grove Ave., Cincinnati, Ohio 45232.



was affixed to the calf so that an open space was left in the middle of the webbing allowing for a place to tie the baling twine and bag. Figures 3.1 and 3.2 show the design of the collection bag and its appearance on a calf. The fecal collection bags were put on the calves several days before the actual collection so that they would become accustomed to the bags. The fecal collection bags were either emptied or replaced three times per day; feces collected were refrigerated. The total 6-day fecal collection was pooled and mixed before a sample was withdrawn for cholesterol analysis. The fecal samples were lyophilized and cholesterol was extracted in the same manner described for cholesterol extraction from liver (Wiggers, Jacobson and Getty, 1971). The fecal cholesterol analyses on the experimental calves include endogenous and exogenous sources of cholesterol. The values reported for the experimental calves represent exogenous cholesterol, i.e., the endogenous cholesterol values determined on the control calves were subtracted from the total fecal cholesterol found in the experimental calves.



An in vitro incubation of  $^{14}\text{C}$ -cholesterol<sup>9</sup> and rumen fluid was conducted to determine the amount, if any, of microbial degradation of cholesterol. Rumen fluid was aspirated by a tube introduced into the ruminoreticulum via the mouth and esophagus of a 3-month-old ruminating Holstein calf. The rumen fluid was strained through cheese cloth and

---

<sup>9</sup> Cholesterol-4- $^{14}\text{C}$ . Amersham/Searle Corp., 2636 S. Clearbrook Drive, Arlington Heights, Illinois.

Figure 3.1. Plastic fecal collection bag.

Figure 3.2. Plastic fecal collection bag on a calf; the squares in background are 6-inches to a side.



100 ml of fluid was put into a 250 ml Erlenmeyer flask immersed in a 37°C water bath. Ten  $\mu$ Ci of  $^{14}$ C-cholesterol dissolved in 95% ethanol and 70 mg of cold cholesterol were added to the incubation mixture at zero time and mixed very thoroughly. This level of cold cholesterol added to the 100 ml rumen fluid approximates the concentration of cholesterol in the incubation mixture with the concentration estimated in the rumen of Group III calves. The gaseous space above the rumen fluid in the flask was flooded with nitrogen gas to maintain anaerobic conditions. The flask, equipped with a rubber stopper containing a glass-wool-filled glass tube, was suspended from a wrist-action shaker<sup>10</sup> and shaken gently in the 37°C water.

At 0, 0.5, 1, 2, 3, 4, 5 and 6 hours, the incubation mixture was mixed thoroughly and a 10 ml sample withdrawn. After each sampling, the flask was flooded with nitrogen gas and replaced in the continuous-action shaker. Fifty ml of 2:1 chloroform-methanol was added to the 10 ml sample immediately; the sample was homogenized<sup>11</sup> and then centrifuged at ca. 8000 x gravity. The aqueous and organic layers were decanted and filtered through glass wool into a separatory funnel. The organic layer (lower layer) was drawn off into a 125 ml Erlenmeyer flask and evaporated to less than 10 ml in a vacuum desiccator. This lipid extract was brought up to volume in a 10 ml volumetric flask with chloroform-methanol; a portion of these extracts was spotted on thin-layer chromatographic plates.

---

<sup>10</sup> Burrell Corp., Pittsburg, Pennsylvania.

<sup>11</sup> Virtis "45". Virtis Research Equipment. Gardiner, New York.

Cholesterol and other lipids were separated by thin layer chromatography (TLC) with chloroform-cyclohexane-ethyl acetate (20:30:50) as a solvent on 0.5 mm silica-gel G<sup>12</sup> plates. An X-ray film<sup>13</sup> was placed over the thin-layer chromatogram and exposed for 3 days; this procedure showed the sites of radioactivity on the thin-layer plate. Correspondence was made between the exposed film and the chromatogram; each band of radioactivity was scraped off the chromatogram and eluted into separate scintillation vials with 18 ml of 10% ethyl acetate in Skelly B and secondarily eluted with 18 ml 2:1 chloroform-methanol. These thin-layer extracts were evaporated to dryness in a high velocity exhaust hood. Ten ml of scintillation fluid<sup>14</sup> were added to the extracts; counting was done in a liquid scintillation spectrometer<sup>15</sup>.

At 6 or 9 months each calf was slaughtered; the heart, aorta and liver were removed. The heart and aorta were fixed in 10% neutral buffered formalin. Lipid in the endocardium and aorta was determined grossly by staining with Sudan IV (Holman et al., 1958b). A segment from the circumflex coronary artery immediately preceding the juncture with the left descending coronary and a segment of the left descending coronary adjacent to this junction were removed from the

---

<sup>12</sup> EM Reagents Division. Brinkman Instruments, Inc., Westbury, New York 11590.

<sup>13</sup> Kodak RP/L-14 Medical X-Ray Film. Eastman Kodak Co., Rochester, New York.

<sup>14</sup> PPO (0.3%) and POPOP (0.01%) in toluene.

<sup>15</sup> Packard Tri-Carb Liquid Scintillation Spectrometer. Packard Instrument Company, Inc., 2200 Warrenville Rd., Downers Grove, Illinois.

heart and examined by light microscopy after routine staining. Blocks from the aorta were taken from fatty streaks, lesions and grossly "normal" areas for examination similar to that done for the coronary arteries. Oil-Red-O staining for lipids was done by the method of Zugibe, Fink and Brown (1959). Schultz's cholesterol stain, hematoxylin and eosin stains and Von Kossa calcium stain were conducted as outlined by Armed Forces Institute of Pathology (1968). Collagen and acid mucopolysaccharides (AMPS) were stained by the method of Lison (1954) as modified by Zugibe, Brown and Last (1959), i.e., alcian blue was mixed with hydrochloric acid rather than acetic acid.

#### Results and Discussion

Plasma cholesterol levels (Figure 3.3) for the Group I calves and Group III calves were quite similar to levels found in calves fed the same diets in an earlier experiment (see Section II). Feeding cholesterol via one kilogram milk to milk-grain calves (Group II) did not raise plasma cholesterol levels substantially above those of calves fed cholesterol in the grain (Group III); however, plasma cholesterol levels did decline more gradually and eventually plateaued near those of the Group III calves. The analysis of variance (ANOV) in Table 3.3 shows that the treatment differences, calf-within-treatment differences, week differences and treatment by week interaction were significant at the 1% level. The animal-within-treatment differences show the animal variability in response to treatment. The week effect shows that regardless of treatment, plasma cholesterol levels changed over time. The treatment by week interaction in the Group II and III calves is in part

Figure 3.3. Plasma cholesterol levels. Cholesterol was fed as indicated on the graph. Concurrent with the cessation of cholesterol feeding, all calves were switched to a diet of grain-only.

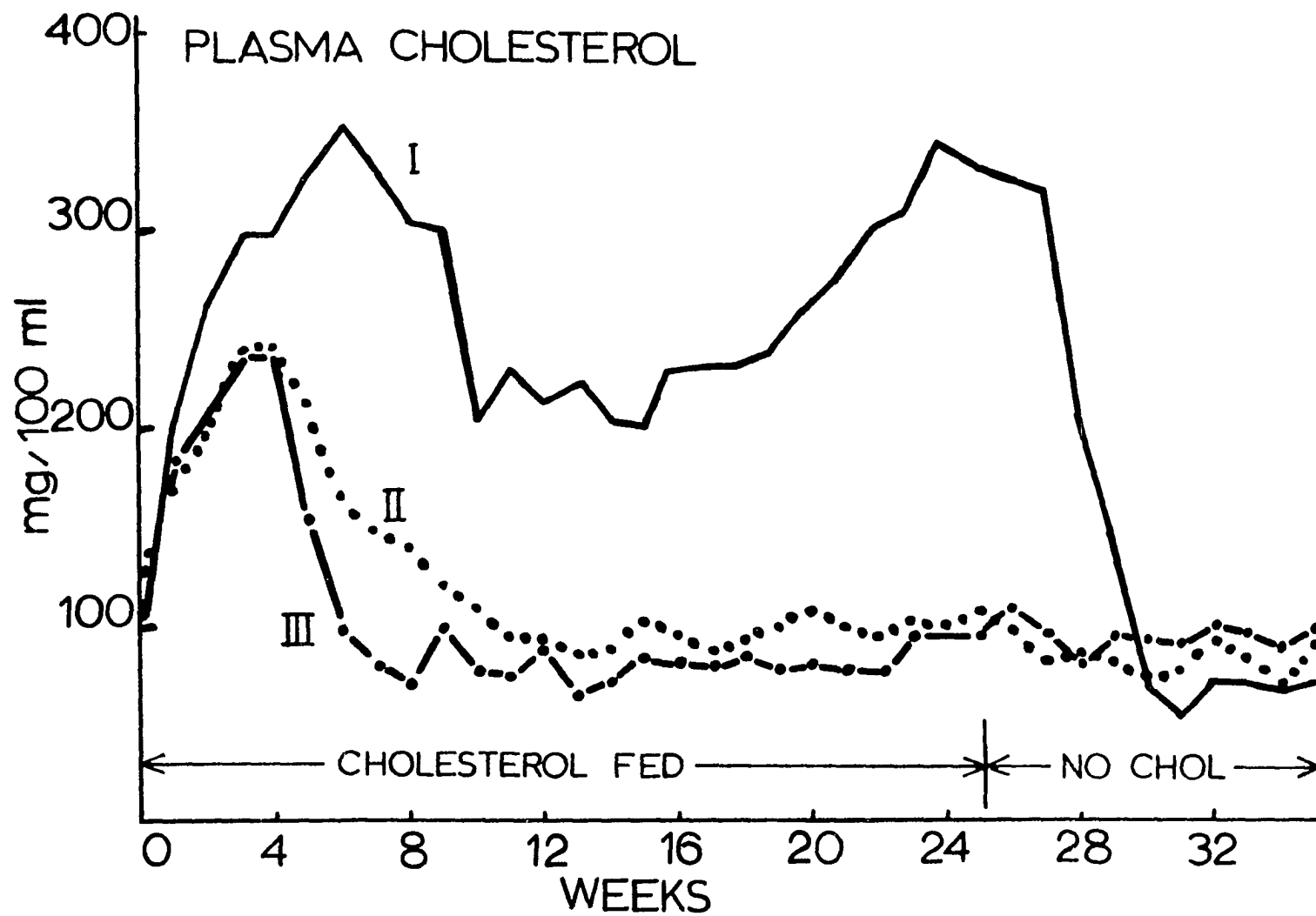




Table 3.3. Analysis of variance of plasma cholesterol during cholesterol feeding

Source of variation	d.f.	Mean squares	"F"
Trt.	2	761,814	16.1 <sup>**</sup>
Animal/Trt.	9	47,240	12.2 <sup>**</sup>
Week	24	20,640	5.3 <sup>**</sup>
Trt. x week	48	8,575	2.2 <sup>**</sup>
Error	216	3,858	

<sup>\*\*</sup> p < 0.01.

Table 3.4. Analysis of variance of plasma cholesterol subsequent to cholesterol feeding

Source of variation	d.f.	Mean squares	"F"
Trt.	2	133,213	15.4 N.S. <sup>a</sup>
Animal/Trt.	3	8,660	5.5 <sup>**</sup>
Week	13	34,458	21.8 <sup>**</sup>
Trt. x week	23	23,299	14.8 <sup>**</sup>
Error	36	1,575	

<sup>a</sup> Nonsignificant, p > 0.05.

<sup>\*\*</sup> p < 0.01.

due to the lower fat intake that occurs at 4 weeks (Table 3.2). No explanation can be given for the treatment by week interaction of the Group I calves.

Table 3.4 shows the ANOV for the 6 calves maintained on experiment and switched to a grain-only diet. Treatment differences are shown to be nonsignificant ( $p > 0.05$ ), i.e., there are no important overall after-effects of the preceding treatment. However, the treatment by week interaction (Table 3.4) does reflect a temporary aftereffect of treatment in the Group I calves.

Considering that the plasma cholesterol levels shown for Group II and III calves in Figure 3.3 are quite similar and with the knowledge as to how they were fed cholesterol, it might be concluded that rumino-reticulo-microbial degradation of cholesterol did not contribute substantially to the different plasma cholesterol levels observed in Group I calves versus Group III calves. Examination of the fecal cholesterol data from a cholesterol digestibility study shown in Table 3.5, however, suggests a substantial loss and presumably degradation of cholesterol fed to Group III calves. These values have been corrected for endogenous cholesterol based on fecal cholesterol excreted daily by two calves fed milk-only (ca. 1 g/day) and by two calves fed grain-only (ca. 2 g/day). The ANOV (Table 3.6) shows the differences in fecal cholesterol levels (or digestibilities) due to treatment to be significant at the 5% level. Calves of Groups II and III had essentially the same plasma cholesterol levels yet there were marked differences in fecal cholesterol (103 and 50%, respectively, of dietary cholesterol).

Table 3.5. Fecal cholesterol

Group	Fecal cholesterol as % of dietary cholesterol
I	79
II	103
III	50

Table 3.6. Analysis of variance of fecal cholesterol determinations

Source of variation	d.f.	Mean squares	"F"
Trt.	2	2,763	7.65*
Error	9	361	

\*  $p < 0.05$ .

Table 3.7. Liver weights (kg) and liver cholesterol expressed as percent dry matter

Group	% cholesterol	weight (kg)
I a) 6 mo.	2.4	3.65
b) 9 mo.	0.9	5.19
II a) 6 mo.	1.1	3.70
b) 9 mo.	0.8	4.62
III a) 6 mo.	1.2	3.99
b) 9 mo.	0.9	5.24

This indicates that some of the cholesterol subjected to the microbes of the ruminoreticulum (Group III) was degraded; cholesterol fed to the Group II calves bypassed ruminoreticulum degradation.

Results of the digestion studies are supported by the in vitro incubation of  $^{14}\text{C}$ -cholesterol and rumen fluid, which showed cholesterol to be degraded into four and probably five compounds (the solvent for the thin-layer chromatograms did not separate cholesterol from cholestanol). Inasmuch as microorganisms in the cecum of humans and other animals degrade cholesterol to cholestanol, it is likely that this degradation also occurs in the ruminoreticulum; if so, cholesterol would be degraded into five compounds.

The cholesterol digestibility study and the in vitro incubation of  $^{14}\text{C}$ -cholesterol-rumen fluid study answer in part why plasma cholesterol levels of the Group III calves are low when compared to those of the Group I calves. However, plasma cholesterol levels of the Group II calves are also low; this cannot be explained by degradation of cholesterol. Table 3.2 shows the amount of fat and cholesterol consumed and the cholesterol-to-fat percent; the data strongly suggest that the amount of fat in the diet is the principal factor responsible for the differences observed in cholesterol uptake. Studies have shown that cholesterol is much more effectively absorbed by the gut when fed in the presence of fat (Connor, Rohwedder and Armstrong, 1967; Cook, 1936; Fraser and Courtice, 1969; and Wilkens, De Wit and Bronte-Stewart, 1962). In rats and humans, Wilkens, De Wit and Bronte-Stewart (1962) noted that cholesterol fed at above a level of 4-6% of the dietary fat did not

cause a further rise in serum cholesterol; the dietary cholesterol of the Group I calves was very near this percentage. Further clarification could be provided by an experiment in which a diet similar to that of Group II is used; however, the fat should be adjusted to a level equal to that in the diet of the Group I calves.

Plasma triglyceride levels of all calves were determined for the first 16 weeks (Figure 3.4). The plasma triglyceride levels of the Group I calves were generally above those of Group II and III calves.

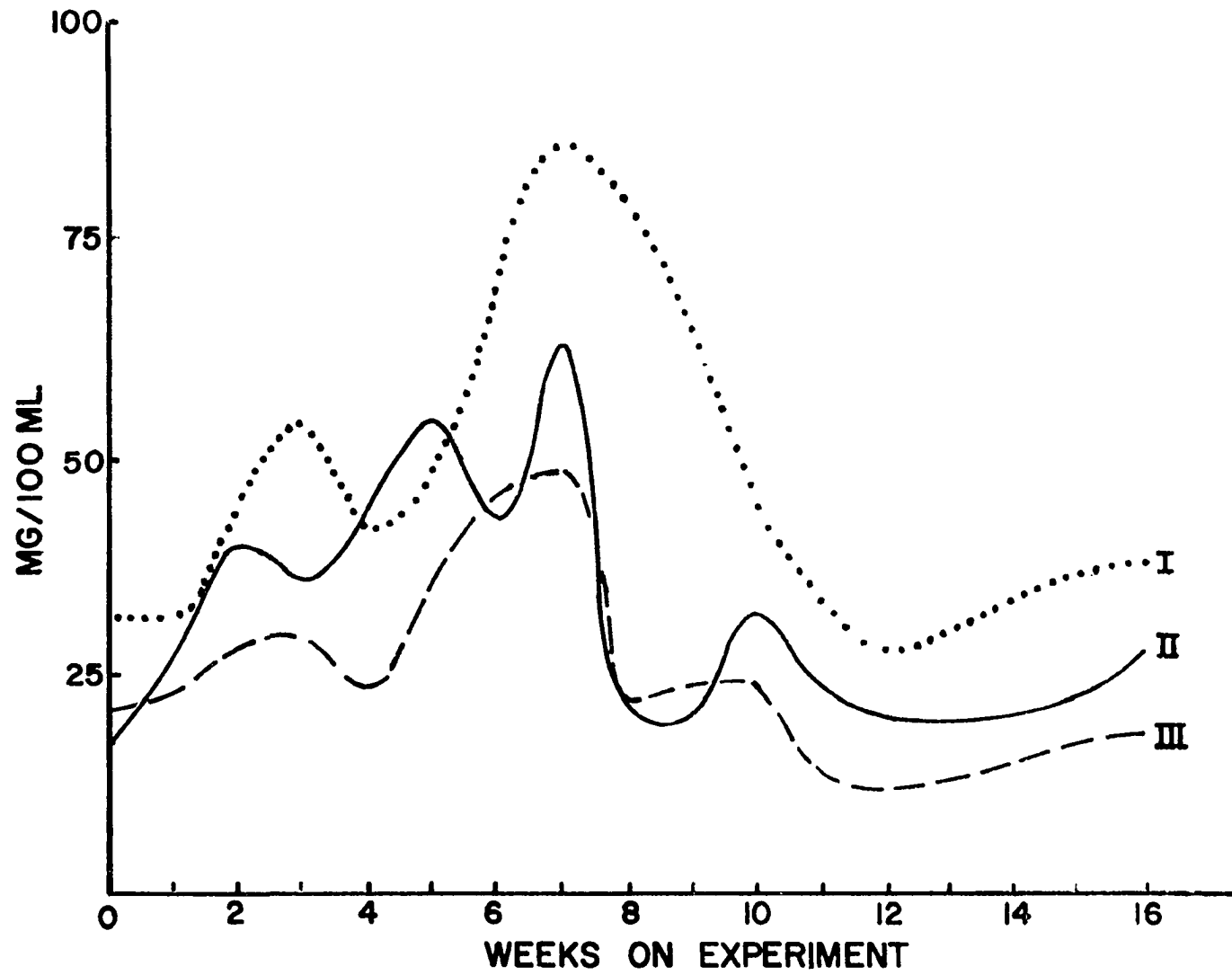
Liver weights and liver cholesterol are presented in Table 3.7. The percent liver cholesterol in the different groups is in accord with previous observations<sup>16</sup> where it has been shown that calves fed milk and cholesterol store more cholesterol in the liver than calves fed essentially grain with or without cholesterol. The liver cholesterol values for Group I, II and III calves at 9 months, after 3 months of grain only, (0.9, 0.8 and 0.9% respectively) are comparable to those found by Wiggers, Jacobson and Getty (1971) in calves fed grain (0.86%) and in goats fed a ruminant diet (0.87%).

A deficiency of magnesium has been suggested as a factor contributing to atherogenesis. Moore, Hallman and Sholl (1938) and Vitale et al. (1961) found calves and puppies, respectively, with hypomagnesemia, to have aortic calcium deposition. Magnesium-deficient monkeys showed marked aortic sudanophilia whereas the controls showed very little sudanophilia (Vitale et al., 1963). Feeding a magnesium-deficient diet

---

<sup>16</sup> Wiggers, K. D. Department of Animal Science, Iowa State University, Ames, Iowa. Unpublished data. 1971.

Figure 3.4. Plasma triglyceride levels.



to rabbits significantly enhanced aortic lipid deposition (Nakamura et al., 1965), but a high magnesium diet did not reduce lipid deposition over that observed in animals on a normal magnesium diet. Duncan, Huffman and Robinson (1935) found that calves fed whole milk exhibited signs of magnesium deficiency, i.e., irritability, nervousness, anorexia and eventually tetany. Breirem (1961) found hypomagnesemia in calves fed dried skimmilk supplemented with hydrogenated whale oil and coconut fat; however, hypomagnesemia was not observed when these fats were replaced with butterfat. Milk supplies adequate magnesium for the young calf in which absorption is efficient but becomes inadequate because net absorption efficiency decreases as the age of the calf increases (Smith, 1964). In the present study, magnesium values were determined on all weekly blood samples (Figure 3.5). The ANOV of plasma magnesium during cholesterol feeding and subsequent to cholesterol feeding is shown in Table 3.8 and 3.9. The treatment differences are significant at the 1% level (Table 3.8); this reflects the substantially lower magnesium values of the Group I calves, although they are not considered to be seriously hypomagnesemic. Subsequent to cholesterol feeding, two calves in each group were maintained on grain only; during this period of time plasma magnesium rose sharply (Figure 3.5) and treatment differences (Table 3.9) were nonsignificant ( $p > 0.05$ ). These calves did not show any of the signs of magnesium deficiency described by Duncan, Huffman and Robinson (1935). The plasma magnesium levels rose promptly in the Group I calves when they were switched from the milk-cholesterol diet to the grain diet.



Figure 3.5. Plasma magnesium levels. Cholesterol was fed as indicated on the graph. Concurrent with the cessation of cholesterol feeding, all calves were switched to a diet of grain-only.

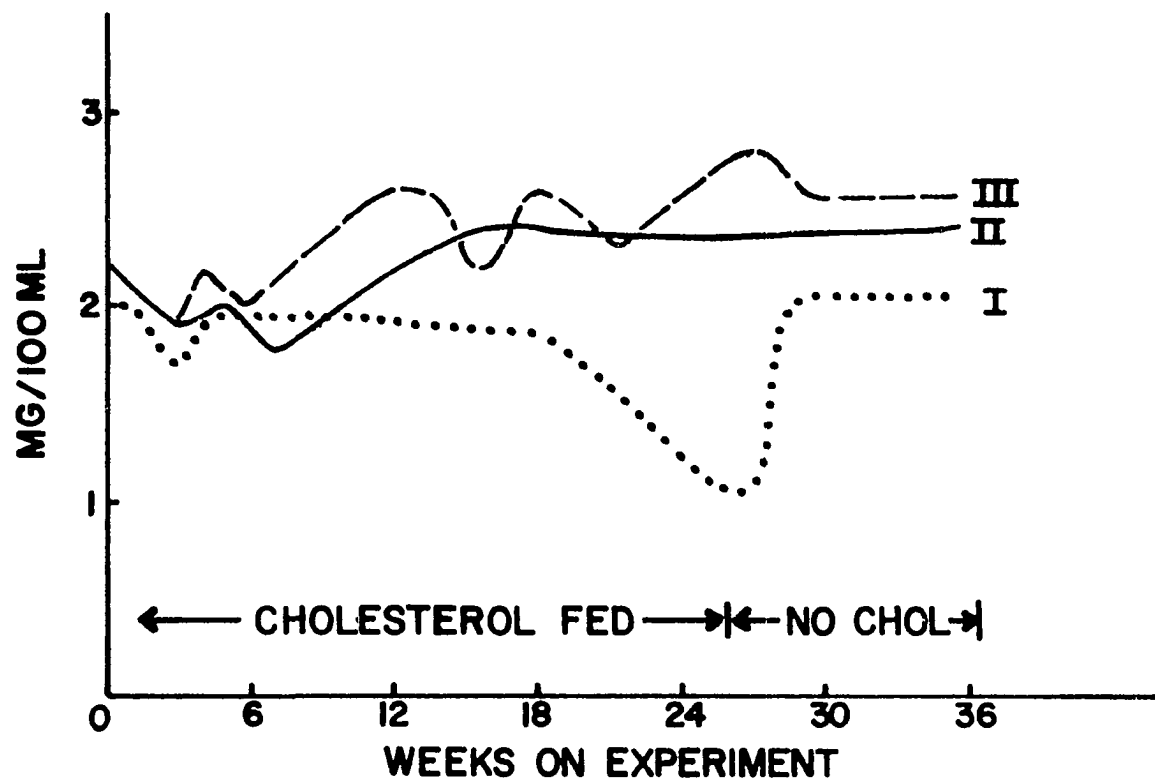


Table 3.8. Analysis of variance of plasma magnesium during cholesterol feeding

Source of variation	d.f.	Mean squares	"F"
Trt.	2	6.83	8.5 <sup>**</sup>
Animal/Trt.	9	0.80	20.5 <sup>**</sup>
Week	24	0.12	3.1 <sup>**</sup>
Trt. x week	48	0.15	4.0 <sup>**</sup>
Error	212	0.04	

<sup>\*\*</sup>  $p < 0.01$ .

Table 3.9. Analysis of variance of plasma magnesium subsequent to cholesterol feeding

Source of variation	d.f.	Mean squares	"F"
Trt.	2	5.16	5.16 N.S. <sup>a</sup>
Animal/Trt.	3	1.00	9.43 <sup>**</sup>
Week	13	0.16	1.47 <sup>a</sup>
Trt. x week	22	0.18	1.75 <sup>a</sup>
Error	33	0.11	

<sup>a</sup> Nonsignificant,  $p > 0.05$ .

<sup>\*\*</sup>  $p < 0.01$ .

All calves had focal sudanophilia on the papillary muscle at the base of the chordae tendinae (Figure 3.6). There was not a detectable difference between groups in this respect. Three of the Group I calves had ca. 95% sudanophilia in the abdominal aorta; one of the three had ca. 10% and the other two ca. 90% sudanophilia in the thoracic aorta. All observations made on the fourth Group I calf were more similar to those of Group III calves; this calf had plasma cholesterol levels and fecal cholesterols similar to those of Group III calves. Aortic sudanophilia, ca. 15%, all localized about the exit of the renal artery, corroborates differences observed in plasma cholesterol levels and fecal cholesterol. One might suspect the "esophageal groove reflex" was not functioning and thus allowed the milk-cholesterol to pass into the rumenoreticulum. However, the physical characteristics of the rumenoreticulum (very thin-walled with lack of papillary development) did not appear to be different from those of the other Group I calves. Thus, there are marked differences in response even among animals on the same diet. Sudanophilia was virtually absent in aortas from Group II and III calves; one Group II calf abdominal aorta stained positive near some of the ostia.


Light microscopic observations of Oil-Red-O stained sections revealed lipid in the intima and media of the circumflex coronary arteries of three Group I calves, one Group II calf and one Group III calf. The lipid in the circumflex coronary arteries of the Group I calves was present in the intima and media (Figures 3.7 and 3.8); the lipid was both diffuse and perifibrous. In the Group II calf and the Group III calf,

Figure 3.6. Heart from Group I calf showing focal sudanophilia on the papillary muscle at the base of the chordae tendinae (arrow).



Figure 3.7. Cross-section of circumflex coronary artery from a Group I calf showing lipid deposition in the intima and media. Oil-Red-O + Mayer's Hematoxylin. Line scale = 100  $\mu$ .

Figure 3.8. Cross-section of circumflex coronary artery from a Group I calf showing the perifibrous lipid in the media. Oil-Red-O + Mayer's Hematoxylin. Line scale = 50  $\mu$ .





lipid deposition was very slight and was in conjunction with the elastic lamina.

The circumflex coronary arteries of all calves had at least one area where the overall thickness of the vessel was increased to a greater though variable amount (Figures 3.9 and 3.10); this increased vessel thickness was always accompanied by the apparent degeneration of the media shown in Figures 3.11, 3.12, and 3.13. These medial cells (Figure 3.11) are foam cell-like but did not always contain lipid. These cells have the same morphological characteristics as the medial cells described in the aortic media of MC calves in the preceding section. Figure 3.12 shows the deposition of collagen along the elastic fibers of the media (the red-stained collagen shows as a dark strip adjacent to the clear elastic fiber); it was quite common to find collagen along the elastic fibers with AMPS in the matrix between the fibers. The red-stained collagen was usually found in the intima (Figure 3.13) adjacent to areas of medial degeneration; this is in contrast to the blue-stained AMPS occasionally found in the intima (Figure 3.12, same section as Figure 3.13). All circumflex coronary arteries were negative to Von Kossa calcium stain.

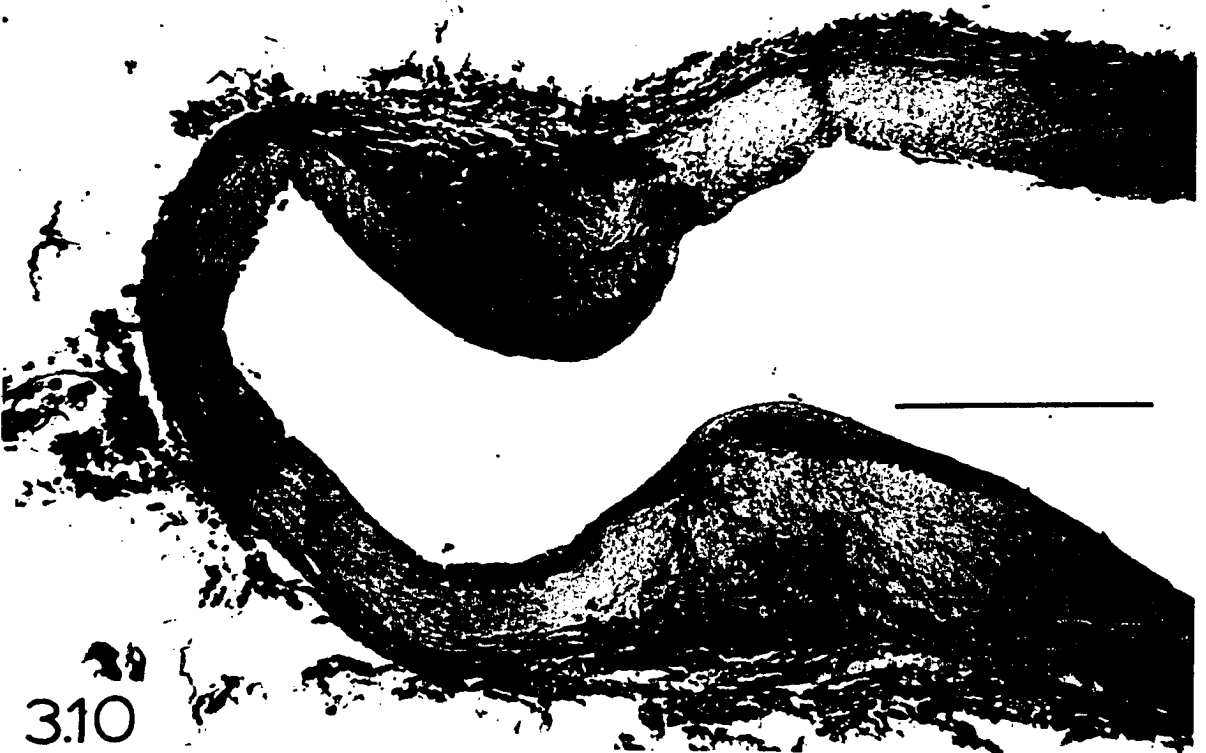
The left descending coronary arteries of most calves were "normal" as shown in Figure 3.14; however, several calves in each group did have some intimal thickening and medial cells similar to those of the circumflex coronary shown in Figure 3.11. No lipid or calcium deposition was noted in any of the left descending coronaries.

Figure 3.9. Cross-section of circumflex coronary artery of Group I calf showing plaques in the vessel wall. Hematoxylin + Eosin. Line scale = 1000  $\mu$ .

Figure 3.10. Cross-section of circumflex coronary artery of Group I calf showing plaques in the vessel wall. Hematoxylin + Eosin. Line scale = 1000  $\mu$ .



3.9



3.10

Figure 3.11. Cross-section of circumflex coronary artery showing medial degeneration. Hematoxylin + Eosin. Line scale = 100  $\mu$ .

Figure 3.12. Cross-section of circumflex coronary artery showing deposition of collagen along the elastic fibers of the media (the red-stained collagen shows as a dark strip adjacent to the clear elastic fibers). Blue-stained acid mucopolysaccharides are present in the intima (shows dark in print). Chlorantin Fast Red + Alcian Blue + Mayer's Hematoxylin. Line scale = 100  $\mu$ .




Figure 3.13. Cross-section of circumflex coronary artery showing red-stained collagen (dark in print) in the intima. Chlorantin Fast Red + Alcian Blue + Mayer's Hematoxylin. Line scale = 200  $\mu$ .

Figure 3.14. Cross-section of left descending coronary artery. Hematoxylin + Eosin. Line scale = 200  $\mu$ .




Figure 3.15. Cross-section taken from thoracic aorta of Group I calf showing intimal lipid. Oil-Red-O + Mayer's Hematoxylin. Line scale = 200  $\mu$ .

Figure 3.16. Cross-section taken from abdominal aorta of Group I calf showing intimal cholesterol deposition. Schultz cholesterol stain. Line scale = 50  $\mu$ .







Figure 3.17. Cross-section taken from abdominal aorta of Group II calf. Various cell-types are present in the thickened intima. Hematoxylin + Eosin. Line scale = 100  $\mu$ .

Figure 3.18. Cross-section taken from abdominal aorta of Group I calf. Disruptions in the internal elastic lamina are evident. Various cell-types are present in the thickened intima. Hematoxylin + Eosin. Line scale = 100  $\mu$ .



Aortic lipid deposition was confined to the intima (Figure 3.15); Schultz's cholesterol stain showed cholesterol to be coextensive with the intimal lipid (Figure 3.16). The aortic intimal lipid was always found in conjunction with the aortic sudanophilia. Calcium deposition was noted in the inguinal region of the abdominal aorta of one Group I calf and one Group II calf; the calcium was deposited in conjunction with the internal elastic lamina.

Aortic intimal thickening (Figure 3.17) was present in all calves, although the degree of thickening was more extensive in the Group I calves. There were more disruptions (Figure 3.18) in the internal elastic lamina of aortas from Group I calves; generally associated with these disruptions was a radial orientation of smooth muscle cell (SMC) nuclei. The cell-types observed in the intimae of Figures 3.17 and 3.18 were discussed in the preceding section.

All calves had collagen deposition in the thickened intima; the greater the intimal thickening, the greater the amount of collagen deposition. Acid mucopolysaccharides were noted in the aortic media of all calves; AMPS were most heavily concentrated along the elastic fibers. This was sometimes accompanied by more diffuse AMPS in the matrix between elastic fibers. No trends could be discerned in regard to collagen or AMPS deposition.

#### Summary

Varying degrees of atherosclerosis were noted in the aortas and coronary arteries of calves from all treatments; the most extensive atherosclerotic involvement occurred in the Group I calves. The aortas

from the Group I calves had much intimal lipid whereas aortic intimal lipid was virtually absent in Group II and III calves; cholesterol was found to be coextensive with the intimal lipid. The Group I calves slaughtered at 9 months (after 3 months of grain feeding) did not show a reduction in aortic sudanophilia. Lipid was more prevalent in the circumflex coronary arteries of the Group I calves than in the other calves. The circumflex coronary arteries from all calves had at least one area of vessel-wall thickening; the media in this area was degenerated. In two instances, both in Group I calves, large plaques were found in the circumflex coronary artery. No histological differences were noted within groups in regards to time of slaughter, i.e., 6 months or at 9 months.

Plasma cholesterol levels were quite responsive to milk-cholesterol feeding in the Group I calves. It has been determined that rumino-reticulo degradation of dietary cholesterol does occur and that this may in part play a role in limiting the amount of dietary cholesterol that reaches the lower digestive tract for absorption. It has been strongly suggested that the low amount of fat in the diet of the Group II and III calves is a restricting factor in the absorption of cholesterol levels and the increased aortic and coronary artery lipid in Group I calves is a relationship of cause and effect.

## SECTION IV - MISCELLANEOUS OBSERVATIONS

This section includes observations made on various ruminants while studies reported in the previous sections were in progress.

## Materials and Methods

Goats

The livers, hearts, aortas and some fetuses were removed from 16 mature goats (15 females and one male). The hearts and aortas from the mature goats and fetal goats were processed as described in Sections I, II and III. Liver cholesterol as percent dry matter was determined in a manner similar to that described in Section I with the following modifications: (1) the extract was made up to 100 ml or 200 ml volume (depending on cholesterol concentration) rather than to 10 milliliters, and (2) a portion of the 100 ml or 200 ml volume was analyzed directly for cholesterol in the Auto-Analyzer rather than by preparation of an extract of the 10 ml extract as described previously.

Mature Cows

Hearts, aortas and livers were removed from eight cows slaughtered at the Iowa State University Meat Laboratory; these tissues were examined by the same methods used for the goat tissues.

### Calves

Two male Holstein calves were fed reconstituted skim milk<sup>1</sup> (SM) plus 250 mg cholesterol per kg body weight. The diets were supplemented with chlortetracycline, vitamin A, vitamin D<sub>2</sub> and trace minerals.<sup>2</sup> Jugular blood was sampled weekly; plasma cholesterol levels were determined as described in Sections I, II and III. After determining that plasma cholesterol levels remained low during SM-cholesterol feeding, corn oil and tallow were added to the respective diets to make the fat content of the reconstituted skim milk equivalent to 3.5%. Plasma magnesium levels were determined on all samples in the same manner described in Section III.

## Results and Discussion

### Goats

Aortas from ten goats were negative to Sudan IV stain; aortas from the other six goats showed very slight sudanophilia in the inguinal portion of the aorta. The aorta from one nanny (ca. 1.5 years of age) was very brittle; the intimal surface was covered with white plaques (Figures 4.1 and 4.2). These white plaques were negative to Sudan IV staining; histological examination of these plaques after staining with Von Kossa calcium stain and Chlorantin Fast Red collagen stain showed

---

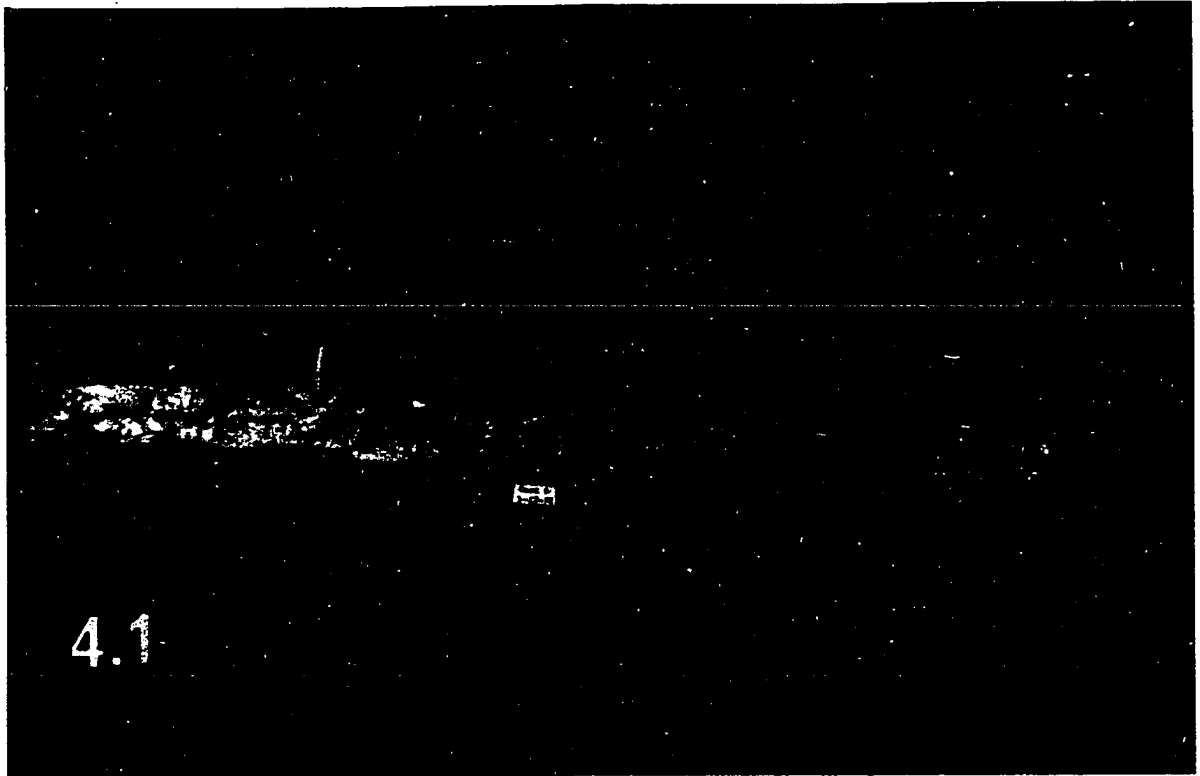
<sup>1</sup> One part dried skim milk to nine parts water.

<sup>2</sup> Each calf received a daily supplement of 50 mg chlortetracycline, 10,000 I.U. vitamin A, 1,000 I.U. vitamin D<sub>2</sub> and 2.4 g of trace mineral mix composed of, in %: MnSO<sub>4</sub>, 12.5; FeSO<sub>4</sub>, 5.0; FeCO<sub>3</sub>, 10; CuSO<sub>4</sub>, 2.0; CoCO<sub>3</sub>, 1.5; ZnO, 4.0; CaIO<sub>3</sub>, 0.2; and CaCO<sub>3</sub>, 64.5.

Figure 4.1. Full-length view of an aorta from a 1.5 year old goat.  
The aorta was very brittle and covered with white plaques.

Figure 4.2. Close-up view of aorta shown in Figure 4.1; white plaques  
are quite apparent.





the plaques to contain massive calcium deposits and to be devoid of collagen. This nanny was in apparent poor health; she was at times heavily infested with external parasites. The average liver cholesterol for these goats expressed on a dry matter basis was 3.0%.

The fetal goat aortas were of special interest in that they exhibited what has been defined by some as "normal" arteries, i.e., the intima consisted of the endothelial layer (Figures 4.3 and 4.4). It seems that the endothelium is held in place by "foot processes" extending into involutions of the media (Figure 4.4). When sections of the aortas of the fetal goats were stained with Oil-Red-O, no lipid could be detected in the intima or media.

#### Cows

The aortas from the mature cows were essentially absent of sudanophilia. Rough raised ridges were common in the lower abdominal aorta; sections taken from these areas showed this to consist of massive calcium deposits in the media (Figure 4.5). There was an increase in collagen and acid mucopolysaccharides (AMPS) about the calcium deposition in most cases. There were varying degrees of collagen and AMPS deposited in the intima and media. Histological examination of Oil-Red-O stained tissue taken from the areas of the aortas that did stain positive for lipids with Sudan IV showed the lipid to be confined to the intima. Intimal thickening occurred in aortas of all cows. The vasa vasorum was very extensive in the greatly thickened thoracic aorta of these cows.

Very fine granular calcium deposition was noted in the coronary arteries of three of eight cows examined. This same type of fine

Figure 4.3. Cross-section of fetal goat aorta. Hematoxylin + Eosin.  
Line scale = 50  $\mu$ .

Figure 4.4. Higher magnification of fetal goat aorta shown in Figure 4.3. The endothelium (E) is evident. Foot-processes extending may play a role in attachment of endothelium to internal elastic lamina. Hematoxylin + Eosin. Line scale = 50  $\mu$ .




Figure 4.5. Cross-section taken from lower abdominal aorta of mature cow. Large massive calcium deposits are evident. Von Kossa. Line scale = 1000  $\mu$ .

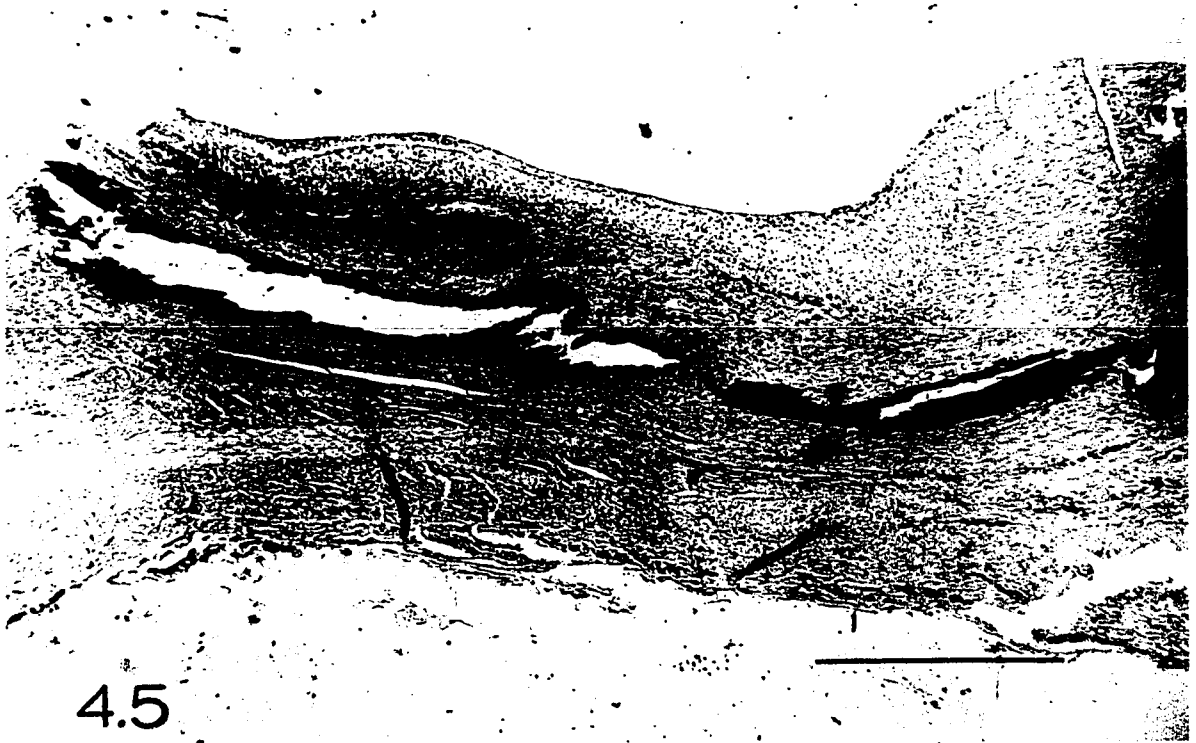

Figure 4.6. Plasma cholesterol levels of calves fed reconstituted skimmilk plus cholesterol without supplemental fat and at a later time with supplemental fat.

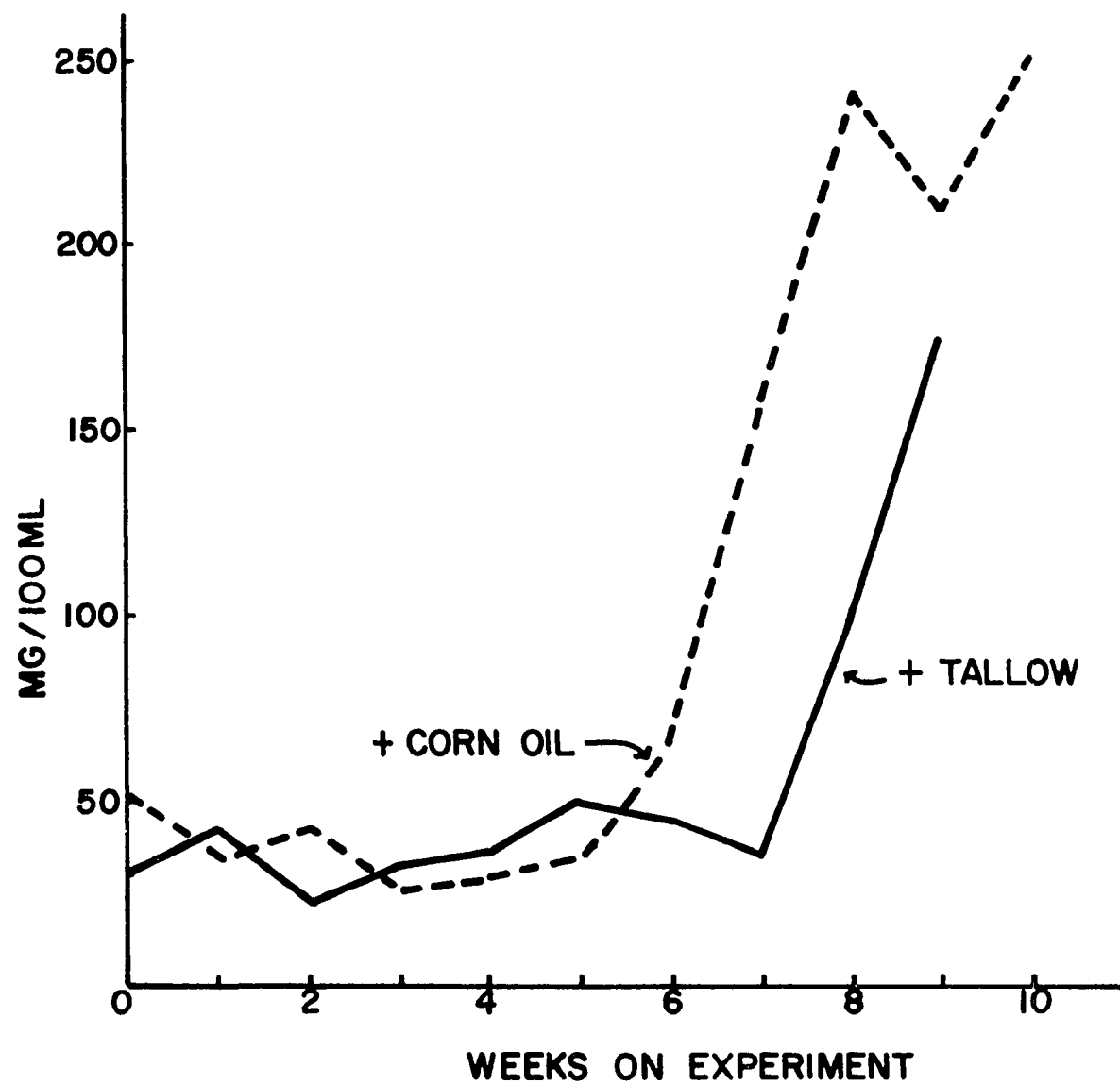
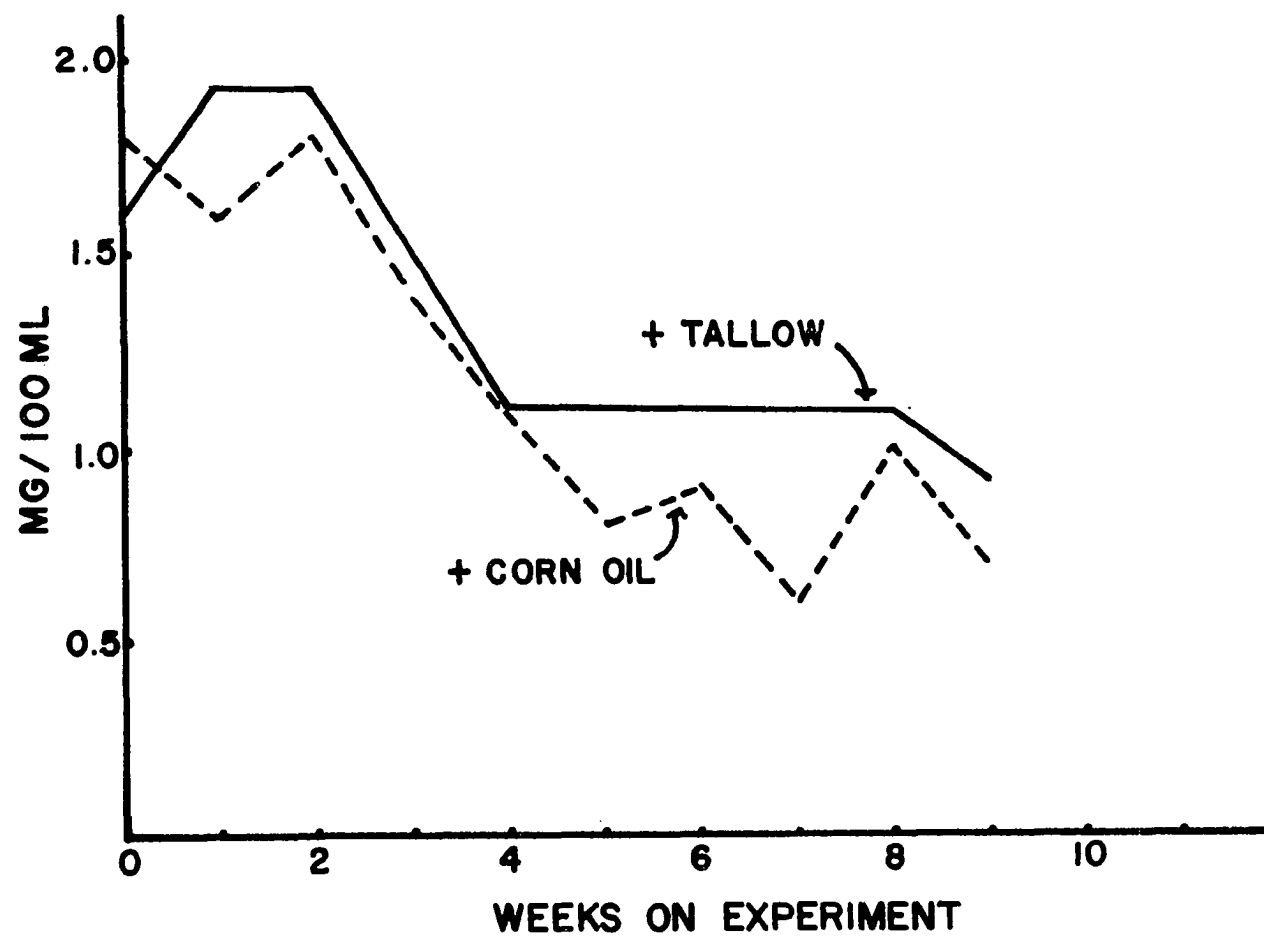




Figure 4.7. Plasma magnesium levels of calves fed reconstituted  
skimmilk plus cholesterol without supplemental fat and  
at a later time with supplemental fat.



granular calcium deposition has been described in the aortas of young calves (Sections I and II). The granular calcium deposition is probably the initial stage of the massive calcium deposits observed in the cow aortas.

Livers from these cows averaged 1.8% cholesterol (expressed on a dry-matter basis).

### Calves

Plasma cholesterol levels of the calves fed SM were very low until 3.5% corn oil and tallow respectively, were added to the SM formula (Figure 4.6). The plasma cholesterol levels increased quite substantially upon addition of the corn oil and tallow to the SM. When examining Figure 4.6, one must realize that the increase in plasma cholesterol is probably much more rapid than expressed; the corn oil and beef tallow were added to the diet only two days before sampling whereas the graph is plotted from values representing weekly samples. These limited observations of fat in the diet causing an apparent increase in cholesterol absorption corroborate the discussion in Section III concerning the relationship of cholesterol and fat in the diet. The calf fed the diet containing beef tallow died inexplicably. Plasma magnesium levels were low in both calves (Figure 4.7); no gross magnesium-deficiency symptoms were manifested.

### Summary

Ruminants examined did not manifest aortic atherosclerosis in the sense of extensive sudanophilic lipid deposition, although other vascular irregularities such as extensive calcium deposition and intimal collagen

were noted. Fetal goat aortas were found to be what may be classified as normal, i.e., the intima consisted of an endothelial layer immediately adjacent to the elastic lamina. Calves fed SM plus cholesterol had very low plasma cholesterol levels; plasma cholesterol levels increased very markedly upon addition of corn oil and beef tallow, respectively, to the SM formula.

## GENERAL DISCUSSION

This thesis project was initiated to study spontaneous (nonexperimental) and experimental atherosclerosis in various ruminants. Selection of ruminants was not prompted because of a high mortality rate from complications arising from atherosclerosis (as in man) but rather to learn more about the etiology and pathogenesis of the disease itself. The ultimate goal is that this information will provide a further insight into the understanding of the etiology of atherosclerosis in man.

Spontaneous aortic atherosclerotic lesions and other vascular degeneration have been observed in domestic cows, calves, sheep and goats and in wild deer, and caribou. The total aortic surface area affected by lipid deposition in spontaneous lesions is quite small and generally limited to the inguinal region and to the areas near the ostia of intercostal arteries. A limited granular calcium deposition without concurrent lipid deposition was also frequently found in aortas of young animals on a "normal" ruminant diet. In contrast, much of the abdominal aorta in the aged animals is rendered inelastic and even brittle in some cases by massive deposits of calcium. Judging from the previous observations, it does not seem that deposition of calcium is necessarily dependent on a previous lipid deposition.

It is quite likely that if these animals were allowed to live to die a "natural death", many would succumb to cardiovascular ailments as does man. When the purported relationship of atherosclerotic degeneration to fat and cholesterol intake is considered, the occurrence of vascular degeneration in domestic and wild ruminants is of special interest in

that they consume foods relatively low in fat and cholesterol, except of course, when nursing. Exercise may retard development of atherosclerosis but does not completely inhibit atherogenesis; for example, the nomadic caribou develops atherosclerosis.

In contrast to the preceding observations, very extensive aortic lipid deposition could be caused in calves by feeding them a diet of milk-only (by nipple) plus cholesterol in the milk. Aortic lipid deposition was limited in calves receiving milk-only and virtually absent in calves receiving grain-only and in calves receiving grain plus cholesterol in the grain. Plasma cholesterol levels were also much higher in calves that had a higher aortic lipid content. The increase in plasma cholesterol levels and aortic lipid content is due for the most part to the cholesterol and fat content of the diet. Fat in the diet seems to enhance the absorption of dietary cholesterol; this was noted in eight calves fed milk (ca. 3.5% fat) plus cholesterol and in an experiment conducted where two calves were fed skimmilk plus cholesterol. Plasma cholesterol levels of the two calves fed skimmilk plus cholesterol were very low until 3.5% corn oil and tallow, respectively, were added to the skimmilk; plasma cholesterol levels doubled or more within two days of the addition of the respective fats to the diet.

Cholesterol supplemented to calves receiving grain-only did not seem to be absorbed; this is due in part to the limited fat intake and in part to the action of the ruminoreticulum. The microorganisms of the ruminoreticulum may play an important role in metabolism of cholesterol in the ruminant; it was determined that cholesterol is

degraded by the microbes of the ruminoreticulum. Further studies where calves are fed basically a grain-diet with supplementary cholesterol and fat are needed to clarify the roles of (1) fat in the diet in regards to cholesterol absorption and (2) the effect of ruminoreticulo microbes on cholesterol absorption.

The degenerative features of atherosclerosis in many respects were similar between experimental and nonexperimental animals. The major differences being the extent of aortic calcium deposition in the aged animals and the presence of much lipid on the aortas of the experimental calves fed milk plus cholesterol. Other aspects, i.e., (1) fragmentation and replication of the internal elastic lamina, (2) focal reorientation and proliferation of smooth muscle cells (SMCs) often accompanied by apparent medial degeneration of SMCs and (3) apparent movement of SMCs through fragmented internal elastic lamina and subsequent proliferation were found in experimental and nonexperimental animals. The experimental calves fed milk plus cholesterol in the milk develop features of atherosclerosis as seen in man, i.e., vascular degeneration with concurrent lipid deposition. The nonexperimental ruminants also show atherosclerotic lesions sans the extensive lipid deposition found in man.

This study has been an examination of the occurrence of spontaneous and experimental atherosclerosis in ruminants. Many questions have been raised while conducting this research and while organizing this material for publication. Some of these questions and possible ways to clarify them will now be discussed briefly.

The presence of and the type of (saturated or unsaturated) fat in the diet has been discussed extensively in the literature in regards to atherosclerosis and absorption of cholesterol. Studies with calves receiving milk (a fat source) and cholesterol have shown a positive relationship between the level of fat intake and apparent absorption of cholesterol. Studies where cholesterol was fed to calves on a low fat intake have been confounded by the degradation of cholesterol by microorganisms of the ruminoreticulum. Several studies should be initiated to clarify these problems: (1) various fats should be supplemented (at a rate equivalent to that of calves receiving milk-only) to calves receiving grain-only plus cholesterol, (2) supplement cholesterol via one kilogram milk [see Section III] plus various fats in this milk to make total fat intake equal to that of calves receiving milk-only, (3) feed skimmilk plus cholesterol without and with various fats supplemented at various levels. Plasma cholesterol levels should be monitored as an index of cholesterol absorption. Along with these studies, an in vitro incubation of  $^{14}\text{C}$ -cholesterol should be conducted on liquor from the ruminoreticulum of calves fed grain-only and from calves fed grain-only plus cholesterol; it is suspected that there will be differences in cholesterol-degradative action due to an adaption (increase) of the cholesterol-degradative microbes in grain-fed calves receiving cholesterol.

It would be of interest to determine sites of cholesterol synthesis in the ruminant; this could be accomplished by intravenous infusion of  $^{14}\text{C}$ -acetate and subsequent slaughter and then removal of various tissues



(liver, intestine, muscle, aorta, etc.) for determination of  $^{14}\text{C}$ -cholesterol synthesis. This type of study could be combined with other studies where cholesterol is or is not supplemented; the presence or absence of a negative feedback system in regards to cholesterol synthesis could be determined in the different tissues. By using light and electron microscopic autoradiographic techniques on aortic tissue one could perhaps determine the cell-type where cholesterol is synthesized or deposited.

The characteristics of the cell-types found in the atherosclerotic lesions and thickened intima have been discussed at the level of light microscopy. These cell-types could possibly be identified or at least characterized morphologically by electron microscopic examination.

Calves fed an atherogenic diet (milk plus cholesterol) should be slaughtered at various ages; the coronary arteries and aortas should be examined at both the light and electron microscopic level to determine when the first breakage of the internal elastic lamina occurs and to determine if this "breakage" is the first area for lipid deposition. Some of these calves should be supplemented with magnesium to determine the relationship between a relative magnesium deficiency and elastic tissue integrity.

## LITERATURE CITED

- Abdulla, Y. H., C. W. M. Adams and O. B. Bayliss. 1969. Relative absence of triglycerides in coronary atherosclerotic lesions. *J. Atheroscler. Res.* 10: 149-152.
- Adams, C. W. M., O. B. Bayliss, M. Z. M. Ibrahim and W. A. G. Roper. 1964. Failure of oral magnesium salts to prevent aortic atheroma, hepatic lipid accumulation and hypercholesterolemia in the cholesterol-fed rabbit. *J. Atheroscler. Res.* 4: 283-287.
- \_\_\_\_\_ and N. A. Tuqan. 1961. Elastic degeneration as source of lipids in the early lesions of atherosclerosis. *J. Pathol. Bacteriol.* 82: 131-139.
- Altschul, R. and C. M. Williams. 1962. Effect of plant estrogens on serum cholesterol. *Circulation* 26: 645. (Abstr.).
- Antar, M. A., J. A. Little, C. Lucas, G. C. Buckley and A. Csima. 1970. Interrelationship between the kinds of dietary carbohydrates and fat in hyperlipoproteinemic patients. Part 3. Synergistic effects of sucrose and animal fat on serum lipids. *Atherosclerosis* 11: 191-201.
- Antonius, J. I. and L. D. Hill. 1968. Smooth muscle in human occlusive arterial disease. *J. Atheroscler. Res.* 8: 111-123.
- Arima, K., M. Nagasawa, M. Bae and G. Tamura. 1969. Microbial transformation of sterols. Part 1. Decomposition of cholesterol by microorganisms. *Agr. Biol. Chem.* 33: 1636-1643.
- Armed Forces Institute of Pathology. 1968. Manual of Histologic Staining Methods. 3rd ed. L. G. Luna, Ed. McGraw-Hill Book Company, New York.
- Balis, J. U., M. D. Haust and R. H. More. 1964. Electron microscopic studies in human atherosclerosis. Cellular elements in aortic fatty streaks. *Exp. Mol. Pathol.* 3: 511-525.
- Beveridge, J. M. R., W. F. Connell, G. A. Mayer and H. Faust. 1957. Further assessment of the role of sitosterol in accounting for the plasma cholesterol depressant action of corn oil. *Circulation* 16: 491. (Abstr.).
- Birchwood, B. L., J. A. Little, M. A. Antar, C. Lucas, G. C. Buckley, A. Csima and A. Kallos. 1970. Interrelationship between the kinds of dietary carbohydrates and fat in hyperlipoproteinemic patients. Part 2. Sucrose and starch with mixed saturated and polyunsaturated fats. *Atherosclerosis* 11: 183-190.

- Blankenhorn, D. H. 1963. Calcium deposits in the plaque, pp. 297-314. In Evolution of the Atherosclerotic Plaque. R. J. Jones, Ed. University of Chicago Press, Chicago.
- Bloom, W. and D. W. Fawcett. 1968. A Textbook of Histology. 9th ed. W. B. Saunders Company. Philadelphia, Pa.
- Blumenthal, H. T., A. I. Lansing and S. H. Gray. 1950. The interrelation of elastic tissue and calcium in the genesis of arteriosclerosis. *Amer. J. Pathol.* 26: 989-1009.
- Bohman, V. R., M. A. Wade and C. R. Torrell. 1962. Effect of dietary fat and graded levels of alfalfa on growth and tissue lipids of the bovine. *J. Anim. Sci.* 21: 241-247.
- Böttcher, C. J. F. 1963. Phospholipids of atherosclerotic lesions in the human aorta, pp. 109-116. In Evolution of the Atherosclerotic Plaque. R. J. Jones, Ed. University of Chicago Press, Chicago.
- Breirem, K. 1961. A survey of experiments in animal nutrition carried out at the Agricultural College of Norway. Paper read at Antibiotics in Animal Nutrition. European Symposium, Oslo. June 8-11, 1961.
- Cayen, M. N. 1969. The effect of starvation and cholesterol feeding on intestinal cholesterol synthesis in the rat. *Biochem. Biophys. Acta* 187: 546-554.
- Cheraskin, E., W. M. Ringdorf, Jr., A. T. S. H. Setyaadmadja and R. A. Barret. 1967. Carbohydrate consumption and cardiovascular complaints. *Angiology* 18: 224-230.
- Chung, R. A., P. H. Tsai and C. N. Lai. 1970. Effect of dietary lipids and cholesterol on the levels and synthesis of some hepatic lipid components of young chickens. *Poultry Sci.* 49: 729-733.
- Connor, W. E., J. J. Rohwedder and M. L. Armstrong. 1967. Relative failure of saturated fat in the diet to produce atherosclerosis in the rabbit. *Circ. Res.* 20: 658-663.
- Constantinides, P. 1961. Production of experimental atherosclerosis in animals. *J. Atheroscler. Res.* 1: 374-385.
- \_\_\_\_\_. 1968. Lipid deposition in injured arteries. Electron microscopic study. *Arch. Pathol.* 85: 280-297.
- \_\_\_\_\_, J. Booth and G. Carlson. 1960. Production of advanced atherosclerosis in the rabbit. *Arch. Pathol.* 70: 712-724.
- \_\_\_\_\_ and M. Robinson. 1969. Ultrastructural injury of arterial endothelium I. Effects of pH, osmolarity, anoxia, and temperature. *Arch. Pathol.* 88: 99-105.

- Cook, R. P. 1936. Cholesterol feeding and fat metabolism. *Biochem. J.* 30: 1630-1636.
- Cooke, P. H. and S. C. Smith. 1968. Smooth muscle cells: The source of foam cells in atherosclerotic White Carneau pigeons. *Exp. Mol. Pathol.* 8: 171-189.
- Cookson, F. B. and S. Federoff. 1968. Quantitative relationships between administered cholesterol and alfalfa required to prevent hypercholesterolaemia in rabbits. *Brit. J. Exp. Pathol.* 49: 348-355.
- Cox, G. E., L. B. Nelson, W. B. Wood and C. B. Taylor. 1954. Effect of dietary cholesterol on cholesterol synthesis in monkeys' tissue in vitro. *Fed. Proc.* 13: 31. (Abstr.).
- Day, A. J., H. A. I. Newman and D. B. Zilversmit. 1966. Synthesis of phospholipid by foam cells isolated from rabbit atherosclerotic lesions. *Circ. Res.* 19: 122-138.
- \_\_\_\_\_ and R. K. Tume. 1969. In vitro incorporation of <sup>14</sup>C-labeled oleic acid into combined lipid by foam cells isolated from rabbit atheromatous lesions. *J. Atheroscler. Res.* 9: 141-149.
- Dayton, S. 1959. Turnover of cholesterol in the artery walls of normal chickens. *Circ. Res.* 7: 468-475.
- \_\_\_\_\_ and S. Hashimoto. 1966. Movement of labeled cholesterol between plasma lipoprotein and normal arterial wall across the intimal surface. *Circ. Res.* 19: 1041-1049.
- Dietschy, J. M. and M. D. Siperstein. 1967. Effect of cholesterol feeding and fasting on sterol synthesis in seventeen tissues of the rat. *J. Lipid Res.* 8: 97-104.
- \_\_\_\_\_. 1968. The role of bile salt in controlling the rate of intestinal cholesterologenesis. *J. Clin. Invest.* 47: 286-300.
- Downie, H. G., J. F. Mustard, G. A. Robinson and H. C. Rosewell. 1962. Effect of lard, lard and cholesterol, and egg yolk on serum lipids, blood coagulation, thrombosis and atherosclerosis in swine. *Circulation* 26: 651. (Abstr.).
- Duff, G. L., G. C. McMillan and A. C. Ritchie. 1957. The morphology of early atherosclerotic lesions of the aorta demonstrated by the surface technique in rabbits fed cholesterol, together with a description of the anatomy of the intima of the rabbits' aorta and the "spontaneous" lesion which occur in it. *Amer. J. Pathol.* 33: 845-874.

- Duncan, C. W., C. F. Huffman and C. S. Robinson. 1935. Magnesium studies in calves. I. Tetany produced by a ration of milk or with various supplements. *J. Biol. Chem.* 108: 35-44.
- Ehrich, W., C. De La Chappelle and A. E. Cohn. 1931. Anatomical ontogeny B. Man. 1. A study of the coronary arteries. *Amer. J. Anat.* 49: 241-282.
- Esterly, J. A. and S. Glagov. 1963. Altered permeability of the renal artery of the hypertensive rat. An electron microscopic study. *Amer. J. Pathol.* 43: 619-638.
- Fangman, R. J. and C. A. Hellwig. 1947. Histology of coronary arteries in newborn infants. *Amer. J. Pathol.* 23: 901-902. (Abstr.).
- Farquhar, J. W. and M. Sokolow. 1957. A comparison of the effects of  $\beta$ -sitosterol and safflower oil, alone and in combination, on serum lipids of humans: A long-term study. *Circulation* 16: 494-495. (Abstr.).
- Fraser, R. and F. C. Courtice. 1969. The transport of cholesterol in thoracic duct lymph of animals fed cholesterol with varying triglyceride loads. *Aust. J. Exp. Biol. Med. Sci.* 47: 723-732.
- French, J. E. 1963. Endothelial structure and function, pp. 15-33. In Evolution of the Atherosclerotic Plaque. R. J. Jones, Ed. University of Chicago Press, Chicago.
- Fries, E. D. 1969. Hypertension and atherosclerosis. *Amer. J. Med.* 46: 735-740.
- Geer, J. C., H. C. McGill, Jr. and J. P. Strong. 1961. The fine structure of the human atherosclerotic lesions. *Amer. J. Pathol.* 38: 263-387.
- \_\_\_\_\_, W. Webster, M. A. Nyman and H. C. McGill, Jr. 1957. Cholesterol analyses of sudanophilic streaks in human aortas. *Circulation* 16: 507-508. (Abstr.).
- Getty, R. 1966. Histomorphological studies in the dog and hog as related to ageing, pp. 245-276. In *Radiation and Ageing*. P. J. Lindop and G. A. Sacher, Ed. Taylor and Francis, Ltd., London.
- Gosling, R. G., J. A. Hayes and W. Segre-Mackay. 1969. Induction of atheroma in cockerels as a model for studying alterations in blood flow. *J. Atheroscler. Res.* 9: 47-56.
- Gould, R. G. 1951. Lipid metabolism and atherosclerosis. *Amer. J. Med.* 11: 209-227.

- \_\_\_\_\_, R. W. Wissler and R. J. Jones. 1963. The dynamics of lipid deposition in arteries, pp. 205-214. In Evolution of the Atherosclerotic Plaque. R. J. Jones, Ed. University of Chicago Press, Chicago.
- Gross, L., E. Z. Epstein and M. A. Kugel. 1934. Histology of the coronary arteries and their branches in the human. *Amer. J. Pathol.* 10: 253-274.
- Ham, A. W. 1969. Histology. J. B. Lippincott Company, Philadelphia, Pa.
- Haust, M. D. and R. H. More. 1963. Significance of the smooth muscle cell in atherogenesis, pp. 51-63. In Evolution of the Atherosclerotic Plaque, R. J. Jones, Ed. University Press, Chicago.
- Hegland, R. B., M. R. Lambert, N. L. Jacobson and L. C. Payne. 1957. Effect of dietary and managemental factors on reflex closure of the esophageal groove in the dairy calf. *J. Dairy Sci.* 40: 1107-1113.
- Hellman, L., R. S. Rosenfeld, W. Insull, Jr. and E. H. Ahrens, Jr. 1957. Regulation of plasma cholesterol levels by fecal sterol excretion. *Circulation* 16: 497. (Abstr.).
- Hodges, R. E., W. A. Krehl, D. B. Stone and A. Lopez. 1967. Dietary carbohydrates and low cholesterol diets: Effects on serum lipids of man. *Amer. J. Clin. Nutr.* 20: 198-208.
- Holman, R. L., H. C. McGill, Jr., J. P. Strong and J. C. Geer. 1958a. The natural history of atherosclerosis. The early aortic lesions as seen in New Orleans in the middle of the 20th century. *Amer. J. Pathol.* 34: 209-235.
- \_\_\_\_\_, \_\_\_\_\_, \_\_\_\_\_, and \_\_\_\_\_. 1958b. Technics for studying atherosclerotic lesions. *Lab. Invest.* 7: 42-47.
- Homer, D. R. and A. I. Virtanen. 1966. Cholesterol in the milk of cows on normal and protein-free feeds. *Acta Chem. Scand.* 20: 2321-2322.
- \_\_\_\_\_ and \_\_\_\_\_. 1967. Cow's milk cholesterol - Studies on the milk of cows on normal and protein-free feeds. *"Milchwissenschaft"* 22: 1-20.
- Iritani, N. and N. Takeuchi. 1969. Influence of lactose feeding on cholesterol absorption and metabolism. *J. Atheroscler. Res.* 10: 207-216.
- Ito, M., W. E. Connor, E. J. Blanchette, C. R. Treadwell and G. V. Vahounig. 1969. Inhibition of lymphatic absorption of cholesterol by cholestane-3 $\beta$ , 5 $\alpha$ , 6 $\beta$ -triol. *J. Lipid Res.* 10: 694-702.

- Jacobson, N. L., J. H. Zaletel and R. S. Allen. 1953. Effect of various dietary lipids on the blood plasma lipids of dairy calves. *J. Dairy Sci.* 26: 832-842.
- Jennings, I. W., A. R. Jennings and M. A. F. Burton. 1969. Cardio-vascular disease in free-living Red deer (Cervus elephus) on the Island of Rhum. *J. Compar. Pathol.* 79: 65-71.
- Jennings, M. A., H. W. Florey, W. E. Stehbins and J. E. French. 1961. Intimal changes in the arteries of a pig. *J. Pathol. Bacteriol.* 81: 49-61.
- Kahn, H. A. 1970. Changes in serum cholesterol associated with changes in the United States civilian diet, 1909-1965. *Amer. J. Clin. Nutr.* 83: 879-882.
- Kelly, F. B., Jr., C. B. Taylor, S. Cross, J. Wolski and G. E. Cox. 1957. Hepatic cholesterol levels in rats following the cessation of a high cholesterol diet. *Circulation* 16: 510. (Abstr.).
- Kessler, G. and H. Lederer. 1966. Fluorometric measurement of triglycerides, p. 341. Technicon Symposia; Automation in Analytical Chemistry.
- Knieriem, H. J. 1967. Electron-microscopic study of bovine arteriosclerotic lesions. *Amer. J. Pathol.* 50: 1035-1067.
- \_\_\_\_\_. 1970. Electronmicroscopic studies on the significance of smooth muscle cells in the pathohistogenesis of arteriosclerosis. *Beitr. path. Anat.* 140: 298-332.
- \_\_\_\_\_ and R. Hueber. 1970. Quantitative morphological studies of the human aorta. *Bieter. path. Anat.* 140: 280-297.
- \_\_\_\_\_, V. C. Y. Kao and R. W. Wissler. 1968. Demonstration of smooth muscle cells in bovine arteriosclerosis. An immunohistochemical study. *J. Atheroscler. Res.* 8: 125-136.
- Kritchevsky, D., P. Sallata and S. A. Tepper. 1968. Experimental atherosclerosis in rabbits fed cholesterol-free diets. Part 2. Influence of various carbohydrates. *J. Atheroscler. Res.* 8: 697-703.
- \_\_\_\_\_ and S. Tepper. 1967. Cholesterol vehicle in experimental atherosclerosis. X. Influence of specific saturated fatty acids. *Exp. Mol. Pathol.* 6: 394-401.
- Kumar, V., G. S. Berenson, H. Ruiz, E. R. Dalferes, Jr. and J. P. Strong. 1967a. Acid mucopolysaccharides of human aorta. Part 1. Variations with maturation. *J. Atheroscler. Res.* 7: 573-581.

- \_\_\_\_\_, \_\_\_\_\_, \_\_\_\_\_, \_\_\_\_\_, and \_\_\_\_\_. 1967b. Acid mucopolysaccharides of human aorta. Part 2. Variations with atherosclerotic involvement. *J. Atheroscler. Res.* 7: 583-590.
- Lansing, A. I., M. Alex and T. B. Rosenthal. 1950. Calcium and elastin in human arteriosclerosis. *J. Gerontol.* 5: 112-119.
- Lee, K. T., K. J. Lee, S. K. Lee, H. Imai and R. M. O'Neal. 1970. Poorly differentiated subendothelial cells in swine aorta. *Exp. Mol. Pathol.* 13: 118-129.
- Levene, C. I. 1956a. The early lesions of Atheroma in the coronary arteries. *J. Pathol. Bacteriol.* 72: 79-82.
- \_\_\_\_\_. 1956b. The pathogenesis of atheroma of the coronary arteries. *J. Pathol. Bacteriol.* 72: 83-86.
- Likar, I. N., L. J. Likar and R. W. Robinson. 1966a. Bovine Arterial Disease. II. Lipid distribution and pattern in abdominal aorta with and without naturally occurring gross lesions. *Arch. Pathol.* 82: 561-565.
- \_\_\_\_\_, \_\_\_\_\_ and \_\_\_\_\_. 1966b. Bovine arterial disease. I. Localization of lipids in the abdominal aorta in relation to bovine atherosclerosis. *Arch. Path.* 82: 555-560.
- \_\_\_\_\_, \_\_\_\_\_ and \_\_\_\_\_. 1968a. Bovine arterial disease. Part 3. Elastic tissue and mucal acid mucopolysaccharides in bovine coronary arteries without gross lesions. *J. Artheroscler. Res.* 8: 643-655.
- \_\_\_\_\_, \_\_\_\_\_ and \_\_\_\_\_. 1968b. Levels and patterns of acid mucopolysaccharides in bovine coronary arteries without gross lesions. *Acta Endocrinolog.* 59: 668-681.
- \_\_\_\_\_, \_\_\_\_\_, \_\_\_\_\_ and A. Gouvelis. 1969. Microthrombi and intimal thickening in bovine coronary arteries. *Arch. Pathol.* 87: 146-153.
- Lindsey, C. A., Jr. and J. D. Wilson. 1965. Evidence for a contribution by the intestinal wall to the serum cholesterol of the rat. *J. Lipid Res.* 6: 173-181.
- Lison, L. 1954. Alcian blue 8G with chlorantine fast red 5B. A technic for selective staining of mucopolysaccharides. *Stain Technol.* 29: 131-138.
- Lloyd, J. K. and O. H. Wolff. 1969. A paediatric approach to the prevention of atherosclerosis. *J. Atheroscler. Res.* 70: 135-138.



- Lofland, H. B. and T. B. Clarkson. 1959. A biochemical study of spontaneous atherosclerosis in pigeons. *Circ. Res.* 7: 234-237.
- \_\_\_\_\_ and \_\_\_\_\_. 1970. The bi-directional transfer of cholesterol in normal aorta, fatty streaks, and atheromatous plaques. *Proc. Soc. Exp. Biol. Med.* 133: 1-8.
- \_\_\_\_\_, \_\_\_\_\_, and H. O. Goodman. 1961. Interactions among dietary fat, protein and cholesterol in atherosclerosis-susceptible pigeons. *Circ. Res.* 9: 917-924.
- Lofland, H. B., Jr., D. M. Moury, C. W. Hoffman and T. B. Clarkson. 1965. Lipid metabolism in pigeon aorta during atherogenesis. *J. Lipid Res.* 6: 112-118.
- Malmros, H. 1969. Dietary prevention of atherosclerosis. *The Lancet* 1969: 479-483.
- Masironi, R. 1970. Dietary factors and coronary heart disease. *Bull. W. H. O.* 42: 103-114.
- McGill, H. C., Jr. and J. C. Geer. 1963. The human lesion fine structure, pp. 65-76. In Evolution of the Atherosclerotic Plaque. R. J. Jones, Ed. University of Chicago Press, Chicago.
- McKinney, B. 1968. Atherosclerosis in the African Buffalo (Syncerus caffer) and comparative studies in man. *J. Pathol. Bacteriol.* 95: 301-304.
- McMartin, D. N., J. C. Geer, A. Koestner and D. G. Cornwell. 1970. Effect of age on lipid composition and morphology of the bovine aorta. *Arch. Pathol.* 89: 164-172.
- Middleton, C. C., T. B. Clarkson, H. B. Lofland and R. W. Prichard. 1967. Diet and atherosclerosis of Squirrel monkeys. *Arch. Pathol.* 83: 145-153.
- Moon, H. D. 1957. Coronary arteries in fetuses, infants, and juveniles. *Circulation* 16: 263-269.
- Moore, L. A., E. T. Hallman and L. B. Sholl. 1938. Cardiovascular and other lesions in calves fed diets low in magnesium. *Arch. Pathol.* 26: 820-838.
- Moore, S. and J. Lough. 1970. Lipid accumulation in renal arterioles due to platelet aggregate embolism. *Amer. J. Pathol.* 58: 283-293.
- Moses, C., J. R. Jablonski, T. S. Danowski and M. H. Kunkle. 1957. Changes in lipid and lipoprotein partition induced by feeding a skim-milk-corn oil mixture. *Circulation* 16: 511-512. (Abstr.).

- Mustard, J. F., E. A. Murphy, H. C. Rowsell and H. G. Downie. 1964. Platelets and atherosclerosis. *J. Atheroscler. Res.* 4: 1-28.
- Nakamura, M., S. Torii, M. Hiramatsu, J. Hirano, A. Sumiyoshi and K. Tanaka. 1965. Dietary effect of magnesium on cholesterol-induced atherosclerosis of rabbits. *J. Atheroscler. Res.* 5: 145-158.
- Nakamura, T., K. Tokita, S. Tateno, T. Koktoku and T. Ohba. 1968. Human aortic acid mucopolysaccharides and glycoproteins. Changes during ageing and in atherosclerosis. *J. Atheroscler. Res.* 8: 891-902.
- Newman, H. A. I., E. L. McCandless and D. B. Zilversmit. 1961. The synthesis of  $C^{14}$ -lipids in rabbit atheromatous lesions. *J. Biol. Chem.* 236: 1264-1268.
- \_\_\_\_\_ and D. B. Zilversmit. 1962. Quantitative aspects of cholesterol flux in rabbit atheromatous lesions. *J. Biol. Chem.* 237: 2078-2084.
- Noller, C. H., G. M. Ward, A. D. McGilliard, C. F. Huffman and C. W. Duncan. 1956. The effect of age of the calf on the availability of nutrients in vegetable milk-replacer rations. *J. Dairy Sci.* 39: 1288-1298.
- Okey, R. and M. M. Lyman. 1954. Dietary constituents which may influence the use of food cholesterol. *J. Nutr.* 53: 601-611.
- Ørskov, E. R. and D. Benzie. 1968. Using the oesophageal groove reflex in ruminants as a means of bypassing rumen fermentation with high-quality protein and other nutrients. *Proc. Nutr. Soc.* 28: 30A.
- Parker, F. and G. F. Odland. 1966. A correlative histochemical, biochemical and electron microscopic study of experimental atherosclerosis in the rabbit aorta with special reference to the myo-intimal cell. *Amer. J. Pathol.* 48: 197-239.
- \_\_\_\_\_, J. W. Ormsby, N. F. Peterson, G. F. Odland and R. H. Williams. 1966. In vitro studies of phospholipid synthesis in experimental atherosclerosis. *Circ. Res.* 19: 700-710.
- Pick, R., J. Stamler and L. N. Katz. 1959. Effects of high protein intakes on cholesterolemia and atherogenesis in growing and mature chickens fed high-fat, high-cholesterol diets. *Circ. Res.* 7: 866-869.
- Platt, W. R. 1969. Color Atlas and Textbook of Hematology. J. B. Lippincott Company. Philadelphia, Pa.
- Pollak, O. J. 1957. Rabbits on egg diets. *Circulation* 16: 494. (Abstr.).

- Pomeranze, J., A. Goalwin and L. B. Slobody. 1957. Effect of dietary fat on serum cholesterol levels in infancy and childhood. *Circulation* 16: 481. (Abstr.).
- Prior, J. T. and D. B. Jones. 1952. Structural alterations within the aortic intima in infancy and childhood. *Amer. J. Pathol.* 28: 937-951.
- Rademeyer, L. J. and J. Booyens. 1965. The effects of variations in the fat and carbohydrate content of the diet on the levels of magnesium and cholesterol in the serum of white rats. *Brit. J. Nutr.* 19: 153-162.
- Ratcliffe, H. L., H. Luginbühl and L. Pivnik. 1970. Coronary, aortic and cerebral atherosclerosis in swine of 3 age-groups: Implications. *Bull. W. H. O.* 42: 225-234.
- Reiser, R., D. A. Clark, M. F. Sorrel, B. S. Gibson, M. C. Williams and F. H. Wilson. 1966. Tissue cholesterol transport as modified by diet cholesterol and the nature of diet fat. *J. Atheroscler. Res.* 6: 565-579.
- Rodbard, S., C. Bolene and L. N. Katz. 1951. Hypercholesteremia and atheromatosis in chicks on a restricted diet containing cholesterol. *Circulation* 4: 43-46.
- Roser, B. J. and F. R. Magarey. 1964. Spontaneous "atheroma" in sheep. *J. Pathol. Bacteriol.* 88: 73-78.
- Samy, T. S. A. and H. R. Cama. 1964. Role of dietary fats in inducing hypercholesterolemia in rats. *J. Atheroscler. Res.* 4: 356-366.
- Siperstein, M. D. and I. L. Chaikoff. 1955. Conversion of cholesterol to bile acids. *Fed. Proc.* 14: 767-774.
- Skold, B. H., N. L. Jacobson and R. Getty. 1967. Spontaneous atherosclerosis of bovine. *J. Dairy Sci.* 50: 1712-1714.
- Smith, E. B., P. H. Evans and M. D. Downham. 1967. Lipid in the aortic intima. The correlation of morphological and chemical characteristics. *J. Atheroscler. Res.* 7: 171-186.
- Smith, R. H. 1964. Hypomagnesaemia in calves. Reprint Rep. III International Meeting Diseases of Cattle. Copenhagen. pp. 143-166.
- Snedecor, G. W. and W. G. Cochran. 1967. Statistical Methods. 6th ed. The Iowa State University Press, Ames, Iowa.
- Somogyi, M. 1945. The determination of blood sugar. *J. Biol. Chem.* 160: 69-73.

- Stary, H. C. and G. C. McMillan. 1970. Kinetics of cellular proliferation in experimental atherosclerosis. Radioautography with grain counts in cholesterol-fed rabbits. Arch. Pathol. 89: 173-183.
- Stehbens, W. E. 1963. The renal artery in normal and cholesterol-fed rabbits. Amer. J. Pathol. 43: 969-985.
- \_\_\_\_\_. 1964. Localization of spontaneous lipid deposition in the cerebral arteries of sheep. Nature 203: 1294-1295.
- \_\_\_\_\_. 1965. Intimal proliferation and spontaneous lipid deposition in the cerebral arteries of sheep and steers. J. Atheroscler. Res. 5: 556-568.
- Steiner, A., A. Varson and D. Rudman. 1957. Effect of a formula diet containing various vegetable oils upon the serum lipids of human subjects. Circulation 16: 495. (Abstr.).
- Still, W. J. S. 1970. Hyperlipemia and the arterial intima of the hypertensive rat. Arch. Pathol. 89: 392-404.
- Stout, C. and F. Bohorquez. 1969. Aortic atherosclerosis in hoofed mammals. J. Atheroscler. Res. 9: 73-80.
- Stout, R. W. 1969. Insulin stimulation of cholesterol synthesis by arterial tissue. The Lancet 1969: 467-468.
- Strong, J. P. and H. C. McGill, Jr. 1962. The natural history of coronary atherosclerosis. Amer. J. Pathol. 40: 37-49.
- Taher, E. S. and R. Berg. 1969. Micromorphological studies on the coronary vessels of the camel (Camelus dromedarius). Part I. Micromorphology of the coronary arteries in camel fetuses. Zbl. Vet. Med. A. 16: 52-60.
- Taylor, C. B. and K. J. Ho. 1967. A review of human cholesterol metabolism. Arch. Pathol. 84: 3-14.
- Technicon Auto-Analyzer Methodology N-24a. 1965. Total cholesterol in serum. Technicon Instruments Corp., Chauncey, New York.
- Thomas, W. A., R. A. Florentin, S. C. Nam, D. N. Kim, R. M. Jones and K. T. Lee. 1968. Pre-proliferative phase of atherosclerosis in swine fed cholesterol. Arch. Pathol. 86: 621-643.
- Ts'ao, C. 1970. Graded endothelial injury of the rabbit aorta. With special reference to platelet deposition. Arch. Pathol. 90: 222-229.

- Vitale, J. J., E. E. Hellerstein, M. Nakamura and B. Brown. 1961. Effects of magnesium-deficient diet upon puppies. *Circ. Res.* 9: 387-394.
- \_\_\_\_\_, H. Velez, C. Guzman and P. Correa. 1963. Magnesium deficiency in the Cebus monkey. *Circ. Res.* 12: 642-650.
- \_\_\_\_\_, P. L. White, M. Nakamura, D. M. Hegsted, N. Zamcheck and E. E. Hellerstein. 1957. Interrelationships between experimental hypercholesterolemia, magnesium requirements and experimental atherosclerosis. *J. Exp. Med.* 106: 757-766.
- Vles, R. O., J. Büller, J. J. Gottenbos and H. J. Thomasson. 1964. Influence of type of dietary fat on cholesterol induced atherosclerosis in the rabbit. *J. Atheroscler. Res.* 4: 170-183.
- Wang, C., L. Strauss and D. Adlersberg. 1956. The role of acid mucopolysaccharides in the development of atherosclerosis in the rabbit. *Circulation* 14: 481 (Abstr.).
- Watts, H. F. 1963. Role of lipoproteins in the formation of atherosclerotic lesions, pp. 117-132. In Evolution of the Atherosclerotic Plaque. R. J. Jones, Ed. University of Chicago Press, Chicago.
- Webster, J. 1930. The ruminant reflex in the ox. *Vet. J.* 86: 401-410.
- Wener, J., K. Pintar, M. A. Simon, R. Motola, R. Friedman, A. Mayman and R. Schucher. 1964. The effects of prolonged hypomagnesemia on the cardiovascular system in young dogs. *Amer. Heart J.* 67: 221-231.
- Wiggers, K. D., N. L. Jacobson and R. Getty. 1971. Atherosclerosis in ruminants. *J. Anim. Sci.* 32: (in press).
- Wilens, S. L. 1951. The nature of diffuse intimal thickening of arteries. *Amer. J. Pathol.* 27: 825-839.
- Wilkins, J. A., H. De Wit and B. Bronte-Stewart. 1962. A proposed mechanism for the effect of different dietary fats on some aspects of cholesterol metabolism. *Can. J. Biochem. Physiol.* 40: 1091-1100.
- Wilson, J. D., C. A. Lindsey and J. M. Dietschy. 1968. Influence of dietary cholesterol on cholesterol metabolism. *Ann. N. Y. Acad. Sci.* 149: 808-821.
- Wise, G. H. and G. W. Anderson. 1939. Factors affecting the passage of liquids into the rumen of the dairy calf. I. Method of administering liquids: drinking from open pail versus sucking through a rubber nipple. *J. Dairy Sci.* 22: 697-705.

- Wissler, R. W. 1968. The arterial medial cell, smooth muscle or multifunctional mesenchyme? J. Atheroscler. Res. 8: 201-213.
- Young, J. W., E. O. Otchere, A. Trenkle and N. L. Jacobson. 1970. The effect of age on glucose, reducing sugars and plasma insulin in blood of milk-fed calves. J. Nutr. 100: 1267-1273.
- Yu, S. Y. and H. T. Blumenthal. 1963. The calcification of elastic fibers. I. Biochemical studies. J. Gerontol. 18: 119-126.
- Yudkin, J. 1969. Dietary sugar and coronary heart disease. Nutr. News. 32: 9, 12.
- Zilversmit, D. B. 1968a. Cholesterol flux in the atherosclerotic plaque. Ann. N. Y. Acad. Sci. 149: 710-724.
- \_\_\_\_\_. 1968b. Cholesterol flux in vitro in aortas of cholesterol-fed and non-cholesterol-fed pigeons. Atherosclerosis 11: 235-246.
- Zugibe, F. T. and K. D. Brown. 1960. Histochemical studies in atherogenesis: Human aortas. Circ. Res. 8: 287-295.
- \_\_\_\_\_, K. D. Brown and J. H. Last. 1959. A new technique for the simultaneous demonstration of lipid and acid polysaccharides on the same tissue section. J. Histochem. 7: 101-106.
- \_\_\_\_\_, M. L. Fink and K. D. Brown. 1959. Carbowax 400: A new solvent for oil red O and sudan IV for staining carbowax-embedded and frozen sections. Stain Technol. 34: 33-37.

## ACKNOWLEDGEMENTS

The author wishes to express appreciation to Dr. Norman L. Jacobson for his assistance and advice in planning and conducting this study and in writing this thesis; to Dr. Robert Getty for advice on histological interpretation; to Dr. Gordon Thomson for programming the experimental data for statistical analysis; to Mrs. Marlene Richard for advice and assistance in laboratory work; to Miss Rose Aspengren for laboratory assistance; to Miss Joyce Smith for very prompt typing of this thesis; and to Iowa State University and those responsible for furnishing excellent laboratory and office facilities.