CLINICAL MEDICINE

Index

1 **A Compound Comminuted Fracture in an Arabian Stallion.** On Nov. 3, 1952, a 6-year-old Arabian stallion, Iben Fadl, was admitted to the Stange Memorial Clinic with a history of fracturing the left front leg the previous day.

Examination of the leg revealed a swollen left front ankle with an open wound on the lateral side of the pastern. Manual manipulation of the affected part produced pain and crepitations could be felt. A diagnosis of compound comminuted fracture was made.

An X-ray was taken to determine the extent of the bone pathology. The radiogram depicted the first phalanx shattered into some two hundred fragments with the fracture extending into both the fetlock joint and the articulation of the first and second phalanges.

Five hundred and fifty cubic centimeters of Millenbruck's anesthetic solution was administered intravenously to produce and maintain surgical anesthesia. The following surgical manipulations were employed: the hair was clipped from around the break in the skin, the wound irrigated with a mild potassium permanganate solution and sulfanilimide powder applied. Then boric acid powder was applied and the leg well wrapped with cotton from the manus to the olecranon. After the first phalanx was manipulated, four plaster of paris impregnated gauze bandages, which had been soaked in water three minutes, were applied over a generous amount of cotton on the extended leg. This afforded the leg protection from the four metal splints which were formed to fit the contour of the leg and bent over two inches at the bottom to fit under the foot. These splints were placed into position and wrapped with wet plaster-of-paris gauze with extreme care. A great number of wet plaster-of-paris bandages were applied, so when dry a strong and suitable cast was formed.

The patient recovered from anesthesia three hours later and was helped to his feet.

A mixture of boric acid and air slaked lime powder was sprinkled inside the cast

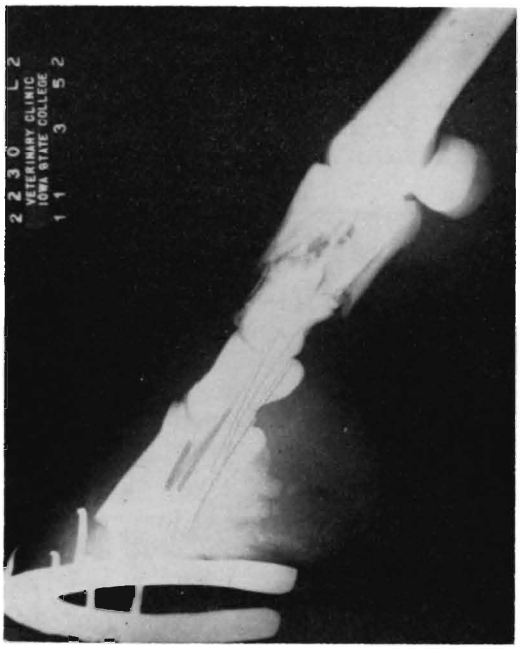

X-ray of comminuted fracture

daily. In a few days the patient's temperature and respiratory rate were somewhat higher than normal. He placed no weight on the cast, his appetite declined progressively, and he was losing condition. The patient did not lie down for the first sixteen days after the cast was applied. Extreme fatigue forced him to lie down, and after he found that he could regain his feet, he took advantage of much needed rest.

As soon as his appetite began to decline, daily internal medication was started. This consisted of a No. 10 capsule of equal parts of gentian, ginger and nux vomica and one capsule of a mixture of a vitamin supplement and bone meal. He soon began eating and drinking favorably, appearing to be alert and in good spirits. At this time, medication was no longer given in capsules, but placed on his grain twice daily, this consisting of bonemeal and a vitamin preparation.

A period of uneventful progress followed. The daily application of powder inside the cast continued and the cast was watched very closely because muscular atrophy was causing it to loosen. The patient was now beginning to put some weight on the cast.

On Nov. 26, 1952, the original cast was removed prompted by his showing a slight temperature rise. Upon removal it was revealed that the break in the skin at the point of fracture was healed, but a necrotic area had developed eight inches below the point of the olecranon. Two X-rays were taken and these revealed osteoid tissue filling in between the bone fragments and around the comminuted area. The formation of this provisional callus was very encouraging.

The leg was again placed in a cast, and this extended to a few inches below the necrotic area that had developed. The necrotic area was treated with sulfathiazole powder for a few days and then sulfa-urea powder was used. The sterile gauze bandage used to cover the wound was changed daily.

During the period of hospitalization that followed, the patient spent a great deal of time lying down and developed a decubitus ulcer at the point of the tuber coxae. He also pulled at his leg with his teeth because of pruritus and produced an abrasion just above the cast on the lateral side. A neck cradle was applied immediately; however, it was removed a few days later.

Daily treatment was given to his wounds which were healing uneventfully, and on January 6, the cast was removed and X-rays showed that calcification was taking place and a permanent callus had formed.

The patient began progressively using his leg and daily improvement was noted.

On January 22, Iben Fadl, still maintaining a slight limp and having only one superficial wound left with an eschar, was discharged. During his three-month nineteen-day stay, only once did this ideal and loveable patient misbehave, that being the time it was necessary that he wear a neck cradle for four days.

This case is interesting because of the severity of the fracture, and because this stallion as spirited as he was, seemed to do everything he could to promote his own recovery.

Edward J. Murphy, '54