

Experimental canine leptospirosis caused by *Leptospira interrogans* serovars pomona and bratislava

Justin J. Greenlee, DVM, PhD; David P. Alt, DVM, PhD; Carole A. Bolin, DVM, PhD;
Richard L. Zuerner, PhD; Claire B. Andreasen, DVM, PhD

Objective—To evaluate gross, histopathologic, and serum biochemical findings caused by *Leptospira interrogans* serovars pomona and bratislava inoculated in dogs.

Animals—Twenty-seven 8-week-old female Beagles.

Procedure—Dogs were randomly assigned to challenge or control groups. Challenge groups were conjunctivally inoculated on 3 successive days with 5×10^7 *L. interrogans* serovar pomona ($n = 12$) or serovar bratislava (11). Clinical signs were recorded throughout the experiment, and clinical pathology assays, bacteriologic culture, and necropsies (6 or 7 dogs necropsied at each time point) were done on postinoculation day (PID) 7, 10, 14, and 20.

Results—Infection could not be confirmed in any serovar bratislava-inoculated dog, and control dogs remained healthy throughout the experiment. Positive culture and fluorescent antibody test results were confirmed in 11 of 12 serovar pomona-inoculated dogs. Fever and lethargy starting at PID 7 were the most common clinical signs in serovar pomona-infected dogs. On day 10, gross lesions included multifocal renal and pulmonary hemorrhage and perirenal edema. Serovar pomona-inoculated dogs had histopathologic lesions including hepatitis, interstitial nephritis, and pneumonia at PID 7, 10, 14, and 20. Increases in BUN, anion gap, and bilirubin concentration occurred on PID 10, 14, and 20. Platelet counts in dogs with positive results of bacteriologic culture were decreased from baseline values on PID 10, 12, and 14.

Conclusions and Clinical Relevance—Conjunctival inoculation with *L. interrogans* serovar pomona resulted in a high rate of infection with concomitant hemorrhagic and inflammatory lesions of the kidneys, liver, and lungs. (*Am J Vet Res* 2005;66:1816–1822)

Leptospirosis, one of the most widespread zoonoses,¹ is a reemerging cause of renal failure and hepatic disease in dogs.² The diagnosis of canine leptospirosis in the United States and Canada substantially increased

between 1983 and 1998.³ Traditionally, *Leptospira interrogans* serovars canicola and icterohaemorrhagiae have been a major cause of canine leptospirosis. Experimental disease caused by serovars canicola and icterohaemorrhagiae has been described,^{4–11} and the use of vaccines containing these serovars has substantially reduced the incidence of disease caused by them.^{12,13} However, in the past decade, other serovars such as *Leptospira kirschneri* serovar grippotyphosa and *L. interrogans* serovars pomona and bratislava have been associated with an increasing percentage of reported cases,^{2,3,12,14–16} and until recently, vaccines have not been available to protect against them. Features of canine leptospirosis that may be serovar specific have not been well characterized because of the paucity of experimental studies and the inability to determine the time of exposure in clinical cases. Experimental studies are needed to better understand the progression of clinical signs and clinicopathologic abnormalities in the course of disease with these reemerging serovars. The purpose of the study reported here was to inoculate dogs with *Leptospira interrogans* serovars pomona and bratislava and monitor clinical signs, changes in CBC and serum biochemical profiles, and gross and histopathologic lesions at necropsy.

Materials and Methods

Dogs—Twenty-seven 8-week-old female Beagles without detectable antibodies against *L. interrogans* serovars bratislava or pomona (microscopic agglutination test [MAT])¹⁷ were obtained from a commercial laboratory animal vendor.^a Upon arrival, dogs were examined and randomly allocated into 3 groups: 4 control dogs, 12 serovar pomona-inoculated dogs, and 11 serovar bratislava-inoculated dogs. Inoculated dogs were housed in biosafety level 2 rooms at Iowa State University. Dogs were housed in pairs in a room maintained at a constant temperature and humidity. Cages were cleaned once daily, and food and water were available at all times and freshened twice daily. All animal experiments were performed with the approval of the Iowa State University Committee on Animal Care.

Leptospires—Two bacterial isolates were used. *Leptospira interrogans* serovar pomona type kennewicki

Received July 12, 2004.

Accepted December 20, 2004.

From the Department of Veterinary Pathology, College of Veterinary Medicine, Iowa State University, Ames, IA 50011 (Greenlee, Andreasen); and the Bacterial Diseases of Livestock Research Unit, National Animal Disease Center, Agricultural Research Service, USDA, Ames, IA 50011 (Alt, Bolin, Zuerner). Dr. Greenlee's present address is Virus and Prion Diseases of Livestock Research Unit, National Animal Disease Center, PO Box 70, Ames, IA 50011. Dr. Bolin's present address is Diagnostic Center for Population and Animal Health, College of Veterinary Medicine, Michigan State University, East Lansing, MI 48824.

Supported by a grant from the Biotechnology Research and Development Corporation.

Presented in part at the American College of Veterinary Pathologists Annual Meeting, New Orleans, December 2002.

The authors thank Rick Hornsby (leptospirosis culture) and Stacy Friesen (immunohistochemical staining) for technical assistance.

Address correspondence to Dr. Greenlee.

strain RM211 was isolated at the National Animal Disease Center from neonatal kidney and liver tissues from an Iowa swine herd that were submitted to the Veterinary Diagnostic Laboratory at Iowa State University.¹⁸ The herd had a history of 25 of 75 pregnancies resulting in abortion or stillbirth. *Leptospira interrogans* serovar bratislava strain Alex was isolated from urine obtained from a dog in Indiana with a 1:640 titer against serovar bratislava as detected by use of the MAT.¹⁹ Organisms of both serovars used for inoculation were grown from a frozen aliquot of the original culture.

Experimental design—Inoculations were performed after a 6-day acclimation period. Two days prior to inoculation, samples were taken from each dog for CBC, serum biochemical profile, and urinalysis, and no abnormalities were detected. The dogs were observed for clinical signs at least twice daily and rectal temperatures recorded once daily throughout the experiment. Dogs were challenged on 3 consecutive days (day 0, 1, and 2) with 5×10^7 leptospire in 250 μ L of 80/40 liquid culture medium²⁰/eye (a concentration of 2×10^8 organisms/mL quantified by use of a Petroff-Hausser counting chamber), which was placed onto the corneal surface of each eye of each dog and allowed to run onto the conjunctiva. Dogs 1 to 4 ($n = 4$) served as controls and were inoculated with an equal volume of sterile culture media. Dogs 5 to 16 ($n = 12$) were inoculated with *L. interrogans* serovar pomona type kennewicki strain RM 211. Dogs 17 to 27 ($n = 11$) were inoculated with *L. interrogans* serovar bratislava strain Alex.

Necropsy and sample collection—On days 5, 8, and 12 of the experiment, blood was drawn for bacteriologic culture. Prior to necropsies done on days 7, 10, 14, and 20, additional blood samples were drawn from all dogs for measurement of CBC and serum biochemical panels including concentrations or activities of sodium, potassium, chloride, total CO₂, calcium, phosphorus, BUN, creatinine, glucose, total protein, albumin, alanine aminotransferase, **alkaline phosphatase (ALP)**, **γ -glutamyltransferase (GGT)**, creatine kinase, **direct bilirubin (Dbili)**, **total bilirubin (Tbili)**, and anion gap. For each time point, 2 or 3 dogs inoculated with each serovar and 1 control dog were necropsied. Dogs were euthanatized by administration of an overdose of sodium pentobarbital. During necropsy, liver, kidney, and urine were taken aseptically for bacteriologic culture and immunofluorescence testing. Samples of kidney, liver, lung, hepatic lymph node, adrenal gland, spleen, heart, tonsil, mesenteric lymph node, pancreas, stomach, jejunum, vulva, urinary bladder, bone marrow, iliac lymph node, colon, ileum, and cecum were collected into neutral-buffered 10% formalin. An eye and conjunctival sample were collected into Bouin fixative.

Histologic examination—Tissues for histologic evaluation were collected into neutral-buffered 10% formalin and processed via standard paraffin-embedding techniques after 24 hours. Sections were cut at 5 μ m except for kidney, lymph nodes, and adrenal gland, which were cut at 3 μ m. All sections were stained with H&E. Histopathologic grading of selected lesions of liver and kidney was done using mild (+), moderate (++), and severe (+++) designations. For interstitial nephritis, tubular mineralization, and hepatic perivascular inflammation, the scores were assigned as follows: (–) = no change from control dogs, (+) = 1 to 3 foci/section examined, (++) = 4 to 6 foci/section examined, (+++) = > 6 foci/section examined. Tubular degeneration was graded (+) when scattered cells were detected with pyknotic nuclei or loss of polarity, (++) when these changes were present in larger sections of a tubule, and (+++) when multiple tubules in an area were affected. Tubular dilation was scored (+) when scattered tubular lumens were severely widened and lined by a thin

layer of epithelium, (++) when multiple tubules were affected, and (+++) when the cortex was diffusely affected.

Leptospiral culture and polymerase chain reaction assay—Bacteriologic cultures of blood were performed on **postinoculation day (PID)** 5, 8, 10, 12, 14, 22, and 28. Liver and kidney samples of approximately 1 g and aqueous humor and urine samples of 1 mL were obtained at necropsy and processed for isolation of leptospire. Three media were used for isolations. First, Tween 80/Tween 40/lactalbumin hydrolysate was used as described²⁰ with slight modifications: 5-fluorouracil was used at a rate of 100 μ g/mL, and nalidixic acid was not used. Second, Ellinghausen-McCullough-Johnson-Harris semisolid medium was used as described²¹ with the modifications of 10% bovine serum albumin, 100 μ g of 5-fluorouracil/mL, and 1% rabbit serum. Finally, commercial polysorbate *Leptospira* medium^b was used with the addition of purified agar and 100 μ g of 5-fluorouracil/mL. Cultures were incubated at 29°C for 6 months. Dark-field examination was performed at 1, 2, 4, 6, and 8 weeks and at 3, 4, 5, and 6 months. If cultures became contaminated, approximately 1 mL was filtered through a 0.22- μ m filter into new medium. Representative isolates were identified via restriction endonuclease analysis of chromosomal DNA.²² Isolation of genomic DNA was done with a commercial kit,^c and amplification by **polymerase chain reaction (PCR)** was performed on kidney tissue as described.²³

Serologic examination—Blood was obtained from dogs prior to inoculation and at PID 7, 14, 22, and 28. Serum was separated and tested for agglutinating antibodies against serovars pomona or bratislava, respectively, by use of the MAT.¹⁷

Immunofluorescence testing—Samples of urine, kidney, aqueous humor, and liver were processed and stained as described.^{24,25} Leptospire were identified by typical size, morphologic characteristics, and fluorescence when examined via incident light fluorescence microscopy.

Immunohistochemical analysis—Immunohistochemical staining was done on a subset of dogs' tissues to determine the patterns of antigen distribution after infection was confirmed via positive results of culture or immunofluorescence. Two primary antisera were used at the stated dilutions: polyclonal rabbit antisera^d specific to the outer membrane protein OmpL1²⁶ (1:6,000) and polyclonal rabbit antisera with serovar pomona specificity (1:8,000) as described.^{25,27} Briefly, 5- μ m sections were cut, placed on positively charged slides, and deparaffinized with xylene and ethanol by use of standard procedures. Slide-mounted tissue sections were rinsed in **potassium phosphate-buffered solution (KPBS; 0.15M NaCl, 0.034M K₂HPO₄, 0.017M KH₂PO₄; pH, 7.4)**, and antigen retrieval was performed by incubating slides for 7 minutes in 37°C KPBS with 0.1% trypsin and 0.1% CaCl₂. After 2 rinses in KPBS, endogenous peroxidase activity was eliminated by 30-minute incubation in 0.3% hydrogen peroxide solution in KPBS. The sections were then incubated for 2 hours in blocking solution (KPBS with 1% bovine serum albumin,^e 0.4% Triton X-100,^f and 1.5% normal blocking serum)^g and incubated overnight at room temperature (24°C) in primary antiserum. On the following day, tissue sections were rinsed in KPBS with 0.2% Triton X-100 and incubated in an appropriate biotinylated secondary antibody^h for 2 hours at room temperature, rinsed, and incubated in horseradish peroxidase-avidin-biotin complexⁱ for 1 hour at room temperature. Enzyme reactions were developed with a substrate kit that produced a red reaction.^j The reaction was terminated in successive rinses of 0.9% NaCl solution. Slides were counterstained with hematoxylin, dehydrated through graded alcohols, and cover slipped.

Results

Clinical signs and leptospiral culture—Clinical signs in serovar pomona-inoculated dogs began on PID 7 and included lethargy, fever, and inappetence. Seven serovar pomona-inoculated dogs were febrile (range, 39.3° to 40.2°C) on PID 7 (1/7), 8 to 9 (2/7), 11 to 13 (3/7), and 17 to 18 (1/7). Three serovar pomona-inoculated dogs had loose feces with small amounts of blood on PID 7 to 10. One dog necropsied on day 20 had a progressively worsening wasting syndrome characterized by poor food intake; rough coat; scant, dark feces; and failure to gain weight.

A dog was considered infected if leptospires were detected in tissues or body fluids via culture, immunofluorescence, or immunohistochemical analysis. Culture and immunofluorescence test results (Table 1) were negative in all control dogs (4/4). Serovar bratislava was not detected in any tissue by use of bacteriologic culture or immunofluorescence testing (0/11). Serovar pomona was detected 11 of 12 inoculated dogs. Results of bacteriologic culture of blood of pomona-inoculated dogs (11/12) were positive at PID 7 or 8, but infection could not be confirmed by any other method at those early time points. Culture, immunofluorescence testing, and PCR methods yielded positive results in these dogs (8/9) after PID 10. Leptospires were cultured from kidney (8/9), urine (5/7), aqueous humor (5/9), and liver (6/9) at PID 10 or later, and 11 of 12 dogs yielded positive results via PCR during that time period. Immunofluorescence testing revealed leptospiral antigen in kidney (8/9), liver (6/9), and urine (5/7) at necropsy when performed at PID 10 or later.

Necropsy—No abnormalities except ocular discharge and conjunctival hyperemia in 2 serovar pomona-inoculated dogs at PID 10 were detected via external examination prior to necropsy. One serovar pomona-inoculated dog necropsied at PID 10 continued to bleed for an abnormally long period of time after venipuncture for antemortem serum biochemical assays. Gross lesions were evident in serovar pomona-inoculated dogs necropsied on PID 10, 14, and 20 and consisted of multifocal pulmonary petechial hemorrhage (Figure 1) and renal petechial and ecchymotic subcapsular and parenchymal hemorrhage (Figures 2 and 3), perirenal edema, friable liver with multifocal 1- to 2-mm raised white foci, and enlarged and reddened hepatic and internal iliac lymph nodes. One serovar pomona-inoculated dog (with the described wasting syndrome), which had been febrile on days 11 and 13

and was necropsied at day 20, had dark, bloody feces; a friable, pale, and yellow liver; and multifocal brown pulmonary hemorrhages. No gross lesions were detected in serovar bratislava-inoculated dogs.

Histologic examination and immunohistochemical analysis—Tissues from necropsies performed on PID 7, 10, 14, and 20 on serovar pomona-inoculated dogs had histologic lesions in liver, kidney, and lungs (Table 2). Lesions at PID 7 were subtle and confined to perivascular inflammation in the liver and multifocal interstitial nephritis. A single serovar pomona-infected dog had a focus of coagulative hepatic necrosis. On PID 10, there was pulmonary (Figure 4) and renal hemorrhage (Figure 5); coalescing interstitial nephritis; and heavier infiltrates of lymphocytes, plasma cells, and neutrophils in portal areas and around hepatic portal veins, relative to dogs necropsied on PID 7. On PID 14 and 20, multifocal renal hemorrhage was detected, interstitial nephritis was more intense (Figure 6), and hyaline droplets (Figure 7) were prominent in the tubular epithelium. Periportal inflammatory infiltrates of lymphocytes, plasma cells, neutrophils, and macrophages were thicker than previously; there were a few small foci of hepatic necrosis and multifocal bile plugs within bile canaliculi. Dilated proximal convoluted tubules with flattened epithelium and mineral deposits were evident at PID 20 only. Lesions that occurred less frequently in infected dogs were renal tubular syncytia, endocarditis and epicarditis, and focal pneumonia. In the heart, there were infiltrates of neutrophils and lymphocytes and fewer plasma cells around multifocal veins and arteries, subjacent to the endocardium, and within the epicardium and epicardial fat. In the lungs, groups of alveoli were filled and alveolar septa were expanded with free erythrocytes, serum, fibrin, degenerate neutrophils, and fewer lymphocytes and macrophages (Figures 8). In sections of perirenal fat examined from dogs with perirenal edema, there was necrosis of fat and heavy infiltrates of lymphocytes, plasma cells, neutrophils, and macrophages. Sections examined from the enlarged, reddened lymph nodes contained large numbers of free erythrocytes within the medulla. Erythrocytes often formed rosettes around macrophages or were within macrophages.

There was positive immunoreactivity to polyclonal antisera at the brush border of multifocal proximal convoluted tubules (Figure 9) and at the luminal surface of bile duct epithelium. The pattern of immunoreactivity was consistent with intact leptospires (Figure 10). There was a similar pattern of immunoreactivity

Table 1—Results (No. of positive results/No. of dogs tested) of bacteriologic culture and immunofluorescence testing in control dogs and dogs inoculated with 2 *Leptospira* serovars.

Variable	Culture								Immunofluorescence test		
	Blood PID 5	Blood PID 8	Blood PID 12	Blood PM	Kidney	Liver	Urine	AQ humor	Kidney	Liver	Urine
Control	0/4	0/3	0/2	0/4	0/4	0/4	0/4	0/4	0/4	0/4	ND
Serovar pomona	0/12	8/9	5/6	6/8	8/12	6/12	5/10	5/12	8/12	6/12	5/7
Serovar bratislava	0/11	0/9	0/6	0/11	0/11	0/11	0/11	0/11	0/11	0/11	0/10

PID = Postinoculation day. PM = Postmortem. AQ = Aqueous. ND = Not done.

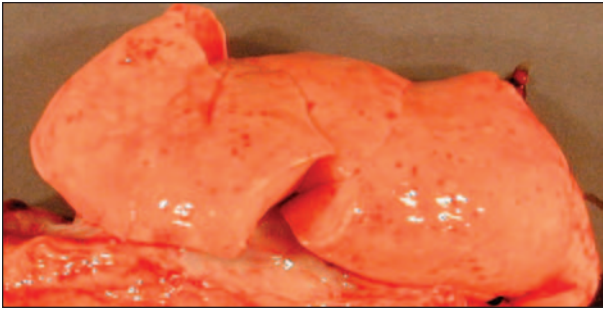


Figure 1—Photograph of the right lung of a dog inoculated 10 days previously with *Leptospira interrogans* serovar pomona strain RM 211. Notice petechial hemorrhages that have multifocally coalesced.

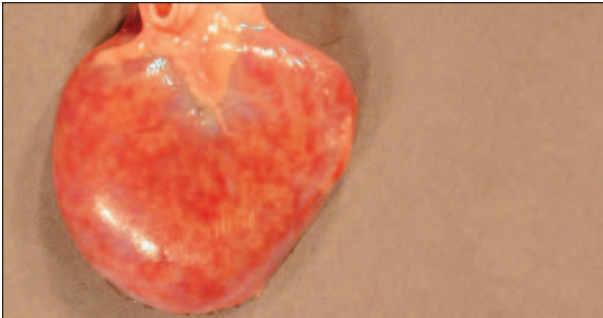


Figure 2—Photograph of the kidney of a dog inoculated 10 days previously with serovar pomona. Notice multifocal subcapsular hemorrhages.

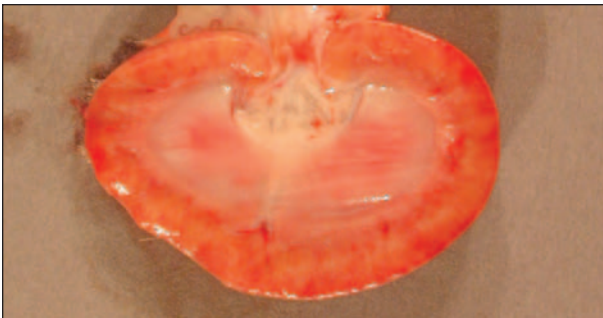

Figure 3—Photograph of the sagittal section of a kidney of a dog inoculated 10 days previously with serovar pomona. Notice multifocal irregularly shaped hemorrhages extending from the cortical surface to the corticomedullary junction.

in kidney with the anti-pomona antisera. In affected regions of lung, immunoreactivity with polyclonal antisera against serovar pomona was evident as leptospiral forms between bronchiolar epithelial cells and free within alveoli or as granular deposits within intra-alveolar phagocytes (Figure 11).

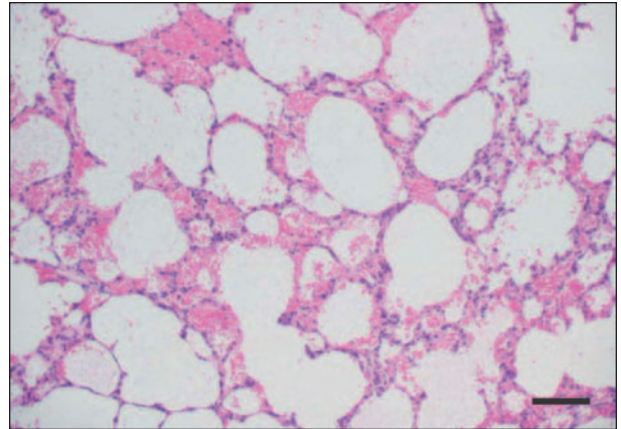


Figure 4—Photomicrograph of a section of lung from a dog inoculated 10 days previously with serovar pomona. Notice that many alveoli are filled with free erythrocytes. H&E stain; bar = 50 µm.

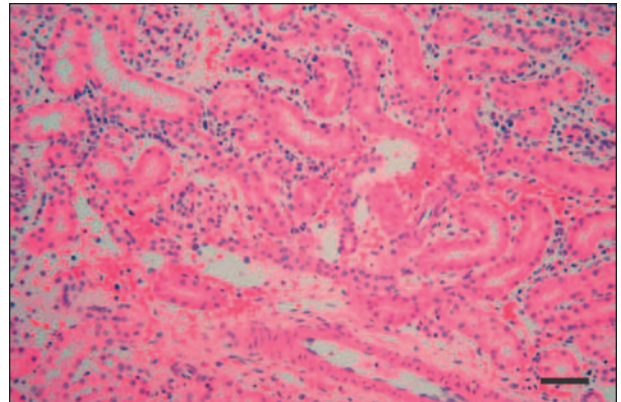


Figure 5—Photomicrograph of a section of kidney from a dog inoculated 10 days previously with serovar pomona. Notice that the interstitium is expanded by edema; free erythrocytes; and infiltrates of lymphocytes, plasma cells, and neutrophils. H&E stain; bar = 50 µm.

Table 2—Distribution (No. of dogs affected/No. of dogs necropsied) of major histologic lesions in kidneys and liver of dogs inoculated with serovar pomona and necropsied on various days after inoculation.

Day	Kidney			Liver	
	Interstitial nephritis	Tubular mineral	Tubular degeneration and dilation	Perivascular inflammation	Bile plugs
7	3/3 +	2/3 +	1/3 +	1/3 + 1/3 ++	3/3 –
10	1/3 + 2/3 +++	2/3 +	2/3 +	2/3 + 1/3 +++	3/3 –
14	3/3 +++	1/3 + 1/3 ++	1/3 ++ 1/3 +++	1/3 + 1/3 +	1/3 1/3 ++
20	1/3 ++ 1/3 +++	2/3 +	1/3 +++	1/3 +	1/3 +++

The number of addition symbols indicates the severity of the lesions.
– = No dogs had lesions.

Clinicopathologic examinations—Sporadic increases in BUN, anion gap, and bilirubin were detected only in serovar pomona-infected dogs. The BUN concentrations were increased in 2 dogs on PID 10 and a single dog on each of PID 14 and 20. There were not con-

comitant increases in creatinine concentration. Increases in Dbili, Tbili, GGT, and ALP were detected in 4 dogs on PID 14 and a single remaining dog (from this group of 4) that was necropsied on PID 20.

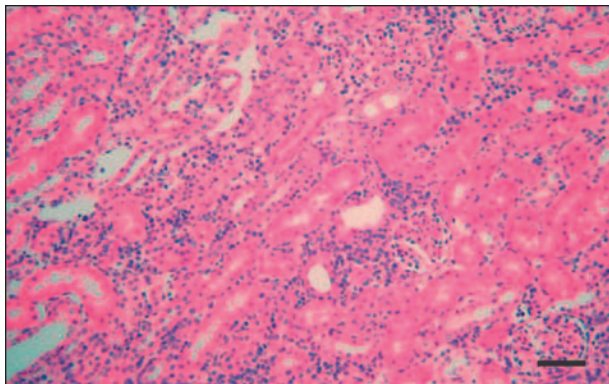


Figure 6—Photomicrograph of a section of kidney from a dog inoculated 20 days previously with serovar pomona. Notice that interstitial infiltrates are intense and composed primarily of plasma cells and lymphocytes. H&E stain; bar = 50 μ m.

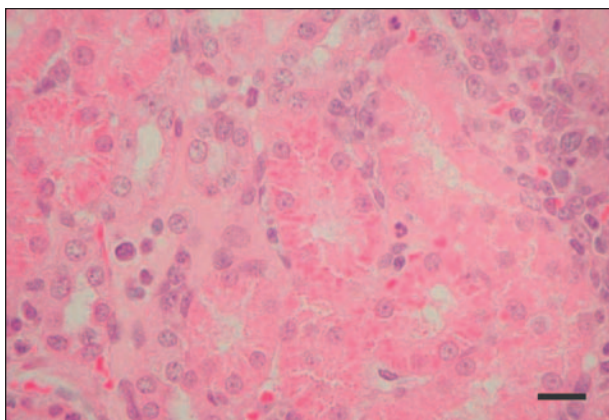


Figure 7—Photomicrograph of a section of kidney from a dog inoculated 20 days previously with serovar pomona. Notice that hyaline droplets are abundant in proximal convoluted tubular epithelial cells. H&E stain; bar = 20 μ m.

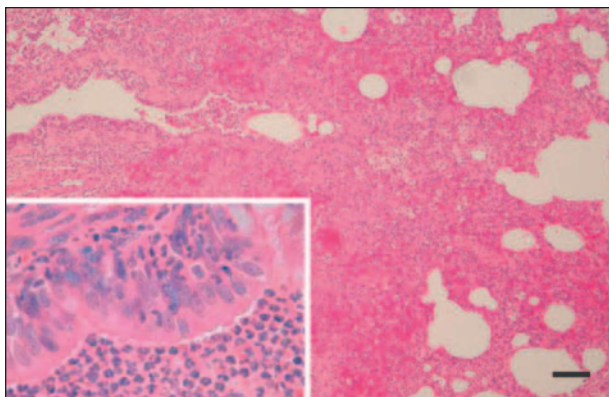


Figure 8—Photomicrograph of a section of lung from a dog inoculated 20 days previously with serovar pomona. Notice that alveoli and bronchioles are filled with degenerate neutrophils, macrophages, erythrocytes, and serum. Similar infiltrates expand alveolar septa. Unaffected alveoli are overinflated. Inset: High magnification of bronchiolar epithelium and lumen. H&E stain; bar = 20 μ m.

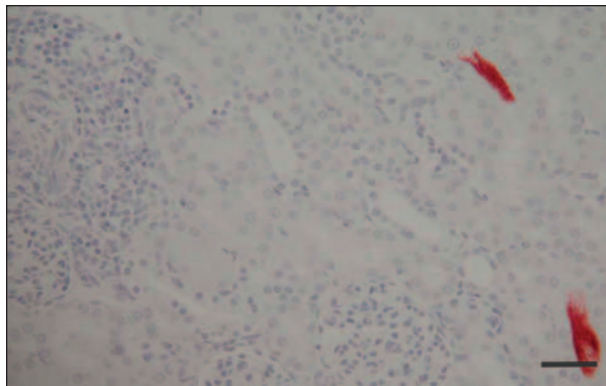


Figure 9—Immunohistochemical staining of a section of kidney from a dog inoculated 20 days previously with serovar pomona. Notice immunoreactivity with polyclonal antibody (antisera to OmpL1) within multiple proximal tubules but not within foci of interstitial inflammation. Bar = 50 μ m.

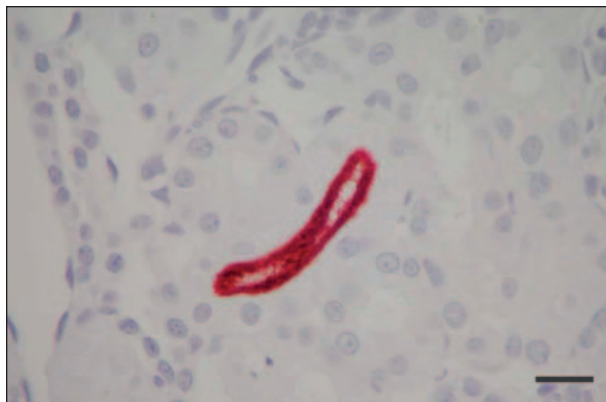

Figure 10—Higher magnification of the immunohistochemical staining in Figure 8. Notice that intense immunoreactivity to leptospiral antigens is associated with organisms attached to the microvillous surface of the proximal convoluted tubule. Bar = 20 μ m.

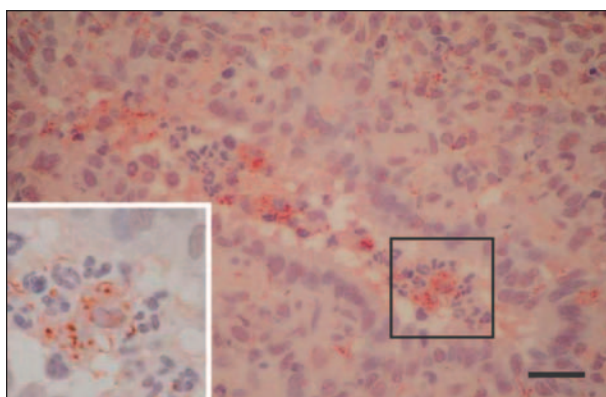


Figure 11—Immunohistochemical staining of a section of lung serial to that in Figure 8. Notice that in affected regions of lung, immunoreactivity with polyclonal antisera against serovar pomona was evident as leptospiral forms between bronchiolar epithelial cells and free within alveoli or as granular deposits within intra-alveolar phagocytes. Inset: High magnification view of granular debris within macrophages. H&E stain; bar = 20 μ m.

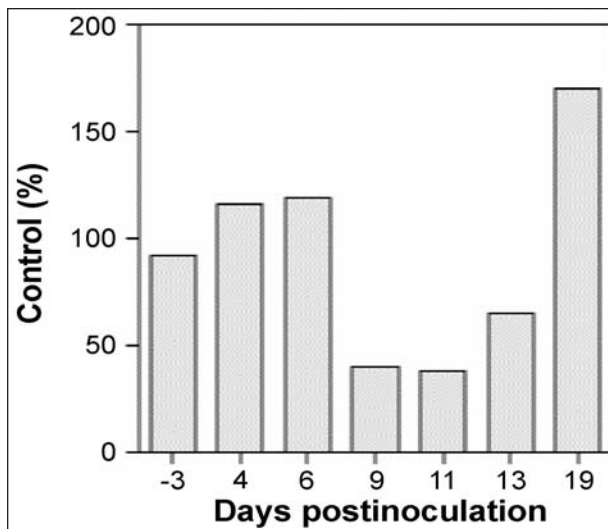


Figure 12—Mean platelet counts (percentage of control values) of dogs inoculated with serovar pomona. Notice a transient decrease in platelet counts at postinoculation days 9 to 13, when dogs were clinically ill.

Increases in serum ALP activity ranged from 834 U/L to 1,413 U/L (reference interval, 20 to 115 U/L). Platelet concentrations from dogs with positive results of culture were decreased from baseline values on PID 9, 11, and 13 (Figure 12). A single serovar pomona-inoculated dog had a slightly prolonged partial thromboplastin time on PID 10 (21.1 seconds; reference interval 8.9 to 18.7 seconds). On PID 14, 2 serovar pomona-inoculated dogs had glucose (+) and bilirubin (3+) in the urine. Significant differences for other variables in serovar pomona-inoculated dogs, including leukocyte count, were not detected. Results from CBC and serum biochemical profiles in serovar bratislava-inoculated dogs did not differ from control dogs.

Serologic testing—No MAT titer > 1:100 was detected in any serovar bratislava-inoculated dog. Two serovar pomona-inoculated dogs had MAT titers of 1:200 and 1:800, respectively, at PID 20. No other agglutinating antibody titers \geq 1:25 were detected in any dogs.

Discussion

Several diagnostic methods were used to confirm leptospiral infection, and infection was confirmed in 11 of 12 serovar pomona-inoculated dogs. Bacteriologic culture of blood was the most sensitive method of detecting infection by serovar pomona at PID 7 or 8. The PCR samples collected at the PID 7 necropsies yielded negative results, but PCR assay was attempted on renal tissue only. Neither PCR assay nor immunofluorescence testing results were positive until PID 10, 3 days after the onset of clinical signs. The PCR assay was not attempted on blood samples but may be indicated in clinical cases in which waiting weeks for a bacteriologic blood culture result limits the usefulness of culture in the diagnosis of acute cases. Only 1 dog had an MAT titer that would be diagnostic for leptospirosis by use of published standards of 1:800

to 1:3,200 used in retrospective studies.^{14,15} At PID 20, 1 serovar pomona-inoculated dog had an MAT titer of 1:200 and another had a titer of 1:800. Tissues and fluids from a single dog necropsied on PID 20 did not yield positive results by use of any of the detection methods, despite being inoculated on 3 consecutive days and being housed with a clinically ill cagemate with detectable leptospires in blood, tissues, and urine. Furthermore, this dog did not have a detectable titer by use of MAT before or after inoculation.

Detection of hemorrhage was supported by gross, histopathologic, and clinical pathologic data. Hemorrhage in serovar pomona-infected dogs was associated with sporadic increases in BUN concentration not accompanied by increases in creatinine concentration, which suggested gastrointestinal tract hemorrhage with absorption of blood.²⁸ One of the dogs with increased serum BUN concentration had loose feces with flecks of blood prior to necropsy at PID 10. A second dog with increased BUN concentration had large amounts of digested blood within the intestine at necropsy.

Renal lesions were evident in all serovar pomona-infected dogs. Interstitial nephritis increased in severity over time, but was not associated with indicators of renal failure, as it was with inoculation of dogs with *L. kirschneri* serovar grippotyphosa.²⁵ Because most infected dogs had serum BUN and creatinine concentrations within the reference intervals, > 25% of renal function remained, but that did not exclude the possibility of renal disease. Hyaline droplets in the proximal convoluted tubules, formed when resorption by the cell outpaces the digestion of protein during pinocytotic vesicle fusion with lysosomes, suggested plasma protein leakage from abnormal glomerular capillaries or abnormal protein processing by tubular epithelium. Glucosuria without hyperglycemia, which occurred in 2 dogs at PID 14, may have further suggested a renal tubular dysfunction.

Clinical pathology data and histopathologic examination in severely affected dogs were consistent with cholestasis on PID 14 and 20. Increased Tbili and Dbili concentrations and substantially increased serum activity of ALP were detected in 4 dogs, and these abnormalities were associated with histologic evidence of dense perivascular infiltrates of lymphocytes, plasma cells, macrophages, and neutrophils in portal areas; bile plugs in bile canaliculi; and multifocal areas of hepatic necrosis that corresponded to multifocal raised white areas noted grossly. Increased ALP activity also can occur in young, growing animals because of induction of the ALP bone isoenzyme; however, the greatest magnitude of increase in ALP was associated with liver lesions.

Serovar bratislava infection was not confirmed in any dog by use of immunofluorescence testing, bacteriologic culture, immunohistochemistry, or PCR assay. The inability of this canine-derived isolate to cause disease in dogs may be the result of changes in expression of virulence factors caused by passage in culture. The organisms grew rapidly in culture, indicating adaptation to culture conditions that often is associated with loss of virulence.²⁹ Infection with serovar bratislava has

been associated with reproductive failure or renal disease in dogs in Great Britain.^{30,31} Failure of this isolate to cause disease in dogs does not imply that all isolates of serovar bratislava are unable to cause disease in dogs because different strains can have substantial differences in virulence factors. Perhaps an isolate from another host would be suitable as a more effective canine challenge organism.

Dogs infected with serovar pomona had unique clinical signs, clinicopathologic abnormalities, and lesion patterns, compared with dogs infected with *L. kirschneri* serovar grippotyphosa.²⁵ Serovar grippotyphosa infection causes severe renal and hepatic failure resulting in severe serum biochemical abnormalities and death by PID 12. Serovar pomona-infected dogs frequently had evidence of hemorrhage in lung and kidney, but fewer serum biochemical abnormalities, although histopathologic lesions in kidney were more severe than those in serovar grippotyphosa-infected dogs.

- a. Marshall Farms, North Rose, NY.
- b. PLM 5, Intergen Co, Purchase, NY.
- c. DNeasy tissue kit, Qiagen, Valencia, Calif.
- d. Monoclonal antibody No. 338, Dr. Rudy Harskeerl, Royal Tropical Institute, Amsterdam, The Netherlands.
- e. Bovine serum albumin, Sigma Chemical Co, St Louis, Mo.
- f. Fisher Chemicals, Fairlawn, NJ.
- g. NBS, donkey, Vector Laboratories Inc, Burlingame, Calif.
- h. Donkey anti-mouse or donkey anti-rabbit, Jackson ImmunoResearch Laboratories Inc, West Grove, Pa.
- i. Vector Elite ABC Kit, 1:600, Vector Laboratories Inc, Burlingame, Calif.
- j. Nova Red, Vector Laboratories Inc, Burlingame, Calif.

References

1. Yang CW, Wu MS, Pan MJ. Leptospirosis and renal disease. *Nephrol Dial Transplant* 2001;16(suppl 5):73–77.
2. Bolin CA. Diagnosis of leptospirosis: a reemerging disease of companion animals. *Semin Vet Med Surg (Small Anim)* 1996;11:166–171.
3. Ward MP, Glickman LT, Guptill LF. Prevalence of and risk factors for leptospirosis among dogs in the United States and Canada: 677 cases (1970–1998). *J Am Vet Med Assoc* 2002;220:53–58.
4. Navarro CE, Kociba GJ, Kowalski JJ. Serum biochemical changes in dogs with experimental *Leptospira interrogans* serovar icterohaemorrhagiae infection. *Am J Vet Res* 1981;42:1125–1129.
5. Navarro CE, Kociba GJ. Hemostatic changes in dogs with experimental *Leptospira interrogans* serovar icterohaemorrhagiae infection. *Am J Vet Res* 1982;43:904–906.
6. Monlux W. Leptospirosis. III. The clinical pathology of canine leptospirosis. *Cornell Vet* 1948;38:109–121.
7. Monlux W. Leptospirosis. IV. The pathology of canine leptospirosis. *Cornell Vet* 1948;38:199–208.
8. McIntyre WIM, Montgomery GL. Renal lesions in *Leptospira canicola* infection in dogs. *J Pathol Bact* 1952;64:145–160.
9. Taylor PL, Hanson LE, Simon J. Serologic, pathologic, and immunologic features of experimentally induced leptospiral nephritis in dogs. *Am J Vet Res* 1970;31:1033–1049.
10. Low DG, Hiatt CW, Gleiser CA, et al. Experimental canine leptospirosis. I. *Leptospira icterohaemorrhagiae* infections in immature dogs. *J Infect Dis* 1956;98:249–259.
11. Low DG, Bergman EN, Hiatt CW, et al. Experimental canine leptospirosis. II. Renal function studies. *J Infect Dis* 1956;98:260–265.
12. Adin CA, Cowgill LD. Treatment and outcome of dogs with leptospirosis: 36 cases (1990–1998). *J Am Vet Med Assoc* 2000;216:371–375.
13. Kalin M, Devaux C, DiFrancia R, et al. Three cases of canine leptospirosis in Quebec. *Can Vet J* 1999;40:187–191.
14. Birnbaum N, Barr SC, Center SA, et al. Naturally acquired leptospirosis in 36 dogs: serological and clinicopathological features. *J Small Anim Pract* 1998;39:231–236.
15. Rentko VT, Clark N, Ross LA, et al. Canine leptospirosis. A retrospective study of 17 cases. *J Vet Intern Med* 1992;6:235–244.
16. Boutilier P, Carr A, Schulman RL. Leptospirosis in dogs: a serologic survey and case series 1996 to 2001. *Vet Ther* 2003;4:178–187.
17. Cole JR, Sulzer CR, Pursell AR. Improved microtechnique for the leptospiral microscopic agglutination test. *Appl Microbiol* 1973;25:976–980.
18. Thiermann A, McClellan R, Hill H. Improved techniques for the isolation of leptospires from swine abortion cases, in *Proceedings*. 27th Annu Meet Am Assoc Vet Lab Diagnosticians 1984;233–244.
19. Nielsen JN, Cochran GK, Cassells JA, et al. *Leptospira interrogans* serovar bratislava infection in two dogs. *J Am Vet Med Assoc* 1991;199:351–352.
20. Ellis WA, Montgomery J, Cassells JA. Dihydrostreptomycin treatment of bovine carriers of *Leptospira interrogans* serovar Hardjo. *Res Vet Sci* 1985;39:292–295.
21. Johnson RC, Harris VG. Differentiation of pathogenic and saprophytic leptospires. I. Growth at low temperatures. *J Bacteriol* 1967;94:27–31.
22. Thiermann AB, Handsaker AL, Foley JW, et al. Reclassification of North American leptospiral isolates belonging to serogroups Mini and Sejroe by restriction endonuclease analysis. *Am J Vet Res* 1986;47:61–66.
23. Zuerner RL, Bolin CA. Differentiation of *Leptospira interrogans* isolates by IS1500 hybridization and PCR assays. *J Clin Microbiol* 1997;35:2612–2617.
24. Bolin CA, Thiermann AB, Handsaker AL, et al. Effect of vaccination with a pentavalent leptospiral vaccine on *Leptospira interrogans* serovar hardjo type hardjo-bovis infection of pregnant cattle. *Am J Vet Res* 1989;50:161–165.
25. Greenlee JJ, Bolin CA, Alt DP, et al. Clinical and pathologic comparison of acute canine leptospirosis caused by two strains of *Leptospira kirschneri* serovar grippotyphosa. *Am J Vet Res* 2004;65:1100–1107.
26. Shang ES, Exner MM, Summers TA, et al. The rare outer membrane protein, OmpL1, of pathogenic *Leptospira* species is a heat-modifiable porin. *Infect Immun* 1995;63:3174–3181.
27. Wild C, Greenlee J, Bolin C, et al. An improved immunohistochemical diagnostic technique for canine leptospirosis using anti-leptospiral antibodies on renal tissue. *J Vet Diagn Invest* 2002;14:20–24.
28. Prause LC, Grauer GF. Association of gastrointestinal hemorrhage with increased blood urea nitrogen and BUN/creatinine ratio in dogs: a literature review and retrospective study. *Vet Clin Pathol* 1998;27:107–111.
29. Thiermann AB. Effect of cyclophosphamide treatment on clinical and serologic response of rats to infection with *Leptospira interrogans* serovar icterohaemorrhagiae. *Am J Vet Res* 1980;41:1655–1658.
30. Thomas S. Leptospirosis apparently due to *Leptospira bratislava* in a dog. *Vet Rec* 1980;106:178–179.
31. van den Broek AHM, Thrusfield MV, Dobie GR, et al. A serological and bacteriological survey of leptospiral infection in dogs in Edinburgh and Glasgow. *J Small Anim Pract* 1991;32:118–124.