

# The Management of Long Bone Fractures in Birds

Michael L. Westfall\*  
Erick L. Egger, DVM†

This paper will discuss difficulties and problems in the management of avian fractures. It will deal with both open and closed reduction of long bone fractures.

## *Introduction*

Exotic animal medicine and surgery pose interesting problems for the average practitioner; however, with the increased popularity of these exotic animals as pets, the veterinarian will be called upon more and more to practice medicine on and render aid to these animals. Over the past few years, birds have been among the more rapidly growing sectors of the exotic pet population. Fanciers have a gambit of sizes ranging from finches and budgerigars to falcons. The chance may also arise when hawks, owls or even eagles are brought into your clinic for rehabilitation. This paper will deal with the special considerations and methods of avian orthopedics.

## *Basic Principles of Fracture Repair in Birds*

The classical objectives of healing in avian orthopedics are the same as those in mammalian orthopedics: 1) rigid fixation, 2) good alignment, 3) good apposition, 4) asepsis, and 5) early return to function.<sup>8,15</sup> It is also very necessary to maintain length of the bones in birds due to balance of the animal and the special mechanics of flight.<sup>15</sup>

Attaining these classical objectives is no easy task in birds. Molting, a yearly occurrence in most birds, causes an increase in the susceptibility of the long bones to frac-

ture. This functional "osteoporosis" is due to an enlargement of the Haversian systems.<sup>1</sup> As the vascularity of the bones decrease the healing time increases.<sup>2,4</sup> This problem is especially pronounced in humeral and femoral fractures. The callus in bird fractures forms primarily on the inside of the bone. This gives excellent stability and reduces healing time but also reduces the efficacy of intramedullary devices for fracture repair.<sup>8</sup>

Probably the most common complication in healing of avian fractures is sepsis.<sup>3,15</sup> The small muscle mass and thin skin give rise to frequent compound fractures—especially of the wings. Osteomyelitis, which is a common problem in mammals, is relatively rare in birds, presumably due to their increased body temperature.<sup>2,13</sup> However, compound fractures involving the humerus and femur leave an open path into the air sacs and air sacculitis may be seen.<sup>15</sup>

Some mention should be made as to the most common cause of fractures in small caged birds. Elongated, curled toenails are often caught in cage bars or wire floors when the bird is startled into flight.<sup>3,11</sup> Most of these fractures are in the tarsus or tibiotarsal area and can easily be identified by crepitus, abnormal angling and exceptional mobility.<sup>4</sup> The biggest differential diagnoses in avian fractures are bone tumors, easily identified by their lack of pain.<sup>4</sup>

It can be said that often times the orthopedic procedure is successful but the bird dies as a result of stress associated with the injury, anesthesia or surgery.<sup>10</sup> The most serious of these is the risk of anesthesia. Before surgery is attempted it should be recalled that gas exchange occurs during exhalation (while the gas is passed from the air sacs into the lungs and trachea) and *not* on inspiration as in mammals; thus there is a lag time for resuscitation and anesthesia while

\*Mr. Westfall is a fourth year student in the College of Veterinary Medicine, ISU.

†Dr. Egger is an Associate Professor of Veterinary Clinical Sciences, Small Animal Surgery Section, College of Veterinary Medicine, ISU.

using gas anesthetics.<sup>8</sup> The problem of maintaining body heat in birds over lengthy procedures is an often encountered problem. The commonly available plates, screws and pins utilized for fracture fixation are usually too big and too heavy for all but the largest psitticines and raptors.<sup>6</sup> Not the least of the surgical problems are the lack of adequate interest by veterinarians and appropriate reference materials.<sup>6,10</sup>

In caged birds, the demand for accuracy of wing and leg function are not as pronounced as in the raptors and larger birds that depend on their wings for survival. In raptors, limbs must function effectively since they are not designed with any method of acclimation for other than very slight conformational changes. If malunion or reduction of a few degrees in range of joint motion occurs the bird can never perform at his previous level.<sup>15</sup> Angulation and instability cannot be tolerated unless the bird is relegated to a "show bird" status in the local zoological park.

#### **External Fixation**

External fixation is very practical for small caged birds such as canaries and budgerigars. Materials needed can be found in almost every veterinary practice or can be improvised from simple household supplies.

Fractures of the tibiotarsus and tarsometatarsus (TMT) comprise well over 65% of the fractures in canaries and budgerigars.<sup>1,14</sup> These can easily be repaired by having an assistant hold the bird in dorsal recumbancy with the legs facing the veterinarian. The fractured leg can then be grasped by the toe and held upright. Three to four layers of  $\frac{1}{2}$  to  $\frac{3}{4}$  inch adhesive tape should be wrapped loosely around the fracture site. Plenty of tape should be left anteriorly and posteriorly so that heavy hemostats may be used to compress this tape into flaps<sup>2</sup> (Fig. 1). This anterior-posterior flapping gives advantages to the bird when it roosts during healing. Some birds will require Elizabethian collars and/or flesh colored tape to prevent them from picking at the tape. Additional support may be rendered by incorporating matchsticks, split quills, paper clips, cardboard or small wires.

Fractures of the middle third of the TMT should be fixed in full extension without involvement of the proximal or distal joints.

Fractures of the distal third of the TMT should be fixed by applying an anchor strip under the foot to above the fracture line. Routine use of the tape follows to complete this splint. Fractures involving the proximal third of the TMT should be fixed in a flexed state ( $75$  to  $90^{\circ}$ <sup>1,4</sup>) at the tibiotarsal joint. The feathers should be plucked so that the tape adheres better.<sup>1,4,11,12</sup>

Fiberglass has been used for support when it was felt that a cast was required. Fiberglass has the advantages of light weight and better tolerance by the bird as opposed to plaster casts.<sup>2,4</sup> Casts are applied in roughly the same manner as mammalian orthopedics.

Wing fractures in small caged birds are less common, but often cause many problems associated with healing. The ideal method of immobilization is to gently fold both wings into a "normal" resting position and use 3 strips of  $\frac{3}{4}$  to one inch tape, 6 to 8 inches long, around the wings and the body.<sup>2,4</sup> One strip of tape goes around both carpal regions, one around the elbow joints and the last strip is used to counterbalance around the tips of the carpophalangeal feathers.<sup>1,2,4</sup> In larger birds padding and aluminum splints may be used effectively under the fractured wing.<sup>11</sup> Care must be taken to avoid compressing the sternum and the cloaca.<sup>15</sup>




Fig. 1. Adhesive tape has been wrapped loosely around the fracture site. Heavy hemostats have been applied anteriorly and posteriorly to strengthen the tape "splint."

Half-pin and full-pin splintage (Kirschner devices) have been used successfully in medium and large birds with long bone fractures of the wings and legs (Fig. 2). Advantages of these devices include rigid fixation without prolonged surgery time and good tolerance by the bird.<sup>8</sup> The only instrumentation required is a hand chuck or small hand drill and small Steinman pins (2.03mm). Care should be taken to avoid splintering the relatively thin cortices of larger birds. Aftercare is the same as with mammalian Kirschner devices.

### Internal Fixation

Internal fixation may be used for fracture management in both medium and large birds in much the same manner as mammals. The major problem involves the lack of appropriate sizes of pins, screws and plates. Most of these were developed for human or small animal use. Consequently, their size and weight are prohibitive, except for the larger raptors. Other problems associated with internal fixation include providing adequate

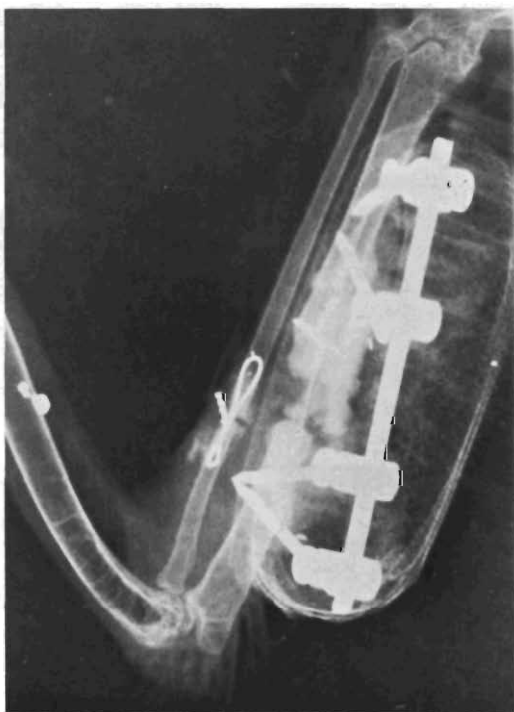


Fig. 2. A half-pin Kirschner device has been applied to the right ulna of a red tail hawk. An interfragmentary wire has been placed in the radius fracture.

exposure, minimal sepsis and articulation insult.<sup>15</sup>

In small birds K-wires or 18 to 26 gauge hypodermic needles may be used for intramedullary pinning.<sup>11-13,17</sup> Care must be taken when installing these, as small bones tend to splinter very easily.<sup>1,12</sup>

Steinman pins may be used for retrograde pinning of the humerus but seem to be of more value in ulnar fractures when the radius is also fractured. Two distinct disadvantages of all intramedullary pins are the lack of dense bone in the metaphyseal region of the bones and the presence of very fine boney trabeculae throughout the length of the bone. These allow for pin migration and rotational instability around the pin at the fracture site.<sup>4,8</sup> Another disadvantage involves the use of Steinman pins which are slightly tight in the marrow cavity. The thin cortices of the avian bone tend to fissure fracture quite readily. If this is the case, a slightly smaller pin should be used in conjunction with devices to prevent rotation. Cerclage wires can easily be applied to prevent the fissure fractures from extending. Finally, pins tend to extend into joints and result in stiffness, severely limiting the ability of the bird to perform (Fig. 3).

Leg fractures are more readily adaptable to the use of plates and screws. The cortices are relatively thicker and do not splinter as readily.<sup>15</sup> ASIF<sup>a</sup> or Richards<sup>b</sup> plates have been used in eagles and hawks.<sup>7,15,18</sup> Disadvantages of plating include: brittle cortex, longer anesthesia and a larger opening of the fracture site.<sup>8</sup> The biggest advantage is rotational stability.

Some of the new acrylic bone cements have been used for fixation. The most common of these, polymethylmethacrylate (PMMA), used frequently in total hip replacement, has been advocated because of its light weight, less need for follow up and immediate normal positioning of the fractured bones.<sup>6</sup> PMMA is a luting agent which forms a mechanical (frictional) bond when forced into the interstices of bone.<sup>6</sup> PMMA has been mixed with various antibiotics to provide local treatment of infection.

Two methods have been used. The first involves predrilled holes proximal and distal to the fracture line. The fracture is then

<sup>a</sup>Synthes, Ltd. Wayne, PA.

<sup>b</sup>Richards Manufacturing Co., Inc. Memphis, TN.

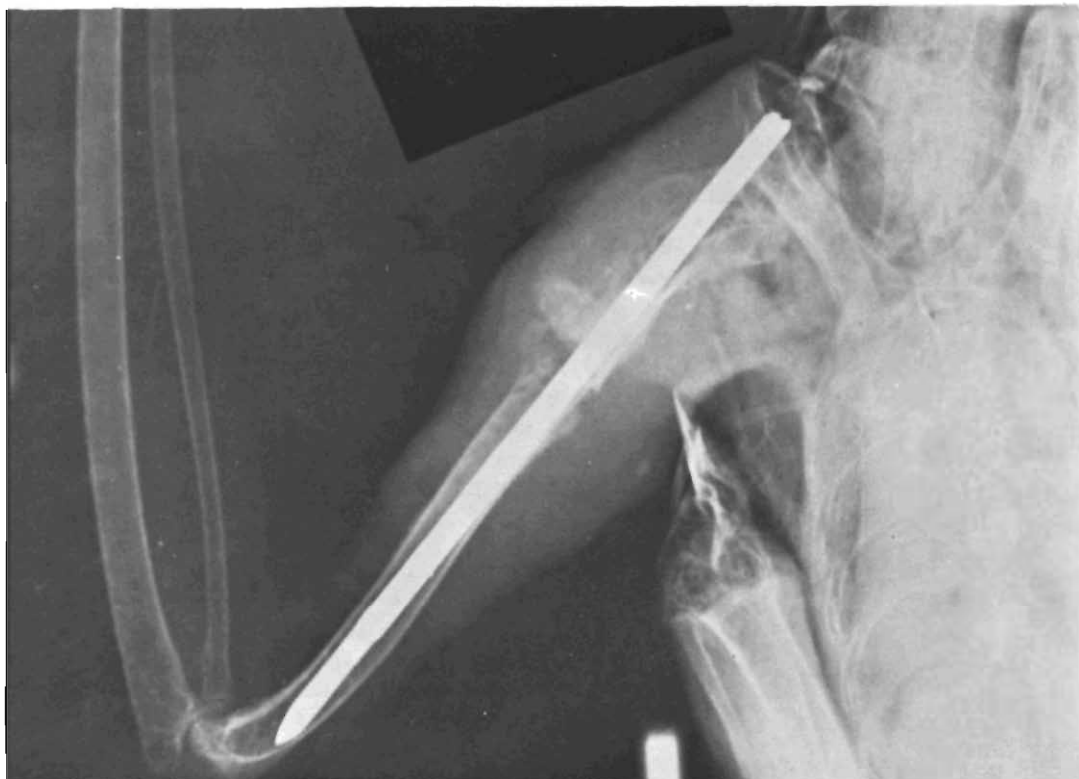

Fig. 3. A Steinman intramedullary pin was placed into the right humerus of this hawk. Notice the

rotational instability of the fracture site and the insult at the scapulohumeral articulation.

reduced and the PMMA is mixed and loaded into a syringe while in the paste stage. The PMMA is then injected into the marrow cavity through these holes. This method allows the PMMA to act as a lightweight "Steinman pin."<sup>6</sup>

The second method involves the use of PMMA and full cerclage wires. PMMA is mixed to a hard paste stage and then is incorporated into the wire twists proximal and distal to the fracture site. In this method the PMMA acts as a neutralization plate, thereby increasing rotational stability markedly. It can be used equally well in both wing and leg fractures (Fig. 4).

### Summary

The basic principles of fracture fixation are the same in birds and mammals. External fixation can be accomplished with simple facilities and supplies. Internal fixation can be performed with only minor changes from mammalian internal fixation. Common sense judgment should be applied whenever the veterinarian is working with exotic animals.

### References

1. Altman, I. E.: Disorders of the skeletal system, in Petrak, M. L. (ed.): *Diseases of Caged and Aviary Birds*. Philadelphia, Lea & Febiger, 1969, pp. 257-262.
2. Altman, R. B.: Fractures of the extremities of birds, in Kirk, R. W. (ed.): *Current Therapy VI*. Philadelphia, W. B. Saunders Co., 1977, pp. 717-720.
3. Amand, W. B.: General techniques in avian surgery, in Kirk, R. W. (ed.): *Current Therapy VI*. Philadelphia, W. B. Saunders Co., 1977, pp. 715-716.
4. Arnall, L., Keymer, I. F.: *Bird Diseases*. London, Bailliere-Tindall, 1975, pp. 408-413.
5. Borman, E. R., Putney, D. L.: Repair of a wing fracture with methylmethacrylate bone cement. *VMSAC* 73:794, 1978.
6. Borman, R. R., Putney, D. L., Jessup, D.: Use of acrylic bone cement in avian orthopedics. *JAAHA* 14:602-604, 1978.
7. Brueck, V. L.: Achilles—The golden eagle with the crippled leg. *Pract. Vet.* 46(5):14-15, 1974.
8. Bush, M.: External fixation of avian fractures. *JAVMA* 171:943-946, 1977.
9. Bush, M., Hughes, J. L., Ensley, P. K., James, A. E.: Fracture repair in exotics using internal fixation. *JAAHA* 12:746-753, 1976.
10. Bush, M., James, A. E.: Some considerations of the practice of orthopedics in exotic animals. *JAAHA* 11:587-594, 1975.

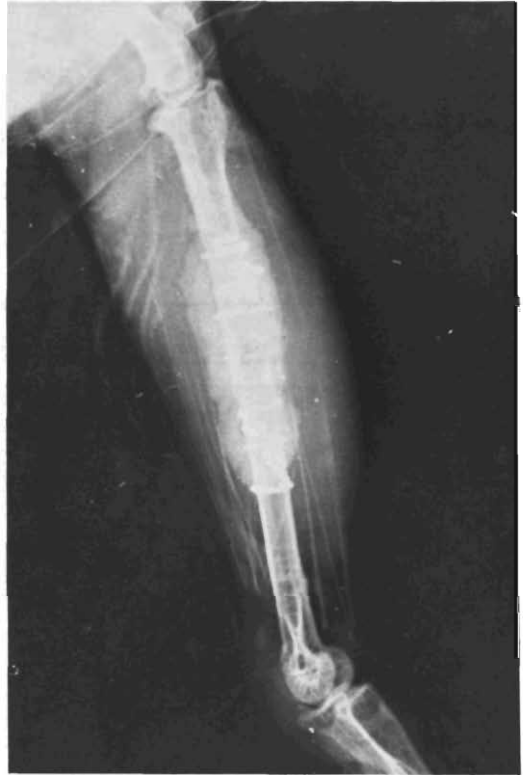
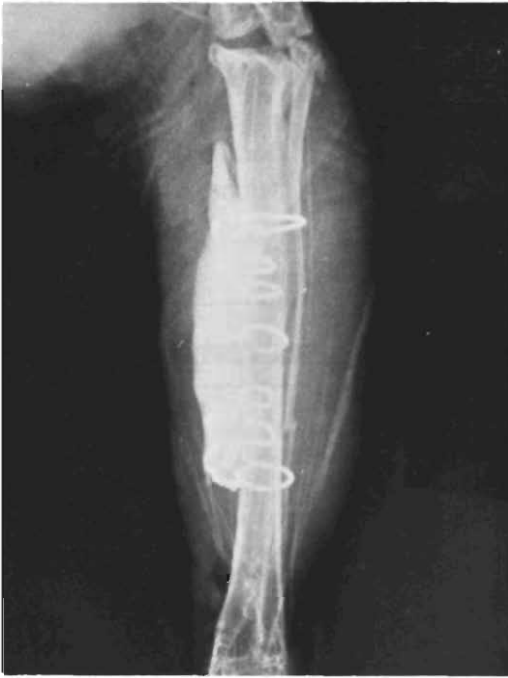
Fig. 4. AP and lateral views of a great horned owl tibia repaired using PMMA and cerclage wires. All the twists of the wires were imbedded into the PMMA.

11. Gandal, C. P.: Surgical techniques and anesthesia, in Petrak, M. L. (ed.): *Diseases of Caged and Aviary Birds*. Philadelphia, Lea & Febiger, 1969, pp. 227-230.
12. Graham, D. L.: *Caged Birds, Their Management and Care*. Ames, ISU Press, 1975, p. 39.
13. Mandrill, D. N.: Internal fixation in the treatment of fractures in birds. *Vict. Vet. Proc.* 1975, p. 18.
14. Raises, M. B.: External fixation in the treatment of fractures in birds. *Vict. Vet. Proc.* 1975, pp. 17-18.
15. Redig, P., Roush, J. C.: Orthopedic and soft tissue surgery, in Fowler, M. E. (ed.): *Zoo and Wild Animal Medicine*. Philadelphia, W. B. Saunders Co., 1978, pp. 247-251.
16. Silver, I. A.: Tissue adhesives. *Vet. Rec.* 98:405-406, 1976.
17. Wallach, J. D.: Surgical techniques for caged birds. *Vet. Clin. NA* 3(2):232-233, 1973.
18. Wingfield, W. E., DeYoung, D. W.: Anesthetic and surgical management of eagles with orthopedic difficulties. *VMSAC* 67:991-993, 1972.

## PREGNANCY DIAGNOSIS FOR MARES

*45th to 150th day. Require at least 25 cc blood serum per test, 50 cc better. Obtain 200 to 250 cc blood. Keep cool, avoid contamination. Use ice packets to ship in hot weather. Write for sterile vials and instructions. \$15 per test.*

*Pregnancy Diagnostic  
Laboratories  
Dysart, Iowa 52224  
Ph: (319) 476-7000*