

***Dictyocaulus Viviparus* in an Iowa Dairy Cow**

Khaled Al-Qudah D.V.M, Ph.D.,*

John H. Greve D.V.M., Ph. D.,** Wallace M. Wass D.V.M., Ph. D. ***

Summary

Dictyocaulus viviparus, the lungworm of cattle, is not commonly diagnosed as a clinical entity in cattle native to Iowa. The parasite is sporadically distributed throughout North America, however, and cases do occasionally occur in the upper Midwest with serious clinical consequences and apparent overwintering of the larval forms. Lungworm infection should be considered as a diagnostic possibility in cases of chronic respiratory disease that do not respond to therapy for other types of infection. The disease can be diagnosed by identifying larval forms in feces by the Baermann technique or by finding adults in the respiratory system at necropsy. A field case from an Iowa dairy herd is described.

History and Clinical Events

A three-year-old Holstein cow in extremely poor body condition was admitted to the Iowa State University Veterinary Teaching Hospital. The clinical history indicated that the animal had calved three weeks previously and was from a milking herd of approximately 35 pasture-fed cows. The animals were said to have been home raised. Several other animals in the herd were described as being in poor condition as well. This animal was recumbent and dyspneic at the time of admission. Physical examination revealed a mastitic left front quarter and an abnormal uterine discharge. Auscultation of the thorax revealed prominent rales with crackles and wheezes. The animal was dehydrated with an estimated 10% loss of body fluid.

*Khaled Al-Qudah is a visiting Postdoctoral Associate in the Department of Veterinary Clinical Sciences, Iowa State University.

**Dr. John Greve is a faculty member in the Department of Veterinary Pathology, Iowa State University.

***Dr. Wallace Wass is a faculty member in the Department of Veterinary Clinical Sciences, Iowa State University.

Initial therapy consisted of intravenous administration of 32 liters of balanced electrolyte solution containing added calcium gluconate and glucose. Fifteen ml of Banamine and 15 ml of Naxcel were given subcutaneously. The animal died approximately twelve hours after admission.

The most striking observation at necropsy, was that the trachea and bronchi were filled with mature forms of *Dictyocaulus viviparus*. Thick inflammatory exudate surrounded the parasites and caused airway obstructions (Fig 1).

Dictyocaulus viviparus, the lungworm of cattle, is usually associated with geographic areas of high moisture and moderate temperatures, but it is sporadically distributed throughout North America². It is not common to see lungworm infection in Iowa cattle. Records of the Iowa Veterinary Diagnostic Laboratory indicate only five cases of *Dictyocaulus viviparus* in cows during the past three years (1992 - 1994). Cases within the experience of the authors have usually involved the movement of infected animals from more southern regions, where lungworms tend to be an endemic problem. The parasite is known to overwinter on pasture, in England⁵ and Canada⁶ and apparently also in mideastern and midwestern states in the U.S., but studies on this have been inconclusive. Larval forms may survive relatively low temperatures but may also be less able to infect cattle as a result³. It is probable that Iowa winter conditions, along with other management factors common to the region, serve to limit the spread of this parasite. Several anthelmintic drugs, including albendazole fenbendazole, oxfenbendazole, ivermectin and levamisole, are effective against lungworms but are not approved for use in lactating dairy animals.

The life cycle

Dictyocaulus viviparus has a direct life cycle. Female worms in the bronchi (Fig. 1) produce embryonated eggs which are coughed up and swallowed. The eggs hatch, and the first-

stage larvae pass through the alimentary canal. When voided in feces the larvae are active. During the grazing season most of them reach the surface of the fecal pat shortly after it is deposited and the pasture grass becomes contaminated. When cattle ingest the grass the infective larvae are stimulated by exposure to bile in the small intestine and penetrate the gut wall.⁴ The larvae enter the lymphatic system of the gut and pass through the thoracic duct, the heart, the cranial vena cava, and then reach the lungs via the arteries about one week after ingestion. They reach maturity three to four weeks after ingestion. The first larvae may be found in the feces twenty-one days after infection.³

Diagnosis

The larvae of *Dictyocaulus viviparus* are the only nematode larvae found in freshly voided cattle feces uncontaminated with soil, so the demonstration of free larvae in such feces justifies a diagnosis of lungworm infection. The larvae may be found by fecal flotation, but the use of the Baermann technique is more accurate.

Baermann Funnel Technique

The Baermann technique is used to isolate larvae from fecal samples and is especially useful in detecting lungworm larvae. The sample should be fresh, as there is a possibility of contamination of older samples with hatched trichostrongyle, strongyle, or *Strongyloides* larvae. Free living nematodes may also invade the sample, making lungworm identification much more difficult.

The Baermann apparatus consists of a funnel clamped to a stand and fitted with a short piece of rubber tubing at the stem end. A pinch clamp on the rubber tubing retains the water in the funnel until aliquots are drawn off for examination (Fig 2). The procedure is as follows:

1. Place 10 gm of feces in a piece of double layer cheesecloth. Gather the cheesecloth around the sample so that it is fully enclosed and place the sample on a piece of wire mesh or sieve so that it is suspended in the funnel. Alternatively, use a rubber band to fasten the cheesecloth and attach it to two applicator sticks, which will rest on the edges and suspend the sample in the funnel.
2. Fill the funnel with lukewarm water.

Make sure that the corners of the cheesecloth do not hang over the edge of the funnel because they will act as wicks for the water.

3. Allow the sample to sit for at least 8 hours.

4. Carefully remove the clamp and collect the first 3 or 4 drops onto a microscope slide and examine the slide with IOX magnification. Alternatively, collect the first 10 ml into a centrifuge tube; spin in a centrifuge for several minutes and examine the sediment under a microscope for larvae (Fig 3).

Conclusion

Dictyocaulus Viviparus is not commonly found as a parasite of cattle in the upper midwestern U.S. but cases do occur with possibly devastating consequences. The parasite should be considered as a diagnostic possibility in cases of respiratory disease that do not respond to therapy for other types of infection. Diagnosis is usually made on necropsy examination but can be accomplished antemortem by fecal examination using the Baermann technique.

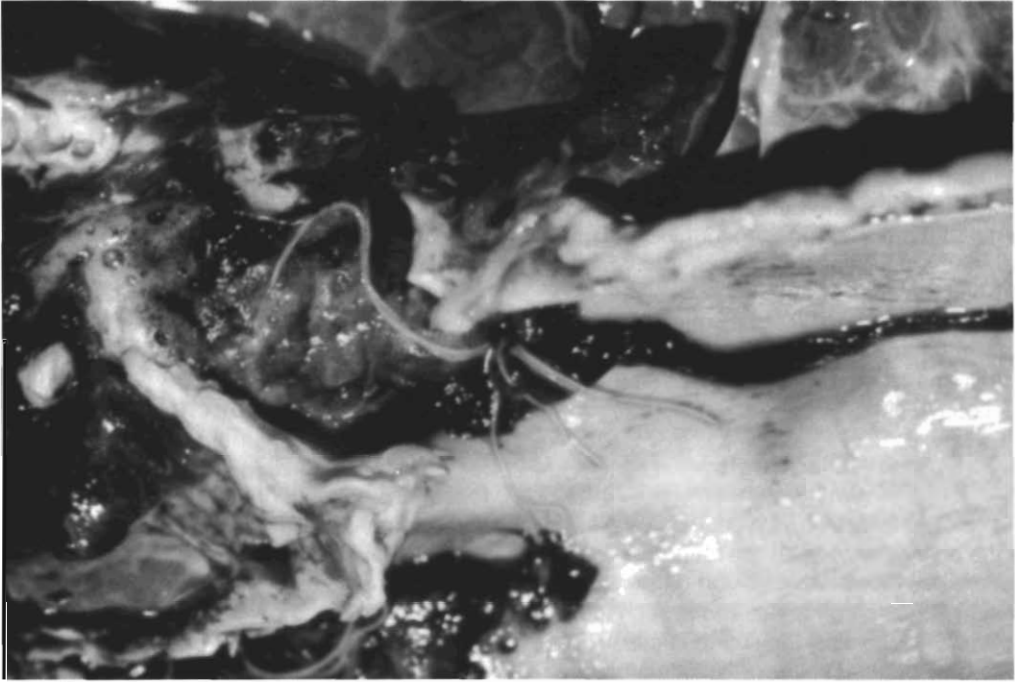


Figure 1. Mature form of *Dictyocaulus viviparus* partially blocking airways in a necropsy specimen.

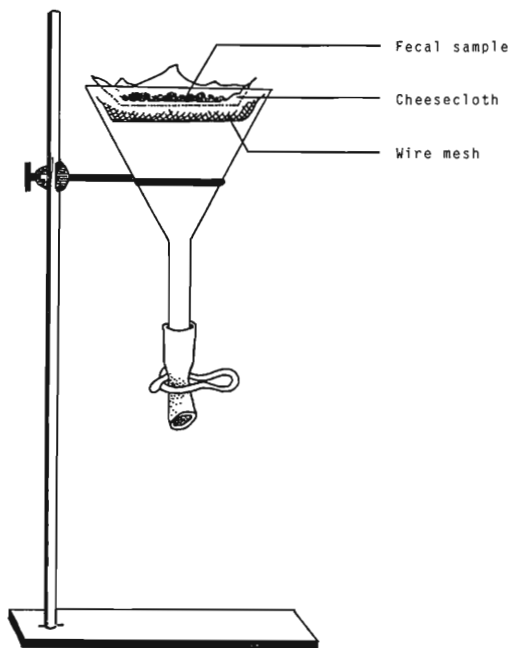


Figure 2. Baermann apparatus.¹

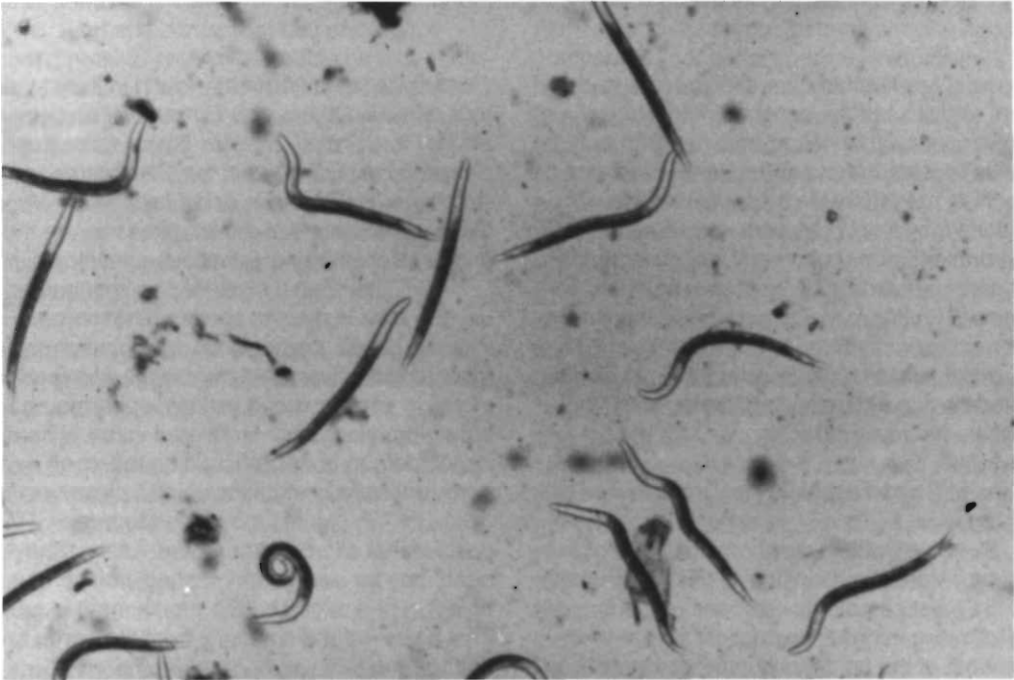

Figure 3. Larval form of *Dictyocaulus viviparus* recovered from a fecal specimen by use of the Baermann technique.

References

1. Ash L R, Orihel T C. *Parasites, a guide to laboratory procedures and identification*. Chicago: ASCP Press, 1987: 3-10.
2. Bennett D G. In: *Current Veterinary Therapy. Food Animal Practice*. Philadelphia: W.B. Saunders, 1986: 684-85.
3. Jorgensen R J, Ogbourne C P. *Bovine dictyocauliasis: a review and annotated bibliography*. Commonwealth Institute of Parasitology, Herts, UK. 1985: 2-26.
4. Jorgensen, R. J. In vitro effect of bile on the motility of *Dictyocaulus viviparus* third stage larvae. *Acta Veterinaria Scandinavica*. 1973; 14 (2): 341-343.
5. Gupta R P, Gibbs H C. Epidemiological investigations on *Dictyocaulus viviparus* (Bloch, 1782) infection in cattle. *Canadian Veterinary Journal*. 1970;11:149-156.
6. Oakley G A. Survival of *Dictyocaulus viviparus* infection on pasture. *Veterinary Record*. 1979; 104:530-31.