

# Quittor

## Outline of surgery and treatment

*V. M. Reinhart, '44*

**S**UCH a significant number of quittor cases have entered the veterinary clinic at Iowa State College in the past year that a short dissertation of this condition is warranted.

Quittor may be defined as an infectious inflammation involving the lateral cartilage of the third phalanx, characterized by a slow progressive necrosis of this cartilage and by the presence of one or more suppurating fistulous tracts. The cause of this condition is the introduction of infection into the cartilage, almost always by means of a wound. Horseshoe calks were the common offenders years ago. They usually produced a comparatively small wound which infected the cartilage below. Today the majority of quittors are caused by wire cuts. They leave the cartilage widely necrosed with a large amount of infected hyperplastic scar tissue around and above the cartilage. Rarely the condition is a complication of a corn or sand-crack or of a puncture wound from below.

### Symptoms

The symptoms vary according to the location, the extent of involvement, and the length of existence. Usually there is a thickening of the skin and the presence of a swelling dorsal to or including the coronary band. This swelling may be small or it may extend over the entire cartilage, bulging above and overlapping the coronary band. From this swelling one or several fistulous tracts may be discharging purulent or sanguino-purulent material which may contain particles of

necrotic cartilage and other diseased tissue. If the condition has existed for several months, horizontal rings may be present on the wall beneath the affected part, due to interference with the secretory function of the coronary band in this region. The degree of lameness exhibited varies according to the nature of the lesion. When only the posterior aspect of the cartilage, which contains comparatively non-sensitive tissue is affected, lameness is slight or absent. However, when the disease is in the anterior part of the cartilage, lameness is often very marked as either the joint or the sensitive laminae of the hoof may be involved. Thus the condition is not as serious and responds more effectively to treatment when confined to the posterior part of the cartilage.

### Types of Operations

Two general plans of handling this disease are in vogue. One, the most popular method, is a surgical operation devised during World War I by Perrier, a French army veterinarian. The other mode consists of the injection of a caustic agent through the fistulous opening to bring about separation of the necrotic tissue, destruction of the infection, and removal of the lining of the sinus.

In preparation for the surgical operation, the hair from the coronary band to the fetlock is clipped or preferably shaved. The hoof and the region around the coronary band are thoroughly scrubbed with mercury bichloride solution, 1:1000. A cotton pack is placed all around the foot

and is held in position with a muslin bandage. This is kept soaked with mercury bichloride solution for 48 hours to prevent a widespread septic inflammation of the soft tissues around the coronary region subsequent to the operation.

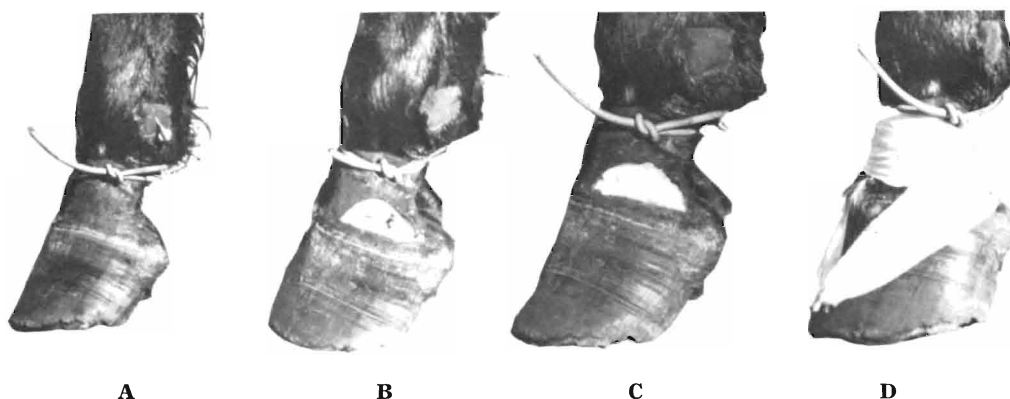
### Anesthesia

Prior to surgery a basal narcotic consisting of 30-60 Gm. of chloral hydrate in 2 liters of water is administered by way of a stomach tube, after which the horse is restrained. To complete the anesthesia a 2 percent procaine solution is infiltrated into the digital nerves which can

that all diseased tissue is removed. Many times the cartilage is followed down as far as 3 cm. or more below the coronary band. The foot should be kept extended during the operation to avoid invasion of the joint capsule, especially if the cartilage must be cut entirely through.

### Aftercare

Following the removal of all necrotic cartilage and infected scar tissue, the wound is tightly packed with gauze impregnated with bipp (bismuth subnitrate 1 part, iodoform 2 parts, and mineral oil 18 parts), and is securely bandaged with



**A.** Old wire cut and quittor. Demonstrates application of tourniquet. Note position of needle for infiltration of anesthetic about the digital nerve. **B.** Foot after Perrier operation has been performed. **C.** Wound tightly packed with gauze to control hemorrhage. **D.** Quittor bandage in place. Several more turns are taken after the tourniquet is removed.

be palpated underneath the skin over the ankle. The coronary region is covered with tincture of iodine and a tourniquet is tightly applied just below the fetlock.

A longitudinal incision is made through the skin just above the coronary band from one end of the scar to the other. Beginning at one end of this incision a curved incision is made extending up over the scar and fistulous tract, joining the other end of the first incision. The tissue included between these incisions is removed, exposing the outer surface of the lateral cartilage. Spots of necrosis in the cartilage indicated by a pea-green color must be carefully excised with a curette and scalpel. The line of excision should be carried some little distance around the visibly affected parts to be quite certain

muslin to control the hemorrhage which will occur when the tourniquet is released. A horseshoe nail is driven into the toe and bent forward to form a hook which will help to hold the bandage in place.

After-treatment consists of changing the bandage daily, and if possible, soaking the entire foot in a phenol-formalin solution of phenol 2 parts, formalin 3 parts and water 3 parts. Eight cc. of this stock solution is used per liter of warm water. Granulation tissue fills the wound in a short time and healing is usually complete in 3 to 5 weeks.

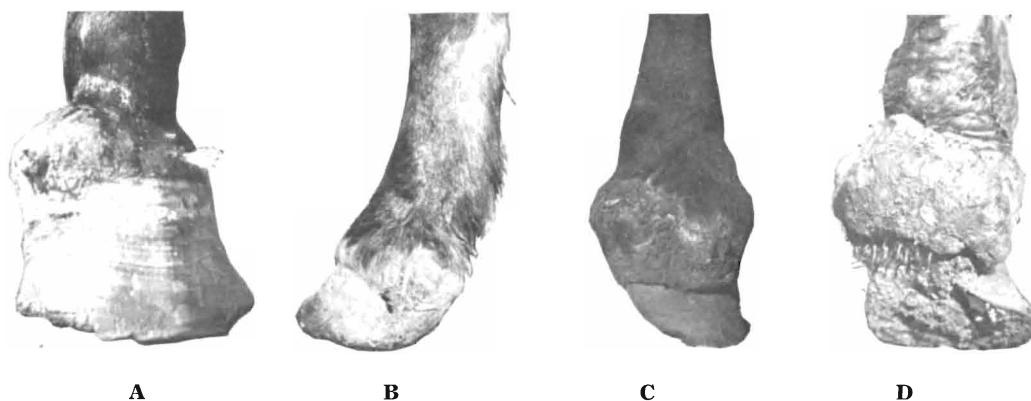
### Caustic Treatment

The second mode of treatment consists of the injection of a caustic solution into the fistulous tract. This method was com-

monly used before Perrier's operation was devised because the operations employed at that time were so difficult to perform and had such a small percentage of recoveries. In this method various caustics were used; pure formalin was probably as good as any. The area of the quittor was well cleaned and the hair shaved. Petrolatum was applied to the skin surrounding the tract to prevent injury by the escharotic solution. A 10 cc. syringe was filled with the solution to be used and the nozzle was inserted into the fistulous tract. Cotton packing was tightly placed around the nozzle to prevent backflow. Under moder-

All too often complete sloughing did not occur and the condition was not benefited and many times made worse. Also there was always a danger of the escharotic fluid gaining entrance to the joint cavity and producing extremely serious results. Consequently, surgery has largely replaced the injection treatment.

The Perrier method of surgery has the advantage over the classical operations and other types of treatment described in the literature in that there is no interference with the wall or coronary cushion, and that the foot has little or no blemish when the wound has cicatrised after the



**Four types of quittor. A. Considerable proliferation of connective tissue but not much injury to the coronary band. B. Very little scarring and the coronary band is practically intact. Both (A) and (B) have a good surgical prognosis. C and D. Cases where a great amount of connective tissue proliferation has taken place and coronary band is seriously damaged, making the prognosis distinctly unfavorable.**

ate pressure the escharotic was injected until the tract was entirely filled. If more than one tract was present they were all treated in the same manner. After a few days the necrotic tissue was supposed to slough, leaving a clean granulating wound.

operation. Occasionally the coronary band below the region of the operation is somewhat thickened, producing a slight lipping just above the hoof. However, this is soon covered by hair and is not noticeable except on close examination.

The farm power question has rather suddenly taken on an unusual importance, and with the many problems of material and transportation involved, farmers with enough horses and mules to do their work find themselves particularly fortunate, says E. A. Trowbridge of the University of Missouri College of Agriculture.

There are in the country now about 10 million horses. One-half of these are mares, and at least 4 million of these mares

will be of breeding age this summer. It would seem the part of good farm planning to breed mares that are worthy of being good brood mares, in an effort to provide farm power as soon as possible. While it is to be hoped that the war will end before colts born in 1944 are old enough to work, it is quite probable that the aftermath of the war will not have cleared away for some time after such colts are ready to do a day's work.

—Hoard's Dairyman.