

Gastric Dilatation and Volvulus in the Dog

by Gregory F. Grauer*
and Donald W. DeYoung, D.V.M., Ph.D.†

Summary

Acute gastric dilatation in the canine is a primary condition which may be followed by gastric volvulus or even gastric rupture. When gastric volvulus occurs, it causes splenic rotation and often torsion of the splenic pedicle. The gastric dilatation-volvulus (GDV) syndrome must always be considered a true emergency. If left untreated death is almost certain to follow due to cardiovascular collapse and electrolyte imbalance. Acute gastric dilatation with or without volvulus requires immediate and vigorous therapy. Both the mixed and small animal practitioner must understand the pathophysiology involved and have a preplanned course of action in mind in order to save the patient. It is also important that the veterinarian be aware of the high incidence of recurrence of the GDV syndrome.

Introduction

Gastric volvulus is always associated with and is probably preceded by gastric dilatation, however gastric dilatation can and does occur as a separate entity.¹³ Acute gastric dilatation (AGD) occurs in many different species³² and in all breeds of dogs at any age.³⁹ AGD is commonly seen in young puppies after overeating.¹⁰ This dilatation is usually self limiting through vomition or by passing the stomach contents into the duodenum. Two conditions are necessary for pathologic gastric dilatation to occur: 1) a source for the distending gas and/or fluid; and 2) an obstruction which prevents suf-

ficient relief of the distention either through eructation, emesis, absorption, or passage of the gastric contents into the small bowel.³⁵ The predisposing causes of AGD remain undetermined. Many factors are believed to play an etiologic role in gastric dilatation. The most common are aerophagia, emesis, parturition, trauma, gastric neoplasms, overeating, pica, abdominal surgery, duodenal obstructions, adynamic ileus, general anesthesia, vagal inhibition or splanchnic stimulation, and electrolyte disturbances.¹⁰

Gas accumulation in the stomach results in gastric dilatation, and fluid accumulation has been shown to be secondary to the distention. The fluids are probably gastric, pancreatic, biliary, and small bowel secretions that are not absorbed due to the decreased venous return from the distended stomach.³⁵ Gastric gas analysis from clinical cases has shown that swallowed air is the major source of stomach gas in AGD.⁸ Rapid eating, wolfing down food, or gulping liquids will considerably increase the degree of aerophagia that accompanies normal deglutition.³⁵ Other sources of gastric gas that have been proposed are chemical gas genesis from the reaction of gastric acid and basic pancreatic secretions or the bicarbonate in saliva. Diffusion of blood gases into the gastric lumen especially with the existing venous stasis and bacterial fermentation-putrefaction of suitable substrates have also been proposed as gas sources.^{14,32,40}

Once gastric dilatation is in existence, the pathogenesis of the dilatation-volvulus complex is initiated. As the stomach dilates, the greater curvature tends to move cranial until it is at an angle of 90° to the organoaxial alignment. The pylorus moves cranial and to the left, whereas the cardia passes caudad.¹⁰

*Mr. Grauer is a fourth year student in the College of Veterinary Medicine.

†Dr. DeYoung is a Professor of Veterinary Clinical Sciences at Iowa State University.

The stomach usually moves in a clockwise direction both as viewed from caudal to the stomach and as viewed from the ventral surface of the patient, in other words an oblique clockwise direction.²⁰ Previous authors have also described a counterclockwise partial volvulus of the stomach of 90°,⁵ however this has been questioned.^{11,12} Clockwise volvulus is by far the most common. The spleen follows the stomach in its clockwise movement, and because of interference with the splenic vessels, is vastly engorged.¹¹ When the degree of twisting of the stomach is less than 180°, the obstruction to the pylorus and esophagus is not complete. When the rotation exceeds 180° the condition is termed a complete volvulus and total obstruction exists at the esophagus and pylorus.¹⁰

Gastric volvulus is stated to be prevalent in those dogs with a deep narrow thorax, and particularly the larger breeds. These include Great Dane, St. Bernard, Bloodhound, Standard Poodle, Boxer, Irish Setter, Weimaraner, English Sheepdog, and Gordon Setter.^{1,13} The Iowa State Veterinary Teaching Hospital has, in addition, seen German Shepherds, Vizslas, Dobermans, Chesapeake Bay Retrievers, and Golden Retrievers affected with gastric volvulus. Reported cases of gastric volvulus in small breeds³ and even in cats¹⁸ have appeared in the literature but these are rare. Gastric volvulus has been observed in dogs one to 14 years of age with an average age of 5.8 years.³

Since gastric dilatation precedes gastric volvulus, all the etiological factors that are thought to cause dilatation may be incriminated in cases of gastric volvulus. The frequent occurrence of gastric volvulus in certain breeding lines suggests the possibility of hereditary predisposition.¹ Anatomical features that are thought to contribute to gastric volvulus include a deep thorax;^{1,13} a lengthening or rupture of the supportive gastric ligaments;¹ primary splenic rotation;^{19,23} gastric atony;¹ and pyloric sphincter dysfunction.¹⁵ Post-prandial exercise and management practices are often thought to have been part of the etiology.³²

Previous authors disagree on sex incidence but studies³ have shown a two to one ratio of males to females in dogs affected with GDV. Records from the Iowa State Veterinary

Teaching Hospital concur with this ratio. There appears to be no seasonal incidence.

The GDV syndrome has a high rate of recurrence. In one study³ involving 160 cases (87 dogs) the number of dilatations in individual animals ranged from one to ten, with 28 animals experiencing more than one episode. The number of volvuli in individual animals ranged from one to five, with nine animals having one or more recurrences. Recurrence following surgery is common, and approximates 30-40 per cent of cases reported.¹¹

The mortality rates for GDV vary from 26.8 per cent in one study³ to 49.4 per cent in another study.³⁴

History and Presenting Clinical Signs

Acute GDV will most commonly present with a history of distention of the patient's abdomen and several unsuccessful attempts at vomiting.⁴⁰ As noted before, this syndrome is usually seen in the sporting, working, or giant breeds. The onset of signs is usually preceded by the ingestion of a large meal consisting most often of a commercial dry dog food, followed by the ingestion of a large volume of water. These animals are often fed and watered once daily and then exercised shortly afterward. Within minutes to six hours later the dog shows signs of pain and restlessness. The owner may have observed weakness but many of these animals are stoic and remain standing upon admission. Even in this instance, if the stomach is distending a hypotensive, hypovolemic state will soon develop. The dog's attitude soon becomes worried and apprehensive and attempts to both vomit and find a comfortable position are unsuccessful. Excessive salivation begins and the animal becomes increasingly dyspneic. If the dog is still standing, the elbows are rotated outward in an attempt to increase its tidal volume. The obviousness of the clinical signs depends upon the severity of the gastric distention. Physical examination will reveal an enlarged cranial abdomen which is firm to tense on palpation and usually tympanic to percussion. Mucous membranes are usually pale and exhibit a prolonged refill time. Hypotensive shock is indicated when tachycardia and a weak femoral pulse are present.^{11,13,29,32,40}

Gastric dilatation with volvulus will not allow passage of a stomach tube. Differentiation between a simple gastric dilatation and a partial volvulus (less than 180°) provides the greatest diagnostic challenge. The degree of difficulty in passing the stomach tube is dependent on three factors: 1) the degree of volvulus; 2) the skill of the operator; and 3) the cooperativeness of the patient.¹⁰

Partial gastric volvulus should be considered in an older dog with a history and clinical findings suggestive of gastric dilatation. A partial volvulus can be presented with a somewhat chronic history of vomiting and anorexia but this is atypical. Radiography may be required to diagnose this condition. It should always be remembered that a partial gastric volvulus has the potential to progress to a complete volvulus and therefore shock and death quite rapidly.^{6,10}

Radiographic Findings

Radiography is rarely necessary to diagnose the acute GDV complex. Simple dilatation as opposed to GDV is difficult to interpret on radiographs because the shapes and positions of abdominal structures are confusing due to the gastric distention.²⁰ On plain radiographs the gastric shadow occupies 50 to 75 per cent of the abdomen, and appears as a large radiolucent mass.²¹ Furthermore, the added stress of radiography many times is not warranted.

Differential Diagnosis

The diagnostic triad of unproductive retching, anterior abdominal distention with tympany, and inability to pass a stomach tube characterizes GDV.³⁹ Splenic torsion may be difficult to differentiate since it can be a predisposing factor to GDV.¹⁹ In the early stages, torsion of the spleen should reveal splenodynia and rapid, symmetrical splenic enlargement in the left mid-abdominal region.⁷

Acute pancreatitis will show productive vomiting without abdominal bloat. An intestinal intussusception should be more chronic in nature and less painful. Abdominal palpation should reveal a hard mass

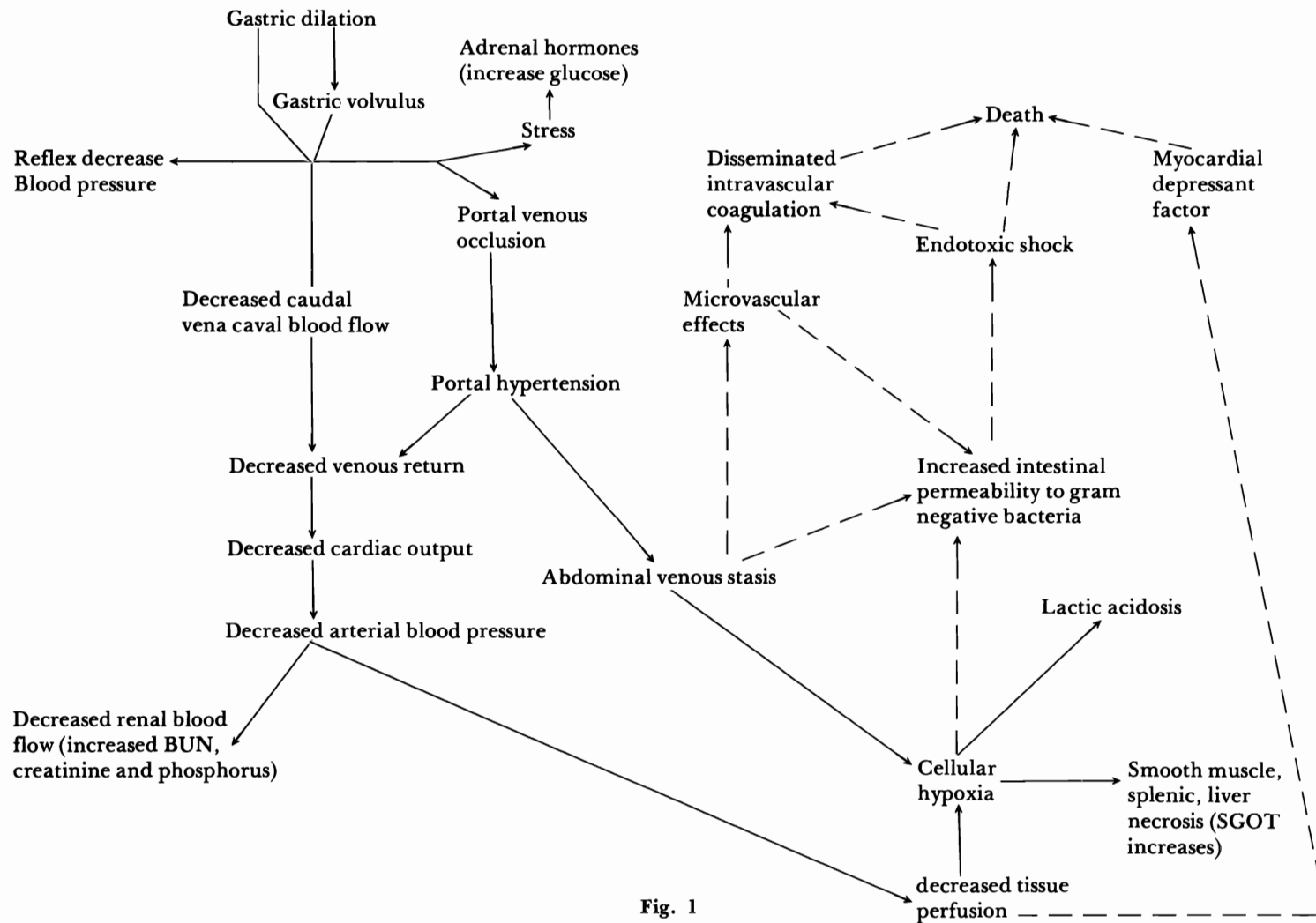
and melena may exist with an intussusception. An intestinal obstruction or volvulus should present itself with productive vomiting, lack of salivation, uniform abdominal distention, and easy passage of a stomach tube without relief of the distention. The signs of intestinal volvulus are more chronic and less dramatic than those of GDV.¹³ Acute gastritis or a foreign body is also a less severe condition and excessive vomiting will occur. If gastric dilatation occurs in small breed dogs one must always be suspicious of a primary pyloric malfunction such as pylorospasm, stenosis, or neoplasia.⁴⁰

Pathophysiology

With the onset of GDV, numerous physiologic alterations are initiated which, if not stopped, soon become irreversible. See fig. 1.

The cardiovascular collapse associated with GDV results from three sources: 1) hypovolemic shock, due to sequestration of fluid and electrolytes in the distended stomach; 2) hypotensive shock, due to a decrease in venous return caused by compression of the caudal vena cava and obstruction to flow through the portal vein; and 3) neurogenic shock, mediated through stretch receptors in the stomach and splanchnic afferent nerves.^{10,38} Acute GDV causes an obstruction to blood flow through the caudal vena cava.^{10,24,35,36,38} Increased intragastric pressure also decreases blood flow through the portal venous system. With gastric volvulus the portal vein undergoes torsion.³⁶ Thus venous return to the heart is greatly diminished as blood is sequestered in the portal system, splanchnic organs, and caudal vena cava. Collateral return via the ventral vertebral sinuses to the azygos vein to the cranial vena cava is not nearly great enough to compensate.³⁵ The exact mechanism of the neurogenic hypotensive pathways mediated through the vagus nerves and splanchnic sympathetics is not known and it appears that the venous obstruction plays a much larger role.

The result of this sequestration of blood and the accompanying hypotension and hypovolemia is a decreased cardiac output and a low velocity of blood flow.³⁵ Arterial blood pressure drops off and tissue perfusion is decreased. This decreased perfusion to the



abdominal viscera causes gut motility to cease which allows the production of endotoxins by gram negative gut bacteria. It is thought that these endotoxins are absorbed by the lymphatics.³⁵ Endotoxic shock rapidly becomes a factor since the hepatic reticuloendothelial system has been shut down by the portal vein occlusion. Endotoxemia in the dog will produce further hypotension, decreased cardiac output, decreased central venous pressure, decreased venous return, and venous pooling in the capillaries and venules.³⁵

Hypoperfusion of the pancreas initiates an ischemic, hypoxic, and acidotic state in this organ. Cellular destruction and lysosomal membrane breakdown occur. Proteases are released and protein digestion takes place producing biologically active peptides. Myocardial depressant factor (MDF) is one of these biologically active peptides. MDF is a cardiodepressant as well as a vasoconstrictive agent. MDF along with the endotoxins produced in GDV could be the cause of the cardiac arrhythmias often seen.⁴⁰

Microvascular disorders also develop in the presence of venous stasis, hypoxia, acidosis, and endotoxemia. The acceleration of the coagulation system by these conditions is associated with the onset of disseminated intravascular coagulation (DIC).³⁵ DIC causes platelet aggregation and a depletion of clotting factors and by doing so predisposes the dog's body to hemorrhage. A secondary fibrinolysis can develop that will break down existing clots and lead to further hemorrhage.³⁵

The impaired abdominal venous blood flow results in tissue hypoxia, anaerobic metabolism, and an increased production of organic acids. A metabolic acidosis soon exists and reduced arterial blood flow to the kidneys limits hydrogen ion excretion.³⁷

In experimentally produced cases of GDV a consistent necropsy finding was congestion of the kidneys, spleen, liver, and pancreas along with pancreatic hemorrhage.²⁵ Rises in blood urea nitrogen, creatinine, and phosphorus³⁷ provide evidence for reduced renal function but most of the decreased function is probably pre-renal in origin. Experiments have also shown the hyperkalemia to significantly increase after the dilatation has been relieved and the sequestered blood is released. This finding could be the key to the not uncommon sudden deaths seen in dogs after

decompression of the gastric dilatation.³⁷

As the expanding stomach impinges on the diaphragmatic excursion, the tidal volume is decreased and the respiratory rate is increased to compensate. This creates a transitory respiratory alkalosis at the same time fluids and electrolytes are being sequestered in the transcellular spaces creating a transitory metabolic alkalosis. This short lived alkaline state is thought to be insignificant,¹⁰ but could possibly cause excitation and hyperactivity in the affected dog as the stomach is expanding.

The shallow respiration and the decreased lung perfusion contribute to late oxygenation of peripheral tissues. Areas of pulmonary edema, congestion, and hemorrhage have been seen at necropsy in animals that died of GDV.³⁵

As gastric dilatation progresses and intragastric pressure increases, venous drainage from the stomach is compromised. The high intragastric pressure will also initially cause a vagal induced bradycardia. Arterial perfusion appears to be affected only slightly in the beginning but marked venous congestion and stasis occur within the wall of the stomach. Normally, 80 per cent of the blood flow to the canine stomach is distributed to the mucosa. This venous stasis quickly leads to mucosal cell anoxia with subepithelial hemorrhage and edema. With the high intragastric concentration of hydrogen ions, mucosal ulceration and frank hemorrhage can occur. This tissue damage releases histamine which cannot be demethylated by the gastric mucosa. Histamine will cause further hemorrhage and gastric ulcer formation. Severe and often irreversible damage to the ganglion cells of Auerbach's plexus occur if blood circulation is not restored before approximately four hours. The end result of an unrelieved gastric dilatation is a hemorrhagic gastritis or possibly gastric rupture.^{10,14,35,38}

Pressure occlusion of the portal vein due to the gastric distention hinders venous drainage from the spleen. This can also indirectly contribute to further gastric venous stasis via the vasa brevis of the gastroepiploic and left gastric veins. It has been shown experimentally that splenic ischemia leads to decreased production of clotting factors VIII and IX which potentially could help initiate DIC. Release of the stagnant splenic blood at

the time of surgery may lead to further vascular sludging. As mentioned before, torsion of the spleen's vascular pedicle may accompany gastric volvulus or occur independently.^{19,35}

Treatment

When presented with a dog having cranial abdominal distention and the presence of shock is detected, one and preferably two peripheral veins should be catheterized. Large bore indwelling catheters should be used to administer Lactated Ringers at a rate of 40 ml/lb within the first hour. This fluid therapy will both increase venous return and decrease vascular stasis in capillaries. Bolus injections of glucocorticoids should be given to help increase cardiac output, stabilize lysosomal membranes, and decrease the body's reaction to the endotoxin. Glucocorticoids also facilitate endotoxin clearance from the body.²⁹ Dexamethasone (Azium)[®] should be given at a dose of 1 mg/lb, IV, and prednisolone sodium succinate (Solu Delta Cortef)[®] at a dose of 5-10 mg/lb, IV. The Azium will take effect about the same time the Solu Delta Cortef is wearing off. 1-2 mg/lb., IV sodium bicarbonate is given to combat the increasing metabolic acidosis. Finally, an aqueous antibiotic solution is given IV to help reduce the production of endotoxin, and to combat any anaerobic bacteria from the gastrointestinal tract. The antibiotic of choice is probably chloramphenicol at a dosage of 25 mg/lb.^{16,29,40}

Once the shock therapy has been initiated, the cause of the cranial abdominal distension should be determined. If need be, a small amount of Innovar[®] (0.5 ml in an average Great Dane) can be given IV after atropine. Then a stiff, vinyl, premeasured stomach tube is passed into the stomach.¹¹ If the tube is easily passed into the stomach and the distension relieved, gastric lavage with warm water should be performed. The animal should be observed closely for 24 hours for any signs of recurrence. If it is not possible to observe the animal closely, a pharyngostomy tube should be inserted to insure continuous gastric decompression. Once the animal has been stabilized, an upper G.I barium series should be performed, even if the animal appears normal, to evaluate the position of

the stomach. If any malposition is detected, exploratory surgery is recommended for repositioning the stomach.¹⁶

If the gastric tube does not enter the stomach, and the abdominal distension is not relieved, then a tentative diagnosis of gastric volvulus is made. Care should be taken while trying to pass the stomach tube into the cardia when resistance is met. Devitalized tissue may exist, and therefore iatrogenic gastric or esophageal rupture may occur.¹⁴

At this point, persons working on the problems associated with gastric volvulus do not always agree upon the best method to handle a particular clinical case. The one thing that is agreed upon, however, is the need for prompt, vigorous therapy. Two basic approaches exist, each with many variations. The first approach is to relieve the gastric distention by gastric marsupialization or gastrostomy, allow the patient to stabilize, and then perform the definitive surgical correction at a later time. The other approach involves an immediate exploratory laparotomy and definitive surgical correction of the volvulus. Non-surgical repositioning of the stomach has also been advocated.^{15,32} These techniques require either special equipment or experience and are not widely practiced or successful. Some authors advise gastric trocarization for immediate relief of the abdominal distention.^{12,17,33} Other authors say this technique should be avoided due to the possibility of iatrogenic gastric rupture and peritonitis. Additionally, the sudden release of pressure by trocar may precipitate or enhance existing shock.¹⁰

Gastrostomy or gastric marsupialization is a rapid and effective way to produce complete gastric decompression. The operation can be performed in 30 minutes by a single doctor without a skilled aide. This technique allows gastric lavage and palpation-visualization of the stomach for necrosis and volvulus. General anesthesia is avoided.⁴⁰ With the dog standing or in left lateral recumbency, the right paracostal area is prepped, and a five centimeter incision is made two centimeters behind and parallel to the costal margin after infiltration with 2% lidocaine.[®] Through a grid approach in the abdominal muscles, the stomach wall is attached to skin at either end of the incision by 2-0 silk stay sutures. The long ends of these stay sutures are used to

suture the stomach to the skin margin. Following the gastrostomy and removal of the contents, the stomach is lavaged with saline and inspected for areas of necrosis. The cut edges of the stomach can be oversewn with 3-0 chromic gut to control bleeding if necessary. At this point, hydration, renal function, and electrolyte balance are assessed and corrected to stabilize the patient. When this stabilization is complete (usually within 2-24 hours), the animal is anesthetized, and a definitive surgical procedure is performed.^{17,27,33} Some authors have criticized this technique, stating that the results of the gastrostomy have not been satisfactory. The gastric fistula tends to soil the animal, and is often slow in healing.³¹

The second approach to surgical correction of the GDV syndrome is to perform the exploratory laparotomy as soon as the diagnosis has been reached, and shock therapy initiated. Atropine is given pre-operatively, and if possible, anesthesia is induced with halothane. If this is not possible, induction with thiamylal sodium (Surital)[®] to effect may be carried out, and anesthesia maintained with minimum necessary levels of halothane.[®] The use of nitrous oxide is contraindicated as it will increase the distension of the gas pockets in the stomach by way of diffusion. The patient, ideally, should be closely monitored during the surgery by EKG, urine output and CVP.

Many different surgical procedures have been advocated, but it should be remembered that no surgical procedure will totally prevent recurrence of gastric volvulus. The surgical procedures utilized in the correction of a gastric volvulus have been directed at the following: 1) correction of the anatomical and pathological abnormalities, and 2) prophylactic measures to lessen recurrence rates.³⁴

A long incision is made along the ventral midline from the xiphoid cartilage to several centimeters below the umbilicus. A large diameter stomach tube should be passed. By exteriorizing the spleen first, and then grasping the portion of the stomach closest to the vertebral column and slowly rotating it in a counterclockwise direction, one can usually reposition the stomach.¹⁶ If the stomach is so grossly distended that it is difficult to work with, gastric paracentesis with a needle connected to a suction device, will allow

decompression, and ease repositioning of the stomach without contaminating the abdomen. Once the stomach has been repositioned the spleen should be repositioned as well. The stomach contents and gas are usually easily relieved by way of the stomach tube upon correct repositioning. Gastric lavage with warm water should then be performed. The stomach should be examined for areas of necrosis which should be removed. The spleen should be examined; partial or total splenectomy should be performed only if the spleen is damaged or thrombosed.¹⁶

In an attempt to prevent a recurrence of gastric volvulus, gastropexy has been employed. Usually, the stomach does not adhere permanently to the abdominal wall after gastropexy, but is probably important in preventing a recurrence during the immediate post-operative period.²⁴ A "permanent" gastropexy technique has appeared in the literature. A left paracostal incision and grid approach is used, then using 00 chromic gut in a two-step continuous pattern, the deep layer of closure incorporates the stomach wall into the cranial, and then separately the caudal, aspect of peritoneum and transverse abdominis muscle. With four successive sutures, the gastric submucosa-muscularis is bonded to the peritoneum-transversus abdominis, internal oblique, external oblique, and the dermal fascia.^{2,4}

Gastrocolopexy has been advocated by other authors.⁹ The transverse colon is brought into apposition with the greater curvature of the stomach. The greater omentum is pushed dorsal to the transverse colon to facilitate suturing to the greater curvature of the stomach. The serosal surfaces of the stomach and colon are gently scarified with a scalpel blade, and simple interrupted 2-0 monofilament nylon sutures are placed through both muscular layers.

A tube gastrostomy has also been used to obtain permanent gastric adhesions to the abdominal wall. A 24 to 26 French Foley catheter is placed through an abdominal stab incision to the right of the ventral midline and about four centimeters caudal to the last rib. The catheter should perforate several layers of the greater omentum before entering the stomach. This will ensure that the wound

heals without contamination of the abdominal cavity when the tube is withdrawn. 0 silk is used to place a purse-string suture in the antral region of the stomach. The tip of the Foley catheter is placed into the stomach through a stab incision in the middle of the purse-string. The catheter bulb is inflated inside the stomach and the purse-string is tied down around the tube. The catheter is then used to bring the stomach to the peritoneal wall where a gastropexy is performed with 0 silk. The Foley catheter is firmly sutured to the skin to maintain the traction on the stomach. The abdominal closure is routine. After five to seven days the bulb is deflated and the tube withdrawn. Local treatment of the wound allows the fistula to drain and seal over.²⁸

Pyloric sphincter dysfunction has been implicated in the cause of the GDV syndrome. In order to decrease gastric emptying time, the pyloromyotomy, various pyloroplasties, and gastroduodenostomy have been utilized.^{13,34,39}

A pharyngostomy tube makes management of the post-surgical gastric volvulus much easier. Medications, food, and water can be given by way of the pharyngostomy tube while it is keeping the stomach decompressed.³⁴

Postoperatively, the animal should be maintained on intravenous fluids until well stabilized physiologically. Feeding is started 24 hours after surgery. A light broth is given three to four times daily through the pharyngostomy tube. The dog can be allowed to eat small amounts gruel several times a day on the third post-operative day. The pharyngostomy tube is usually removed after the fifth day. Antibiotics are continued through the seventh post-operative day.¹⁰

When animals are discharged from the hospital, limit food and water while the animal again becomes accustomed to its normal surroundings. Since these animals are predisposed to relapse, they should be fed balanced, easily digested meals that will not prolong gastric emptying. Low fat meals of cottage cheese, lean meats, and some macaroni are excellent as is a prepared dietary food such as "i/d". These animals should be fed small amounts of food, three to four times a day. They should never be allowed to eat or drink to the point of engorgement. Post-prandial exercise should

not be allowed and clean, fresh water should always be available.²⁶

Discussion—Conclusion

All cases of GDV must be considered true emergencies. A partial volvulus has the potential to progress to a total volvulus quite rapidly.

There are four things one should always have in mind in association with the GDV syndrome: 1) GDV is primarily a problem of large breed dogs and usually occurs within the ages of one to ten years, 2) These animals are predisposed to subsequent attacks of GDV, 3) GDV is a life threatening condition. It must be accurately diagnosed and treated promptly and vigorously. A pre-planned course of action should be laid out, and 4) No single or combination of current surgical procedures has eliminated the possibility of recurrence.³

References

1. Andrews, A. H.: A Study of Ten Cases of Gastric Torsion in the Bloodhound. *Vet. Rec.* 86: 689-693, 1970.
2. Betts, C. W., et. al.: Recurring Gastric Volvulus in a Dog. *Journal of Small Animal Practice.* 16: 433-438, 1975.
3. Betts, C. W., et. al.: A Retrospective Study of Gastric Dilatation-Torsion in the Dog. *Journal of Small Animal Practice.* 15: 727-734, 1974.
4. Betts, C. W., et. al.: "Permanent" Gastropexy—as a Prophylactic Measure Against Gastric Volvulus. *JAAHA.* 12: 177-181, 1976.
5. Blackburn, P. S., and McFarlane, D.: Acute fatal dilatation of the stomach in the dog. *J. Comp. Pathol.* 54: 189, 1944.
6. Boothe, H. W. and Ackerman, N.: Partial Gastric Torsion in Two Dogs. *JAAHA.* 12: 27-30, 1976.
7. Brody, R. S.: Spleen. In *Canine Surgery*. 2nd Archibald Edition. American Veterinary Publications, Inc. Santa Barbara, CA. 1974, 807-826.
8. Caywood, D., et. al.: Gastric Gas Analysis in the Canine Gastric Dilatation-Volvulus Syndrome. *JAAHA* 13: 459-462, 1977.
9. Christie, T. R., and Smith, C. W.: Gastrocolopexy for Prevention of Recurrent Gastric Volvulus. *JAAHA.* 12: 173-176, 1976.
10. Cornelius, L. M. and Wingfield, W. E.: Diseases of the Stomach, pages 1125-1149 in Ettinger S. J., *Textbook of Veterinary Internal Medicine: Diseases of the dog and Cat*, Vol. 2. W. B. Saunders Company, Philadelphia, Pa. 1975.
11. Dann, J. R.: Medical and Surgical Treatment of Canine Acute Gastric Dilatation. *JAAHA* 12: 17-22, 1976.
12. Dann, J. R. and DeHoff, W. D.: Canine Bloat Panal, Morris Animal Foundation, Denver, Colo., Aug. 5, 1975.
13. DeHoff, W. D. and Greene, R. W.: Gastric Dilatation and the Gastric Torsion Complex. *Vet Clinics of N.A.* Vol. 2, No. 1, 141-153, 1972.
14. Dingwall, J. S. and Eger, C. E.: Management of Acute Gastric Dilatation with Torsion and Rupture: A case report. *JAAHA* 12: 23-26, 1976.

15. Funkquist, B.: Gastric Torsion in the Dog. Non-Surgical Reposition. *Journal of Small Animal Practice*. 10: 507-511, 1969.
16. Greene, R. W.: Gastric Dilatation-Torsion (Volvulus) Complex. *AAHA Proceedings* 227-229, 1977.
17. Johnston, D. E.: Treatment of Gastric Dilatation and Torsion in the Dog, pages 936-939 in Kirk, R. W., *Current Veterinary Therapy VI Small Animal Practice*. W. B. Saunders Company, Philadelphia, PA. 1977.
18. Key, D. M.: Dilation and Torsion of the Stomach in a Cat. *Feline Practice*. Vol. 7, No. 1, 38-39, 1977.
19. Kipnis, R. M.: Torsion of the Splenic Pedicle and Gastric Volvulus in a Dog. *JAVMA*. Vol. 164, No. 12: 1202-1203, 1974.
20. Kneller, S. K.: Radiographic Interpretation of the Gastric Dilatation-Volvulus Complex in the Dog. *JAAHA* 12: 154-157, 1976.
21. Larsen, L. H. and Bellenger, C. R.: Stomach and Small Intestines, pages 555-576 in Archibald, J., *Canine Surgery*, Second Edition. American Veterinary Publications, Inc., Santa Barbara, California, 1974.
22. Less, G. E., et. al.: Management of Gastric Dilatation-Volvulus and Disseminated Intravascular Coagulation in a Dog: A Case Report. *JAAHA*. 13: 463-469, 1977.
23. Maxie, M. G., et. al.: Splenic Torsion in Three Great Danes. *Canadian Veterinary Journal*. 11: 249, 1970.
24. Merkley, D. F., et. al.: Experimentally Induced Acute Gastric Dilatation in the Dog: Cardipulmonary Effects. *JAAHA*. 12: 143-148, 1976.
25. Merkley, D. F., et. al.: Experimentally Induced Acute Gastric Dilatation in the Dog: Clinico-pathologic Findings. *JAAHA* 12: 149-153, 1976.
26. Morris, M. L. Jr.: Nutritional Management in Gastrointestinal Disorders. *Vet. Clinics of North America*. Vol. 2, No. 1, 78, 1972.
27. Pass, M. A., and Johnson, D. R.: Treatment of Gastric Dilatation-Torsion in the Dog. Gastric Decompression by Gastrostomy Under Local Anesthesia. *Journal of Small Animal Practice*. 14: 131-142, 1973.
28. Parks, J. L. and Greene, R. W.: Tube Gastrostomy for the Treatment of Gastric Volvulus. *JAAHA*. 12: 168-172, 1976.
29. Rawlings, C. A., et. al.: Shock Therapy and Anesthetic Management in Gastric Dilatation-Volvulus. *JAAHA* 12: 158-161, 1976.
30. Shelton, M. E., and DeYoung, D. W.: Canine Bloat and What You Can Do To Help. A review article. *Pure-Bred Dogs American Kennel Gazette*. Pages 59-66, November, 1977.
31. Stockner, P.: Canine Bloat Update. *Pure-Bred Dogs American Kennel Gazette*. Pages 44-45, October 1976.
32. Van Kruiningen, H. J., et. al.: Acute Gastric Dilatation: A Review of Comparative Aspects, by Species, and a Study in Dogs and Monkeys. *JAAHA*. 10: 294-324, 1974.
33. Walshaw, R. and Johnston, D. E.: Treatment of Gastric Dilatation-Volvulus by Gastric Decompression and Patient Stabilization before Major Surgery. *JAAHA* 12: 162-167, 1976.
34. Wingfield, W. E., et. al.: Operative Techniques and Recurrence Rates Associated with Gastric Volvulus in the Dog. *Journal of Small Animal Practice*, 16: 427-432, 1975.
35. Wingfield, W. E., et. al.: Pathophysiology Associated with Gastric Dilatation-Volvulus in the Dog. *JAAHA* 12: 136-142, 1976.
36. Wingfield, W. E., et. al.: Experimental Acute Gastric Dilatation and Torsion in the Dog. 2. Venous angiographic alterations seen in gastric dilatation. *Journal of Small Animal Practice* 15: 55-60, 1974.
37. Wingfield, W. E., et. al.: Experimental Acute Gastric Dilatation and Torsion in the Dog. 1. Changes in the Biochemical and Acid-Base Parameters. *Journal of Small Animal Practice* 16: 41-53, 1974.
38. Wingfield, W. E., et. al.: Pathophysiology of the Gastric Dilatation-Torsion Complex in the Dog. *Journal of Small Animal Practice*. 15: 735-739, 1974.
39. Wingfield, W. E. and Hoffer, R. E.: The Stomach: Gastric Dilatation-Torsion Complex in the Dog, pages 112-118 in Bojrab, M. J., *Current Techniques in Small Animal Surgery I*, Lea and Febiger, Philadelphia, Pa., 1975.
40. Zolton, G. M.: Gastric Dilatation-Torsion Syndrome (a practitioner's Approach). *DVM*. Vol. 8, No. 10, pages 17- , 1977.

WHAT IS YOUR DIAGNOSIS?

by Gregory F. Grauer* and
Dr. Russell Mitten†

History

A two year old, spayed female, German Shepherd was examined because of a lameness in the left front leg. The lameness was intermittent for six months but now the

dog is always lame whether walking or standing. Palpation revealed a painful area on the cranial-lateral aspect of the left humerus just below the shoulder joint.

*Mr. Grauer is a fourth year student in the College of Veterinary Medicine.

†Dr. Miller is associate professor of Veterinary Clinical Sciences at ISU.