

CLINICAL MEDICINE

Index

1

Intussusception in a Dog. An eighteen-month-old Boxer female was admitted to Stange Memorial Clinic, September 29, 1953, with the history of having eaten practically no food in two weeks. Examination revealed that the bitch coughed up blood and had a bloody discharge from both the vulva and anus. Palpation revealed what was thought to be an elongated foreign body in the intestine, but the fluoroscope would not reveal the true nature of the object.

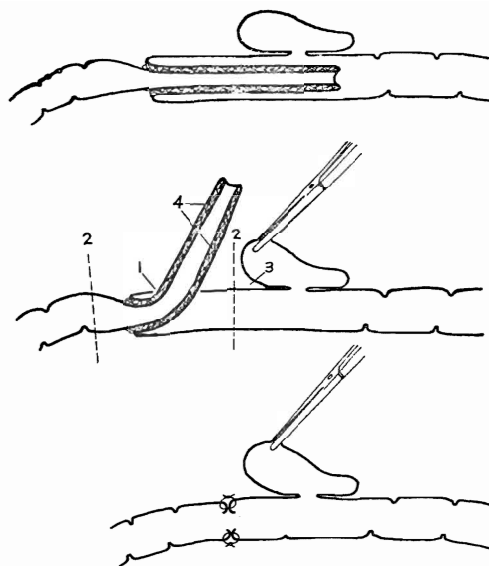
A blood examination revealed a red count of 3,580,000 per cu. mm., a white count of 10,340 per cu. mm., and a hemoglobin level of 81.9 percent. The bitch would not consume food and was losing weight daily, although her temperature remained normal. She also remained quite alert and active.

On October 1, fecal material was found in her exercise pen containing whole kernels of corn. This immediately aroused the suspicion that she had devoured a small ear of corn which had lodged in the intestine. Although surgery had been postponed because of her debilitated condition, it was decided that a laparotomy would be performed.

After being prepared for surgery and anesthetized with pentobarbital sodium given intravenously, 1 cc. adrenal cortex and 1 cc. Koagamin were administered. A four-inch incision was made along the linea alba just posterior to the umbilicus to reveal an intussusception. The posterior part of the small intestine

1. Intussusception in a Dog. 87
2. Dermoid Cyst in a Dog.. 88
3. Pyometritis in a Springer Spaniel 89
4. Partial Torsion of the Cecum of a Bovine..... 89
5. Compound Comminuted Fracture of the Left Metatarsus of a Pony.... 90
6. Hydrops Amnii in a Ewe 91
7. Infarction of the Duodenum 91
8. Transmissible Lymphosarcoma 92
9. Tampon Operation for Chronic Prolapsus Vaginae 93

was found to be intussuscepted, with the posterior part of the intussusception passing beyond the ileo-cecal valve into the colon. Attempted reduction failed because the intussuscepted layers were securely adhered together. A two-inch longitudinal incision was then made about seven inches anterior to the base of the cecum. With careful manipulation, the involved portion was forced out through the incision leaving a portion of the ileum available to be resected. The cecum was dissected loose for about two-thirds of the length of its attachment with the ileum,



Intussusception of the small intestine passing beyond the cecum. (1) Incision to allow reduction of the intussuscepted portion. (2) Points of resection. (3) Cecum dissected loose. (4) Adhesions preventing reduction. The drawings were made by Gene McGehee, a third-year student.

and the posterior part of the ileum was severed about four inches anterior to the ileo-cecal valve. The small intestine was also severed anterior to the beginning of the intussusception and an end to end anastomosis was accomplished. A total of approximately 30 inches of intestine were removed. The peritoneum and rectus sheath were sutured separately with No. 0 chromic catgut. A non-absorbable interrupted suture was used to close the skin incision.

Immediately following surgery, 50 cc. of blood was given intravenously, 3 cc. penicillin-streptomycin and 2 cc. of adrenal cortex, intramuscularly. Five hours following surgery 500 cc. of 5 percent dextrose solution, 3 cc. of penicillin-streptomycin and 1 cc. of adrenal cortex were given.

The day following surgery the dog drank a little warm milk and seemed reasonably alert and active. She picked up steadily and on the third day following the operation, she ate one half a can of I/D prescription diet. The dog's stool

remained very thin, but after the seventh day the vaginal discharge was no longer noted. On October 8, one-half of the skin sutures were removed and the antibiotic therapy which had been maintained at 2 cc. every 12 hours was discontinued.

On October 9, the remaining sutures were removed and the dog was sent home. She appeared very active and the incision was healing nicely. One month later the veterinarian who referred the case to the clinic was contacted, and he reported that the bitch had been kept on a soft diet for a week at which time she had a normal stool. Other than this it was an uneventful recovery, the dog being in perfect health at that time.

Robert K. Gubser, '55

2

Dermoid Cyst in a Dog. On September 20, 1953, a year-and-a-half old Dachshund male was admitted to the Stange Memorial Clinic for treatment of a dermoid on the right cornea. The dermoid appeared to be a patch of skin containing a tiny clump of hair and was attached directly to the cornea of the right eye.

The patient was put under light surgical anesthesia with nembutal. The eye was rinsed with 2 percent boric acid solution and 1 percent pontocaine hydrochloride solution was dropped into the eye at a rate of two drops every two minutes for six minutes. The dermoid was carefully dissected off with extreme caution because of the thinness of the cornea and the possibility of rupture of the cornea and hernia of the contents of the anterior chamber. There was only slight hemorrhage and this was controlled by a light pressure pack. Chloromycetin ophthalmic ointment was infused into the eye and the patient was returned to its cage.

Aftercare consisted of twice daily infusions of chloromycetin ophthalmic ointment for three days, then daily infusion until November 8, when the treatment was stopped. At this time vesicles appeared on the margins of both ears. It was