

A Case of Purulent Metritis in a Mare

Karen Wylie*

HISTORY

On September 10, 1967, an aged mare was presented to the Iowa State University Veterinary Clinic with a history of progressively losing condition. In early June the owners had noticed a white mucus-like substance being passed from the lips of the vulva. This secretion was not associated with urination. By the end of June, the discharge had ceased, but the animal continued to become weaker and thinner. The mare was wormed in July and placed on a special high protein diet in an effort to return her to her original condition. Throughout the course of the summer, the mare maintained an excellent appetite.

CLINICAL SIGNS

When presented to the clinic, the mare was extremely cachectic. She was mildly dehydrated, slightly depressed, and had a subnormal temperature. A complete blood count and fecal examination were conducted revealing normal blood cellular constituents and Strongyloidosis. On the third day, a purulent white exudate was noted on the lips of the vulva. The animal appeared to be in the later stages of pregnancy.

* Karen is a senior Veterinary Medicine student at Iowa State University.

A rectal examination was performed. A firm melon shaped mass was located in the pelvic inlet. The surface of the structure was smooth, taut, and unyielding to digital pressure. The mass extended from just inside the anal sphincter anterior to the brim of the pelvis where it dropped from reach into the abdominal cavity. Vaginal examination with a speculum revealed a stenosis at the vulvo-urethral junction. The apparent adhesion seemed to obliterate the entire lumen of the vagina just anterior to the external urethral orifice.

Due to the extent of the metritis and the condition and age of the animal, euthanasia was recommended.*

NECROPSY

Fibrinous adhesions of the intestine were noted. Corpora lutea were present on both ovaries. Both uterine horns were distended to approximately 80 cm. x 30 cm. and contained an estimated 16 liters of cloudy yellow fluid. The anterior one third of each horn was adhered to the ventral abdominal wall.

DISCUSSION

Although this animal was euthanized, one other similar case has been successfully treated at the Iowa State University

Clinic. The prognosis should always be extremely guarded as to the subsequent reproductive ability of the animal. However, treatment may result in sufficient improvement in the condition of the animal that a serviceable saddle horse results. The similar case mentioned had a large pillar of tissue obliterating the vaginal lu-

men in approximately the same location. The body of the uterus and the horns were collapsed, however, and no infection was present. The adhesion was broken down by blunt dissection and a sterile towel thoroughly impregnated with Sulfathiazole ointment was placed in the vaginal lumen to prevent the reformation of ad-

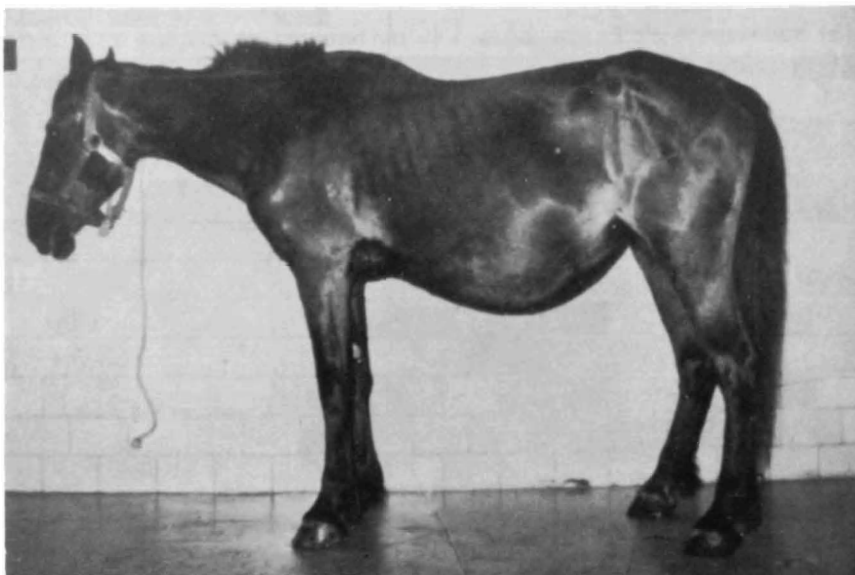


Figure 1. The mare was extremely cachectic, slightly depressed, and appeared to be in the later stages of pregnancy.

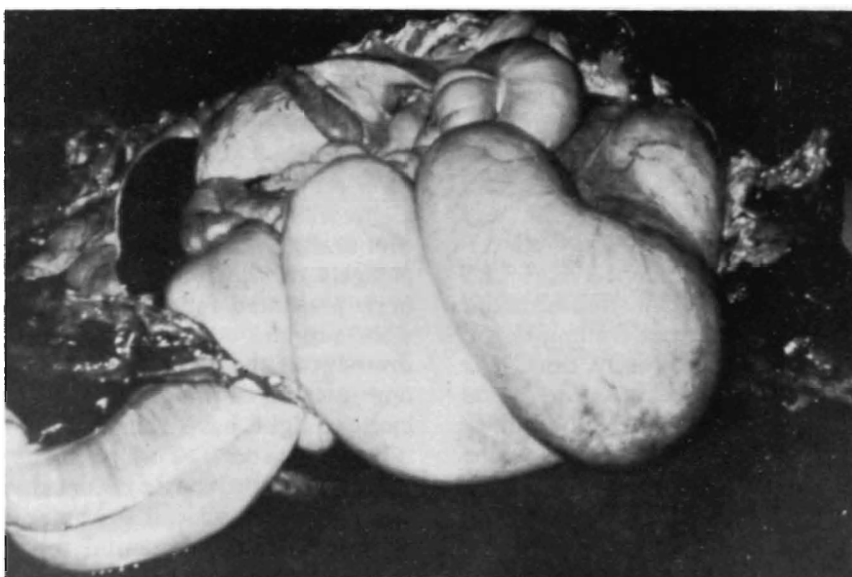


Figure 2. Both uterine horns were distended to approximately 80 cm. \times 30 cm.

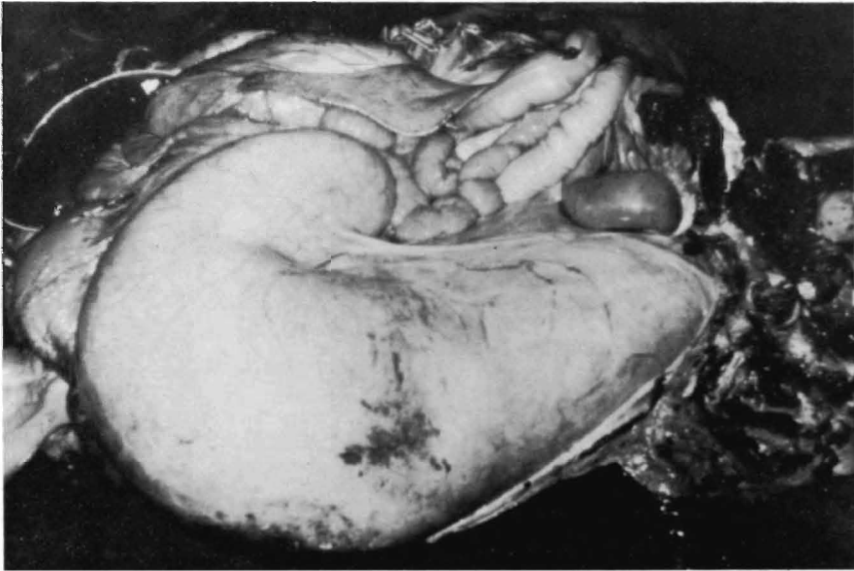


Figure 3. The uterus contained an estimated 16 liters of cloudy yellow fluid. The anterior one-third of each horn was adhered to the ventral abdominal wall.

hesions. The labia were sutured to prevent expulsion of this pack before a 36 to 48 hour period had elapsed. After this length of time, the pack was removed and the vagina examined regularly for any new adhesions. The mare recovered uneventfully, was bred, conceived, and foaled normally. Artificial insemination was used to prevent further trauma to the vaginal mucosa. At the present time, this mare is in foal for the second time since the surgical correction of the adhesion.

Further communication with the owner of the aged subject of this case failed to reveal much more history as to the possible causative trauma. The mare had not foaled in the nine years she had been with the present owners. They had attempted

to have her bred several times including during the summer of 1966. We can only assume that possibly something at this time set up an irritation or caused some slight trauma to the vaginal mucosa which eventually resulted in the adhesion and stenosis of the lumen. If the mare had been presented for treatment earlier, possible surgical correction of the adhesion, drainage of the genital tract, and intermittent flushing of the genital tract with antibiotics might have returned the mare to riding condition. The possibility of her being bred and having conceived would have depended upon the extent of permanent damage to the genital tract and the original reason she had failed to conceive in previous years.