

A Purse-string Suture Technique for Retention of Coxofemoral Luxations

Ronald L. Thompson

INTRODUCTION

Coxofemoral luxations in the dog and cat are a common problem resulting most often from encounters with automobiles. Nearly 50 per cent of all luxations in these two species involve the coxofemoral (hip) joint.^{1,9}

The coxofemoral luxation is classified according to the relative relationship of the head of the femur to the acetabulum. The classifications are anterior, dorsal, posterior and intrapelvic.⁹ The intrapelvic luxation always involves an associated fracture of the acetabular structures. (Fig. 1). In the case of the first three classifications, the descriptive term extrapelvic is purposely omitted and the position of the head is assumed to be lateral or outside the acetabulum. (Fig. 2). Reducible luxations caused by trauma and involving no fracture of the associated hip structures are by far the most common and their retention after reduction the primary concern of this paper.

Diagnosis and reduction of the luxation are often the easiest portion of handling the problem of coxofemoral luxations. Leonard describes these aspects well.⁹ Many degrees and variations of injury to the structures associated with the hip joint occur as a result of chance positioning of the femur at the time of impact, and upon the effect of the force applied on the hip joint. A great variety of methods parallel the variations in an attempt to retain the

luxation once the reduction is accomplished. The fact that there are so many ways to attempt retention indicate that no one method has been outstanding.^{2,8}

On occasion, simple reduction by manipulation followed by cage rest will suffice.⁹ Another commonly applied method is the figure 8 or flexion bandage. When used bilaterally, it is called the "spread cast," "butterfly splint," or "airplane cast."^{1,2,9} Others have advocated first bruising the associated soft tissues with a blunt instrument and applying the aforementioned bandages.²

Less conservative techniques have included: use of Kirshcner wires in an attempt to extend the brim of the acetabulum,^{1,5,9} placement of crossed Steinman pins with a similar goal in mind,^{1,9,12} attachment of shaped plastic to the dorsal rim of the pelvis to improve the "acetabulum" dorsally,^{1,7} placement of an intramedullary (DeVita) pin over the neck of the femur in an attempt to immobilize dorsal movement of the femur,^{1,4,9} application of a "toggle pin" apparatus which would act as the round ligament of the femur (ligamentum capitis femoris)^{1,8,9,11} and excision arthroplasty of the femoral head.³ It has been a common practice to begin with the more conservative treatment and evaluate the response prior to resorting to the more involved methods.

In September of 1963, Dr. L. L. Hansmeyer reported a technique in the Journal of the South African Veterinary Medical Assoc. which could be applied to traumatic coxofemoral luxations which are easily reducible and reoccur when pressure is applied along the axis of the femur.⁶ It in-

* Mr. Thompson is a Senior in the College of Veterinary Medicine, Iowa State University.

The author wishes to express his appreciation to Dr. Daniel J. Hillmann for his assistance in preparation of the photographs for this article.

involved placing a purse-string suture in a pattern around the trochanter major of the femur. This technique was further expounded upon by Dr. D. S. MacDonald in the September 1964 issue of the Canadian Journal of Comparative Medicine.¹⁰

The technique to be described here is a modification of the above reports. It has been employed at the Stange Memorial Clinic at Iowa State University over the past year. It should be emphasized that this method is intended for traumatic luxations which are easily reducible and which recur when pressure is applied. It should not be employed when fractures of the femur or acetabular structures are associated with the coxofemoral luxation.

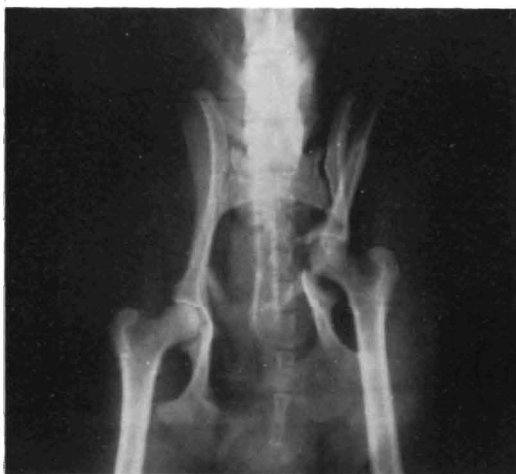

Figure 1. An "intrapelvic" luxation of the coxofemoral joint; an associated acetabular fracture exists.

Operative Technique:

The preanesthetic agents atropine sulfate (1/50 gr. per 20 pounds (4.5Kg) body weight) and morphine sulfate (1/2 gr. per 20 pounds (4.5Kg) body weight) are administered together subcutaneously. In 30 minutes the dog is taken to the preparation room where it is placed under general anesthesia. Induction is accomplished by intravenous injection of the ultrashort acting barbiturate Surital* given to effect. The trachea is intubated and the inhalation anesthetic Metophane** is administered

* Surital®—Parke, Davis and Company. A brand of sodium thiamylal. A 4% solution.

** Metophane®—Pitman-Moore. A brand of methoxyflurane.

throughout the remainder of the procedure. The surgical site is now prepared in the usual manner. The animal is taken into the surgery room and positioned on the table in lateral recumbency. Manipulation of the limb is facilitated if sterile Orthopedic stockinette*** is applied over the leg and secured dorsally. A slit is placed in the stockinette over the proposed incision site. The luxation is reduced by digital manipulation.^{1,2,6,9,10}

A skin incision is made starting one to two inches proximally to the greater trochanter and continued distally directly over the long axis of the femur to a point two to three inches below the greater trochanter. The skin is separated from sub-

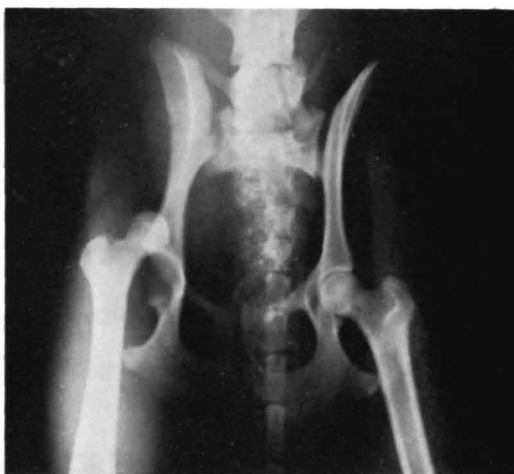

Figure 2. A "dorsolateral" coxofemoral luxation.

cutaneous tissue for approximately two inches on either side of the incision line.

Using heat sterilized Vetafil**** (heavy) which has never been in chemical disinfectant and a large curved cutting edge needle, the needle is inserted into the belly of the tensor fascia lata muscle at a point one-half inch anterior to the femur and approximately one inch distal to the greater trochanter. A long bite about one-quarter inch deep is taken and the needle is directed proximally and parallel to the

*** Curity®—Kendall Co., Bauer and Blade Division. Orthopedic stockinette.

**** Vetafil Bengen®—Dr. S. Jackson (importer) Washington, D.C. A synthetic polyfilament suture material. Heavy is U.S.P. size-0, medium U.S.P. size-00.

long axis of the femur to emerge one inch dorsal to the greater trochanter through the belly of the superficial gluteal muscle. The needle is reinserted into the muscle about one-eighth inch from the previous point of exit and directed caudally to emerge about one-half inch caudal to and one inch proximal to the greater trochanter. This bite should also be about one-quarter inch deep and pass through the superficial and deep gluteal muscles before emerging through the biceps femoris. (Fig. 3). The third bite should be shallower to insure not injuring the underlying sciatic nerve. It is started one-eighth inch from the previous emergence and directed distally one-half inch from the femur and

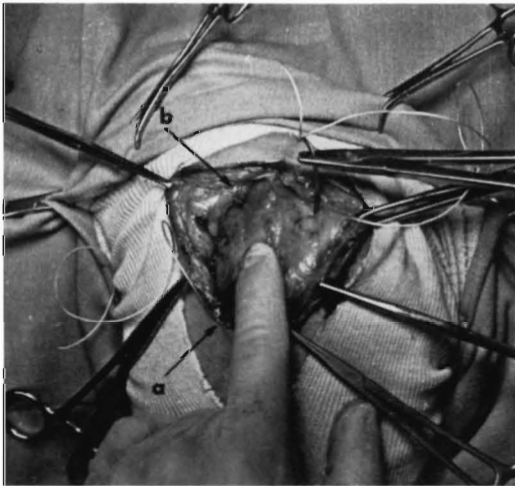


Figure 3. Placement of the "purse-string" suture. a) The point of original insertion, b) the point of emergence of the first bite and entrance of the second. The needle is in position for the third bite and the index finger is palpating the greater trochanter.

parallel to its long axis. It should emerge at a point in line with the original insertion. The fourth and final link is made with a deep bite starting one-eighth inch from the last point of emergence and directed anteriorly to finally emerge about one-eighth inch from the original insertion (Fig. 4).

The loose ends are tied tightly together. A hard enclosed muscle mass superficial to the greater trochanter is the result. The required tightness may be judged by application of pressure in an attempt to again luxate the limb. A subcutaneous

closure is accomplished by a continuous pattern of 2-0 chromic catgut. The skin is closed with medium weight Vetafil or silk in a split thickness interrupted horizontal mattress pattern.

CONCLUSIONS

This simple but effective method of retention applied to reduced coxofemoral luxations has been employed at Iowa State University's Stange Memorial Clinic over the past year. Gratifying results have been attained. It should be emphasized that this procedure is indicated only in cases of traumatic coxofemoral luxations which recur upon manipulation. It should not be employed when acetabular fractures or

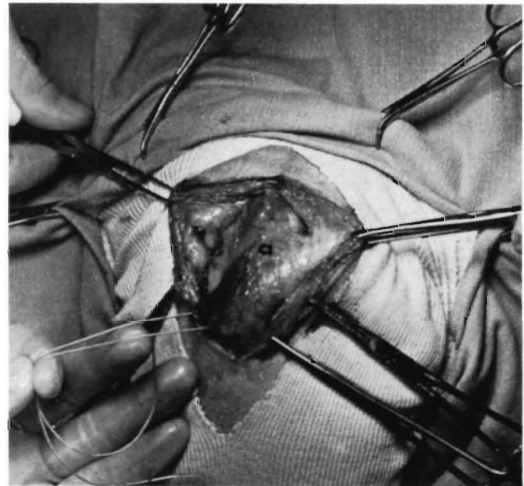


Figure 4. Appearance of the "purse-string" suture prior to tying. a) The area of the greater trochanter.

fractures of the femoral head or neck are associated with the dislocation.

In certain recurrent luxation problems the acetabulum may become filled with organized hemorrhage or fragments of the joint capsule and ligaments. The torn capsule may also heal over the acetabulum and act as a diaphragm. In the above case, proper reduction may become impossible. The anterior-lateral approach to the hip joint may be employed to "clean out" this material and allow adequate reduction.^{1,2,9,11} This procedure may then be followed by the purse-string technique to assure fixation.

(Continued on page 16)

EARLY INVESTIGATORS

Investigator (1818-1901)	Major Place Munich, Germany	Pertinent Work Respiration apparatus for digestion trials and "res- piratory quotient."	Reference 12
Voit (& Bischoff) (1831-1908)	Munich, Germany	Respiratory apparatus. Fat from fat-free meat. Nitro- gen balance studies.	21, 22
Lawes (& Gilbert) (1814-1900)	Rothamsted, England	Composition of fattening animals. Fat from car- bohydrates.	9
Henneberg (& Stohman) (1825-1890)	Weende	The more food the more con- verted to flesh.	6
Zunty (& Hagemann) (1847-1920)	Berlin	31.5% efficiency from food to work.	26
Rubner	Munich	Caloric values of food stuffs. Replacement of nutrients for heat pro- duction.	18
Wolff (1818-1896)	Hohenheim	Variable digestibility of fodder.	24

<ol style="list-style-type: none"> 3. Cheyne, George, <i>Essay on Regimen Together with Five Discourses Medical, Moral and Philosophical</i>, London, 1739. 4. Fulton, John F. and Leonard Wilson, <i>Selected Readings in the History of Physiology</i>, 2nd ed., Springfield. Charles C. Thomas, 1966. 5. Haller, Abrecht von, <i>Praelectionis Boerhaavi ad proprias Institutiones</i>, Gottinga, 1739-1744. 6. Henneberg, W. and Stohman, <i>Beitrage zur Begründung einer Rationellen Fütterung der Wiederkäuer</i>, Brunswick, 1860-1864. 7. Hunter, John, On the Digestion of the Stomach after Death, in <i>Philosophical Transactions</i>, 1772. 8. Jones, W. H. C., <i>Hippocratic Collection</i>, Transl. 1923. 9. Lawes, John and J. Gilbert, <i>Phil. Trans. II</i>, 1859, 493. 10. Macbride, David, <i>Experimental Essays on the Fermentation of Alimentary Mixture</i>, London, 1764. 11. Montegre, Antonio, <i>Experiences de la Digestion dans l'Homme</i>. Paris, 1814. 12. Pettenkofer, Max von and Carl von Voit, <i>Ueber einem neuen Respirationssysteme</i>, Munich, 1861. 13. Pringle, John, <i>Experiments on Substances Resisting Putrefaction</i>, London, 1750. 14. Prout, William, On the nature of the acid and saline matters usually existing in the stomachs of animals, <i>Phil. Trans.</i> 114, 1824. 15. Prout, William, <i>Chemistry, Meteorology, and the</i> 	<ol style="list-style-type: none"> 16. Reaumer, Rene Antoine, <i>Sur la Digestion</i>, Mem. Acad. Roy. Sci., Paris, 1752. 17. Redi, Francesco, <i>Osservazioni Intorno agli Animali Viventi</i>. Firenze, Italy, 1684. 18. Rubner, Max, <i>Ges. d. Energie Verbr. b. d. Ernährung</i>, Munich, 1902. 19. Spallanzani, Lazaro, <i>Dissertations Relative to the Natural History of Animals</i>, Transl. J. Murray, London, 1784. 20. Stevens, Edward, <i>Experiment Concerning Digestion</i>, (an inaugural thesis dissertation), Edinburgh, 1777. 21. Voit, Carl von and Bischoff, <i>Die Gesetze der Ernährung des Fleischfressers</i>, Leipzig, 1860. 22. Voit, Carl von, <i>Ueber die Theorien der Ernährung den Tierischen Organismen</i>, Munich, 1868. 23. Wilson-Phillip, A. P., in various articles found in <i>Transactions of the Royal Society</i>, c. 1830. 24. Wolff, Emil von, <i>Anleitung zur Chemischen Untersuchung Landwirtschaftlich Wichtiger Stoffe</i>, 4th ed. Stuttgart, 1899. 25. Young, J. R., <i>An Experimental Inquiry into the Principles of Nutrition, and the Digestive Process</i>, Philadelphia, Eaken & Mecum, 1803. Reprinted by University of Illinois Press, Urbana, 1959. 26. Zuntz, Nathan and O. Hagemann, <i>Untersuchungen über den Stoffwechsel des Pferdes bei Ruhe und Arbeit</i>, Berlin, 1898.
---	--

A Purse-string Suture Technique for Retention Coxofemoral Luxations

(Continued from page 6)

REFERENCES

1. American Veterinary Publications, Inc., *Canine Surgery*, First Archibald Edition, p. 898-913, 1965.
2. Campbell, J. R., Lawson, D. D. and Wyburn, R.S., Coxofemoral Luxations in the Dog, *Veterinary Record* 77: p. 1173-1177, October, 1965.
3. DeAngelis, M., and Hohn, R. B., Ventral Approach to Excision Arthroplasty of the Femoral Head, *Journal of the American Veterinary Medical Asso.* 152: p. 135-138, Jan. 15, 1968.
4. DeVita, J. A., A Method of Pinning for Chronic Dislocation of the Hip Joint, *Proceedings of the American Veterinary Medical Asso.*, p. 191-192, 1952.
5. Durr, J. L., The Use of Kirschner Wires in Maintaining Reduction of Dislocation of the Hip Joint, *Journal of American Veterinary Medical Asso.*, 130: p. 78-81, 1957.
6. Hansmeyer, L. L., Fixation After Reduction of Luxation of the Coxofemoral Joint in Dogs, *The*

- Journal of South African Veterinary Medical Asso.* 34: p. 459-460, September, 1963.
7. Helper, L. C., Schiller, A. G., Repair of Coxofemoral Luxation by Extension of the Acetabular Rim, *Journal of the American Veterinary Medical Asso.* 143: p. 709-711, 1963.
8. Knowles, A. T., Knowles, J. O., Knowles, R. P., An operation to reserve the Continuity of the Hip Joint, *Journal of the American Veterinary Medical Asso.* 123: p. 508-515, 1953.
9. Leonard, E. P., *Orthopedic Surgery of the Dog and Cat*, Philadelphia and London, Saunders Co., p. 187-207, 1960.
10. MacDonald, D. S., Retention of Coxofemoral Luxations using a purse-string suture, *Canadian Journal of Comparative Medicine*, 28: p. 221-222, September, 1964.
11. Piermattel, D. L., Technique for Surgical Management of Coxofemoral Luxations, *Small Animal Clinician*, 3: p. 373-386, 1963.
12. Vincent, Z. D., The Use of Steinman Stainless Steel Pin in Recurrent Coxofemoral Luxation in the Dog and Cat, *South African Veterinary Medical Journal*, 32: p. 423-425, 1961.