

ULTRASONIC PERIODONTAL PROBE

Mark K. Hinders and John C. Companion
Department of Applied Science
The College of William & Mary
Williamsburg, VA 23187-8795

INTRODUCTION

We have developed an ultrasonic technique for imaging periodontal structures which allows accurate measurements of disease activity without the need for ionizing radiography or manual periodontal probing. It promises reduced variability and improved ease of use, in comparison to conventional manual periodontal probing, and is the first step to establish the ultrasound periodontal probe as a clinically-valuable tool for patient assessment and the first non-invasive measure of periodontal disease activity. We have gathered data from cadaver samples using a prototype intra-oral ultrasound instrument, and have compared the ultrasound scans against conventional manual probing subsequently performed on the annotated cadaver samples.

Periodontal disease is one of the most pervasive dental diseases in older adults [1] - [3] showing increasing prevalence with age [4]. It involves the loss of connective tissue attachment with subsequent destruction of alveolar (tooth-supporting) bone, leading to loss of teeth. Bone loss due to chronic periodontal disease usually is preceded by loss of connective tissue attachment, indicated by an apical progression of the crest of the periodontal ligament [5]. At present, there are no reliable clinical indicators of periodontal disease activity and the best available diagnostic aid, conventional periodontal probing, is only a retrospective analysis of attachment already lost [6] - [16]. Subtraction radiography may be of value in detecting small changes in alveolar bone mineralization but does not evaluate periodontal ligament attachment [17] - [20]. In addition, changes in bone have been shown to lag behind connective tissue loss by several months [21]. Serial radiography also subjects the patient to increasing amounts of ionizing radiation. A method for detecting small increments of periodontal ligament breakdown would permit earlier diagnosis and intervention with less costly and time consuming therapies. Moreover, there is evidence that "disease active" sites respond positively to therapy but that quiescent or stable sites do not change or lose attachment [22] so a more sensitive diagnostic probe would permit site-specific identification of attachment loss. This could direct treatment toward areas that are actively breaking down, and eliminate over treatment for sites that are stable. It will provide the clinician with a non-invasive method for measuring periodontal status without the often-reported discomfort of conventional periodontal probing.

The main use of ultrasound in dentistry is for scaling of teeth and internal shaping of teeth [23] which is in contrast to other areas of medicine where diagnostic ultrasonography is a standard clinical imaging technology. Ultrasound imaging has been recognized by leading authorities as having the best potential for non-invasive periodontal disease evaluation [24] and initial attempts at using ultrasound for intra-oral diagnosis have shown promise despite difficult technology problems [25] - [28]. Our exploratory development program has now produced an intra-oral probe small enough to be practical [29] with an ultrasound beam projection area close enough in size to the width of the periodontal space to give the optimal coupling and small enough to inspect the area between the teeth, while still delivering sufficient signal strength and depth of penetration to image the periodontal space. In the work reported here, cadaveric specimens (human) of disarticulated dental/jaw sections were obtained through the Naval Dental School's relationship with the Uniformed Services University of the Health Sciences Anatomy Department, and were provided by NDS to William & Mary. These samples were ultrasonically scanned with the location of each scanned point indelibly marked on each resident tooth for comparison to conventional mechanical periodontal probing.

EXPERIMENTAL RESULTS

We have developed a non-invasive ultrasound technique to detect, image, and map the upper boundary of the periodontal ligament and its variation over time as an indicator of the presence of periodontal disease. One of the key technical obstacles we overcame was developing an ultrasonic probe that would be small enough to be useful, but yet transmit and receive sufficient signal strength. The space occupied by the periodontal ligament is normally on the order of 0.5 mm wide, located between the outer surface of the tooth root and the inner surface of the bone forming the socket in which the tooth resides. The coronal elevation of the periodontal ligament is normally approximately 1 mm below the surface of the junctional epithelium which abuts the tooth surface and forms the sulcus below the gingival margin. In order to probe these structures ultrasonically, a narrow beam of ultrasonic energy is projected down between the tooth and bone from a transducer which is manually scanned along the gingival margin, as shown in Figure 1.

The operating frequency of the device we have used for the results shown here is 20 MHz, and the transducer diameter is 12 mm. The transducer is mounted at the base of a dual taper, convergent-divergent coupler, in order to provide an acoustically tapered interface with a throat area on the order of 0.5mm. This constitutes an active area reduction from the transducer element to the aperture of 20-1. Such a reduction is mandated by the geometry and the very small window afforded by the gingival margin. An added virtue of attaining this small a tip size is the ability of the ultrasonic probe to examine the area between the teeth, which is where the problem of periodontal disease is most likely to occur. Figure 2 shows how the ultrasound transducer is mounted in the probe tip shell, which is also incorporates a slight flow of water to ensure good coupling of the ultrasonic energy to the tissues. The probe tip can be mounted in a hand piece that is light in weight and a convenient size for clinical use. The couplant water can come either from a suspended IV-type sterile bag or plumbed from the dental chair. All of the specialized electronics are commercially available as plug in computer boards and are operated via software that runs on the type of pentium class PC's that are becoming common in the dental office.

The focused ultrasonic beam is transmitted into the pocket in the same orientation as a manual probe is inserted and the probe is then moved along the gingival margin, so the two dimensional graphical output corresponds to that one gets from “walking the sulcus” with a manual probe. Ultrasound gives more information, however, because secondary echoes are recorded from tissue features at various depths. It appears likely that the technique will also be able to provide information on the condition of the gingival tissue and the quality and extent of the epithelial bond to the tooth surface. This may provide valuable data to aid the clinician in the diagnosis and treatment charting of the disease.

Figure 3 shows a B-scan of four teeth in a cadaver mandible along with mechanical probing depths in mm. Because the velocity of ultrasonic waves is known, the time delay in echoes corresponds to depth into the tissues which is marked in mm on the right of the figure. The transducer was scanned along the gingival margin, the level of which is shown along with the standard locations for mechanical probing. Note that a cementum pearl on the root surface of tooth 31 shows up clearly in the ultrasonic scan, and the furcation involvement on tooth 30 gives strong ultrasonic echoes. The bottom of the pocket on tooth 31 is out of range on the figure.

DISCUSSION OF RESULTS

At present, there are no reliable clinical indicators of periodontal disease activity and the best available diagnostic aid, conventional periodontal probing with a manual probe, is a retrospective analysis of losses in periodontal attachment. The development of a new non-invasive diagnostic *Gold Standard* for periodontal disease activity would directly improve patient management through earlier and more accurate targeting of treatment. We have developed such a technique for ultrasound imaging of human periodontal structures, and have presented in this paper some results with a comparison to conventional manual probing depths.

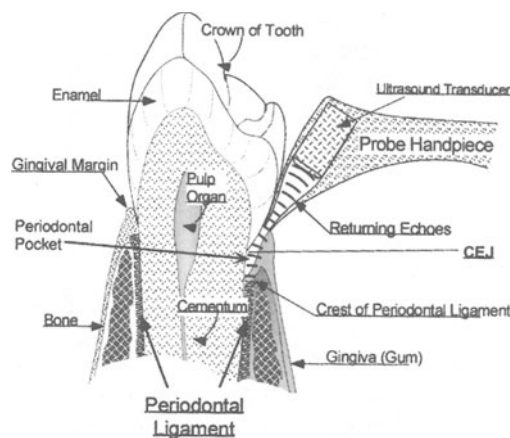


Figure 1. Ultrasonic periodontal probe with probe tip at the gingival margin and ultrasound projected into the periodontal pocket. The echoes returning from the crest of the periodontal ligament are shown.

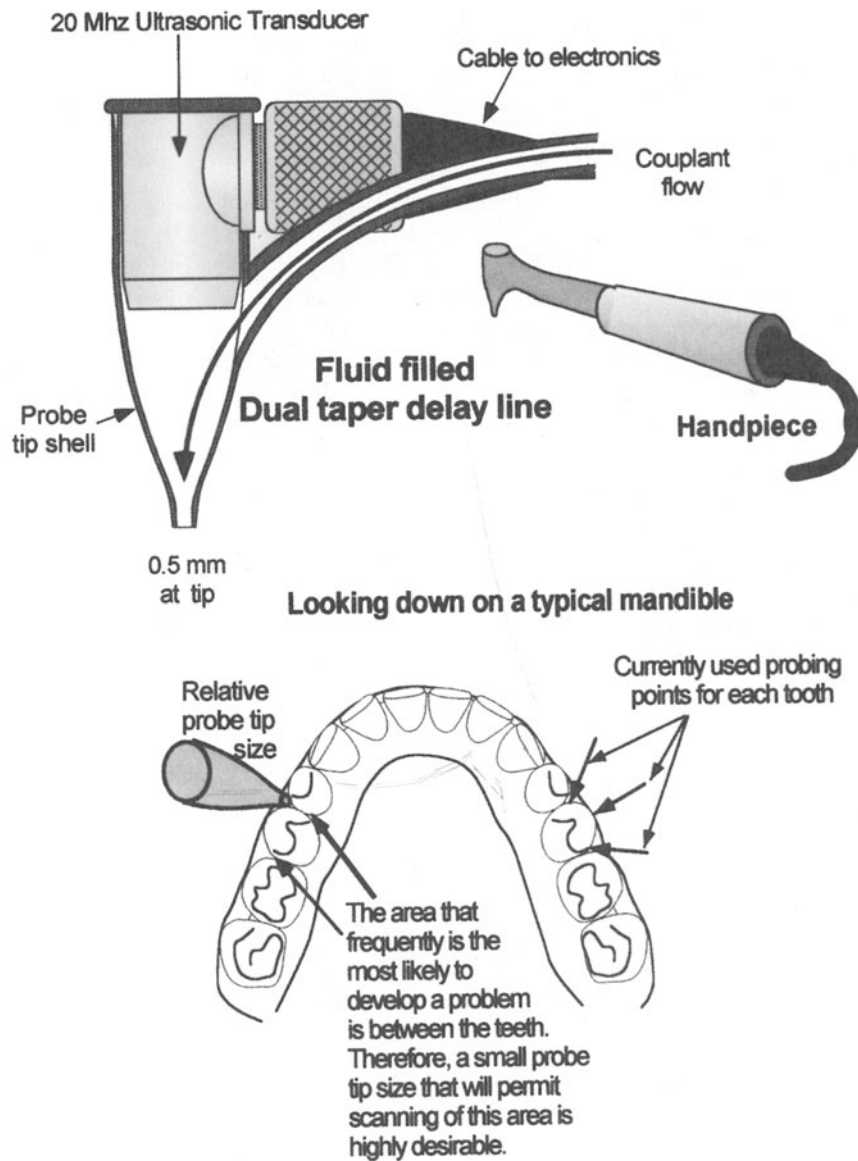


Figure 2. The hand piece contains a probe tip which is small enough to permit scanning of the area between teeth. The ultrasonic transducer is mounted in a probe tip shell (a fluid-filled dual taper delay line) which has a throat diameter small enough to project the ultrasonic beam into the narrow space between the tooth and bone.

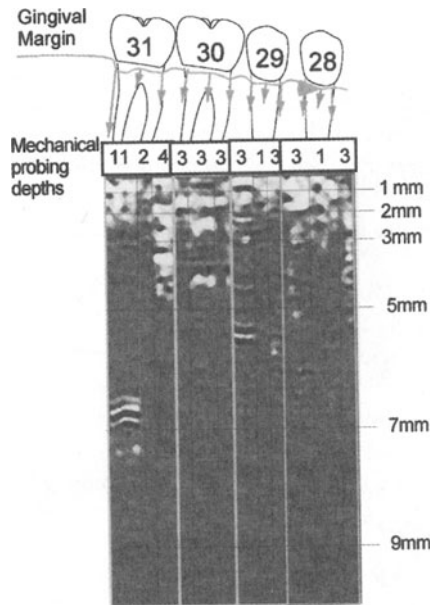


Figure 3. Comparison between ultrasonic scan and mechanical probing depths, in vitro, both done at the same three locations on each tooth. The transducer was moved laterally along the gingival margin, with the depths of the echoes relative to the gingival margin indicated. On tooth 31 the 11 mm probing depth is off scale at the bottom of the figure. The echos that are apparent at about 7mm for this tooth correspond to a cementum pearl on the root surface. Tooth 30 had a furcation involvement which may be responsible for the strong echoes at 3 and 4 mm.

As our research progresses, additional ultrasonic data of this type will be used to improve the interpretation of the ultrasonic images, and to support mathematical modeling and computer simulation of the ultrasonic wave propagation in the periodontal pocket. A key part of the next phase of work is a comparison between ultrasonic scanning and histopathological sections for the same in vitro samples. Once confidence in our interpretations is established, the emphasis will move to the determination of the accuracy in mapping periodontal structures that can be achieved by this ultrasonic technique, and to the development of signal processing algorithms to present the ultrasonic data in a format most useful to clinicians. One question that remains to be answered is whether characteristic ultrasonic echoes will be returned from the cemento-enamel junction or whether the CEJ location will need to be determined by complimentary techniques

ACKNOWLEDGEMENTS

The authors thank Cpt. A. Charles Richardson, DDS of the Naval Dental School for providing the samples used in this work, and for many helpful discussions. The support and assistance of Drs. Eric Madaras and Joe Heyman of NASA Langley Research Center are also gratefully acknowledged. This work was supported by NDS and NASA Langley.

REFERENCES

1. Douglas, C W, Gillings, D., Sollecito, W., and Bammon, M. (1983) National trends in the prevalence and severity of the periodontal diseases. *JADA* 107 403-411.
2. Barrington, EP and M Nevins (1990) Diagnosing periodontal diseases, *JADA* 121 460-464.
3. Page, RC (1995) Critical Issues in Periodontal Research, *J. Dent. Res.* 74 1118-1128.
4. Horning, G.M, Hatch, C.L, and Lutskus, J. (1990) The prevalence of periodontitis in a military population. *JADA* 121 616-620.
5. Carranza, FA and MG Newman (1996) *Clinical Periodontology*, 8th Edition, W.B. Saunders Company, Philadelphia.
6. Listgarten M.A. (1980) Periodontal probing: What does it mean? *J Clin Periodontol*, 7 165.
7. Haffajee AD, et al. (1982) Clinical parameters as predictors of destructive periodontal disease activity. *J. Clin Periodontol*, 10 257.
8. Quirynen, M, A Callens, D van Steenberghe and M Nys (1993) Clinical Evaluation of a Constant Force Electronic Probe, *J. Periodontol.* 64 35-39.
9. Tessier, JF, GV Kulkarni, RP Ellen and CAG McCulloch (1994) Probing Velocity: Novel Approach for Assessment of Inflamed Periodontal Attachment, *J. Periodontol.* 65 103-108.
10. Tupta-Veselicky, L, P Famili, FJ Ceravolo and T Zullo (1994) A Clinical Study of an Electronic Constant Force Periodontal Probe, *J. Periodontol.* 65 616-622.
11. Hunter, F (1994) Periodontal probes and probing, *Int. Dental J.* 44 557-583.
12. Hull, PS, V Clerehugh and A Ghassemi-Aval (1995) An Assessment of the Validity of a Constant Force Electronic Probe in Measuring Probing Depths, *J. Periodontol.* 66 848-851.
13. Rams, TE and J. Slots (1993) Comparison of Two Pressure-Sensitive Periodontal Probes and a Manual Probe in Shallow and Deep Pockets, *Int. J. of Periodontics & Restorative Dentistry* 13 521-529.
14. Lang, NP and EF Corbet (1995) Diagnostic Procedures in Daily Practice, *Int. Dental J.* 45 5-15.
15. Greenstein, G and I Lamster (1995) Understanding Diagnostic Testing for Periodontal Diseases, *J. Periodontol.* 66 659-666.
16. Mayfield, L, G Bratthall and R Attstrom (1996) Periodontal probe precision using 4 different periodontal probes, *J. Clin. Periodontol.* 23 76-82.
17. Van det Stelt, PF (1993) Modern Radiographic Methods in the Diagnosis of Periodontal Disease, *Adv. Dent. Res.* 7 158-162.
18. Jeffcoat, MK (1992) Radiographic Methods for the Detection of Progressive Alveolar Bone Loss, *J. Periodontol.* 63 367-372.
19. Hausmann, E, K Allen, J Norderyd, W Ren, O Shibly and E Machtei (1994) Studies on the relationship between changes in radiographic bone height and probing attachment, *J. Clin. Periodontol.* 21 128-132.
20. McDonnell, D (1995) Digital Dental Imaging Systems: A Review, *J. Can. Dent. Assoc.* 61 962-964.
21. Goodson MJ, et al. (1982) Patterns of progression and regression of advanced destructive periodontal diseases. *J Clin Periodontol*, 9 472.
22. Lindhe J, et al. (1986) Design of clinical trials of traditional therapies for periodontitis. *J Clin Periodontol*, 13 488.

23. Walmsley, AD, WRE Laird and PJ Lumley (1991) Ultrasound in dentistry. Part 2 periodontology and endodontics, J. Dent. 19, 11-17.
24. Lang, N.K. and Bragger, U., (1991) Periodontal diagnosis in the 1990s. J Clin Periodontol, 18 370-379.
25. Yoshida, H. , Akizuki H., and Michi, K.(1987) Intraoral ultrasonic scanning as a diagnostic aid. Journal of Cranio Maxillo Facial Surgery 15 306-311.
26. Palou, ME, MJ McQuade and JA Rossmann (1987) The use of ultrasound for the determination of periodontal bone morphologyJ. Periodontol. 58 262-265.
27. Lost, C, KM Irion and W Nussle (1988) Periodontal ultrasonic diagnosis: experiments on thin bony platelets and on a simulated periodontal ligament space, J. Periodont. Res. 23 347-351.
28. Oikarienen, KS, TM Nieminen, H. Makarainen and J. Pyhtinen (1993) Visibility of foreign bodies in soft tissue in plain radiographs, computed tomography, magnetic resonance imaging, and ultrasound, Int. J. Oral Maxillofac. Surg. 22 119-124.
29. Companion, JA (1998) Differential Measurement Periodontal Structures Mapping System, US Patent #5,755,571.