

Intestinal Swine Anthrax

* *Don Rubel*

DUE TO THE RECENT increases in the incidence of anthrax in swine, numerous publications have attempted to acquaint the practitioner with the various lesions that may be seen. The majority of these descriptions have emphasized the pharyngeal and tonsillar lesions. Many practitioners may have assumed that the oral and pharyngeal regions are the only areas where the Anthrax bacillus localizes in swine.

In a recent review of the literature by Dr. Paul C. Bennett, head of the Iowa State Diagnostic Laboratory, it was brought to my attention that there is also another form of anthrax in swine. This is known as the intestinal form. The intestinal lesions were described by Dr. Karel Macek, of the Veterinary High School, Brno, Czechoslovakia. They were also discussed in a paper read by Dr. L. Van Es², of the Department of Pathology at the University of Nebraska, Lincoln, Neb., at the 40th annual meeting of the United States Live Stock Sanitary Association in 1936.

Both writers agree that the intestinal form occurs most frequently in the duodenum, less often in the other parts of the intestinal tract. The changes are of varying extent and intensity. Such changes may be slight and localized, whereas, in others, several feet of the gut may be involved. An intense enteritis may be ob-

served, presenting a serohemorrhagic or hemorrhagic-necrotic character.

The report of Dr. Van Es states, "The affected mucosa is dark red and swollen, the changes frequently being confined to a certain section of the bowel only. The inflamed mucous membrane is somewhat raised above the level of the normal lining and frequently it is sharply delimited from the latter."

"Necrotic lesions are frequently encountered. They may be small and circumscribed or cover extended areas. Ulcers with ragged edges and a hemorrhagic or grayish base may thus be formed, especially near the mesenteric attachment. In some cases only one small ulcer may be found. The area involved is at first marked by a light red color which deepens into dark red or brownish tint and finally assumes a slate-like coloration."

"In the more or less prolonged cases, hemorrhagic-diphtheritic lesions may be seen and occasionally a hemorrhagic fluid fills the intestinal lumen. Owing to a progressive inflammatory process, the intestinal wall is prone to become thickened, rigid, and with a rounded lumen, may come to resemble a piece of garden hose."

Dr. Macek states that, "If the anthrax process is not limited to individual areas but has become more widespread, then the affected section of the intestinal wall is thickened and presents externally bluish to brownish discolorations. A well marked subserous gelatinous edema is occasionally developed. Frequently fibrinous deposits on the serous surface cause

* Mr. Rubel received his B. A. degree at the University of South Dakota in 1949. He is a member of the Class of '53.

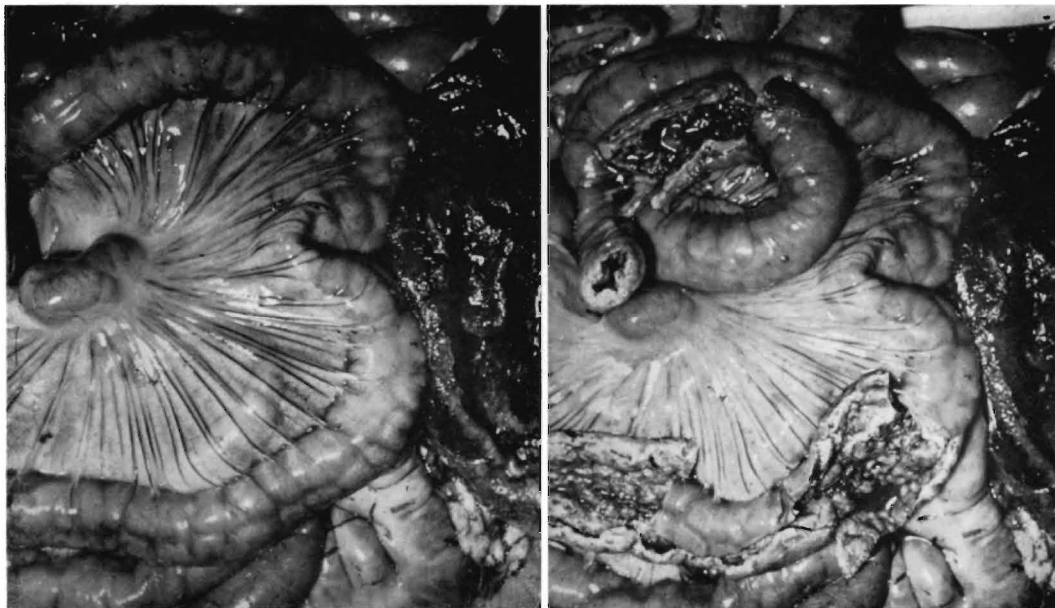


Fig. 1 and 2. Garden hose intestine before and after opening. Note the greatly swollen lymph node and the congested mesenteric vessels. At right of each picture is the opened stomach, which showed a severe hemorrhagic inflammation.

adhesions between individual links of the intestinal chain. Internally, on the mucous membrane, there occur changes of various ages, and, accordingly of various colors (dark red, brownish-red, and bluish gray). The intestinal content is bloody, and, when washed, the mucous membrane may be gray spotted or striped, velvety or dry and rough. Spotting or striping is due to the fact that the necrotic changes begin in the intestinal rugae. Should the necrotic process penetrate deeply into the intestinal walls, perforative peritonitis may result. In isolated cases, hemorrhagic and necrotic foci may also be found in the large intestine."

In the report given by Dr. Van Es, it is stated that, "The lymph nodes regional to the affected parts nearly always, although not constantly, become involved in the infection. The latter gives rise to a hemorrhagic fibrinous necrotic lymphadenitis. The affected lymph node is often markedly enlarged and especially the nodes which receive the lymph drainage of the pharynx and adjacent structures may appear as from two to five times normal size. They are commonly distinguished by a dark, brownish red color and upon sec-

tion they reveal a hemorrhagic and edematous interior."

"In the more acute cases, the entire lymph node may be involved, whereas in the more chronically developing cases, only certain parts may present evidence of a pathologic nature. Particularly in the more chronic intestinal anthrax of swine the lesions may be confined to a single node only and even then the involvement may be a partial one. Such lesions are not always to be readily found."

"Necrotic changes in the involved node may be an early manifestation. The dark red color of the organ then becomes lighter, brick-red or pinkish and finally assumes a grayish yellow tint. The necrotic process may pertain only to a limited portion of the lymph node, the diseased part being separated from the normal tissue by a yellowish line of demarcation. The consistency of the node gradually changes. Its tissue becomes drier and under the influence of pyogenic or other microbic invaders may finally soften. Part or all of the lymph node may thus become affected and the node gradually becomes surrounded by a dense, connective tissue capsule."

After reviewing the literature on the symptoms and lesions of the intestinal form of anthrax, a case involving two pigs was taken from the files of the Iowa State Diagnostic Laboratory to illustrate at least the possibilities of an oversight in diagnosing this form of the disease. There is now some question as to the correct final answer. It also illustrates that the presence of a disease must first be suspected before it can be diagnosed.

On July 17, 1951, two pigs, 15 weeks old were brought to the Iowa State diagnostic laboratory for the purpose of autopsying and making a diagnosis. The history indicates that they were from a lot of 210 pigs. The entire lot had been vaccinated for Hog Cholera with serum and virus prior to weaning and had not been vaccinated for swine erysipelas. They were wormed on July 7th using phenothiazine. On July 9th one pig was found dead. On the 16th, three died and on the morning of the 17th, three more had died, thus giving a total of seven dead pigs in a period of nine days.

The symptoms exhibited were that many of the pigs were listless and off feed. Some of the pigs were vomiting and had a diarrhea. A lot of 28 sows kept separately from these pigs were not affected.

The post mortem examination of the first pig revealed a generalized icterus and the presence of numerous ascarids. Some of these ascarids were found in the bile duct, accounting for the obstructive jaundice. A diffuse congestion of the regional lymph nodes was evident. The bladder and the glottis were congested. A severe necrotic and diphtheritic enteritis of the small intestine, primarily in the region of the duodenum, was noted. A severe hemorrhagic gastritis was observed.

The second pig also had several ascarids. A diffuse hyperemia of the regional lymph nodes was present. The kidneys, bladder, and glottis were congested. A severe necrotic and diphtheritic enteritis of the small intestine was again noted. Bacteriological examinations on both specimens were negative except for the

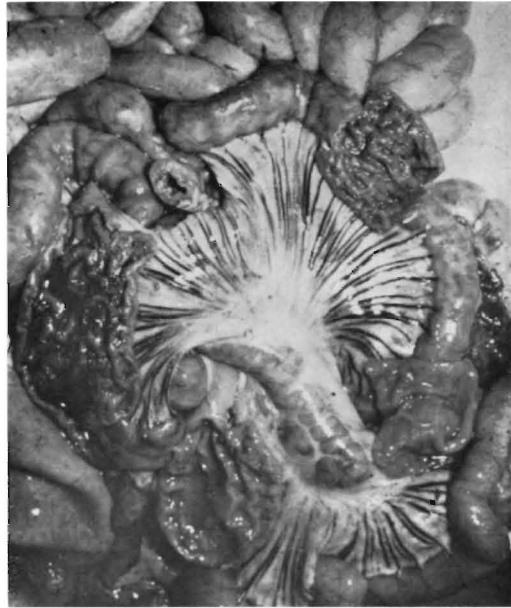


Fig. 3. Second pig examined, showing the thickened intestinal wall with more hemorrhage and fluid contents, but with less caseation. Lymph node swollen and mesenteric vessels congested.

presence of *E. coli* and *Proteus* organisms associated with the enteritis.

It is very interesting to note in the accompanying pictures of the abdominal viscera of these two particular specimens that the lesions are very similar to those described by both Dr. Van Es and Dr. Macek.

1. Macek, Karl. Translated by Dr. Frank Jelen, from Clinical Records 1929. Allied Veterinarian, Feb. 1932.
2. Van Es, L., Anthrax in Swine, Jour. of the A.V.M.A. Vol. XC, pp. 331-340, March 1937.

According to an excerpt from *Veterinary Medicine*, Dec., 1951, 80 percent of a group of swine in Iowa affected with atrophic rhinitis harbored a *Trichomonas* specie in the nasal cavity. By comparison, only 2.8 percent of diseased Iowa swine not affected with this disease had demonstrable organisms. The early stages of atrophic rhinitis usually yielded the greatest number of protozoa, while the more advanced cases usually contained only a few protozoa.